

**CROSS SECTIONAL STUDY:
A FIVE YEAR REVIEW OF
G E S T A T I O N A L
T R O P H O B L A S T I C D I S E A S E
IN KUANTAN GENERAL HOSPITAL
(JAN 1995 – DEC 1999)**

- by -

DR MOHAMAD FAIZ B. MOHAMED JAMLI

**DISSERTATION SUBMITTED IN PARTIAL FULFILMENT
OF THE REQUIREMENT FOR
THE DEGREE OF MASTER OF MEDICINE
(OBSTETRICS & GYNAECOLOGY)**

**UNIVERSITY SAINS MALAYSIA
2001**

*To all women who have suffered from
Gestational Trophoblastic Disease*

2023.1.10

*A*CKNOWLEDGEMENTS

By the name of Allah, I wish to express greatest appreciation and special thanks for the exceptional effort of my supervisor Dr Awang Nila Ismail, Head of department, senior consultant and lecturer Department of Obstetrics and Gynaecology Hospital USM , in preparation of this dissertation. Completion of this dissertation would not have been possible without his guidance and assistant. Thank you also to Dr Mohd Shukri Othman, senior consultant and lecturer Department of Obstetrics and Gynaecology Hospital USM , Dr Ghazali Ismail , head of department, senior consultant Department of Obstetrics and Gynaecology Hospital Tengku Ampuan Afzan Kuantan Pahang Darul Makmur (HTAA), all lecturers, consultants Dr Mokhtar Awang (HTAA) and Dr Lee Say Fat (HTAA), medical officers (USM), medical

officers (HTAA) and medical staff (HTAA) for their assistance and guidance through out the course of my training and preparation of this book.

I would also like to express my gratitude to my parent Abah & Umi and family especially my wife Noorazah bte Zakaria, my daughter Fatehah Ezzatunnur, and my son Muhammad Furqaan whose endless pray, understanding, sacrifices, support, encouragement and patience have guided me through my career.

Wassallam

ABBREVIATIONS

B-hCG	Beta Human chorionic gonadotrophin
CNS	Central Nervous Systems
CT	Computed tomography
D&C	Dilatation and curettage
DM	Darul Makmur
EMACO	Etoposide, Methotrexate, Actinomycin, Cyclophosphamide, Vincristine(Oncovin)
EGF	Endothelial growth Factors
GTD	Gestational Trophoblastic Disease
GTT	Gestational Trophoblastic Tumour
HLA	Human leukocyte antigen
HM	Hydatidiform mole
HPL	Human Placenta Lactogen
IM	Intramuscular
IL	Interleukins
HTAA	Hospita Tengku Ampuan Afzan Kuantan Pahang
MRI	Magnetic resonance imaging
OCP	Oral contraceptive pills
POA	Period of amenorrhoea
PTD	Persistent Trophoblastic Disease
RM	Ringgit Malaysia
TVS	Transvaginal scan
UK	United Kingdom
US	Ultrasound
USA	United State of America
PSTT	Placental site trophoblastic tumour
PHM	Partial Hydatidiform Mole
HPE	Histopathological examination
WHO	World health Organizations

C O N T E N T S

	PAGE
1 ACKNOWLEDGEMENTS.....	III
2 ABBREVIATIONS.....	V
3 THE STATE OF PAHANG.....	VII
5 INTRODUCTION TO HOSPITAL TENGGU AMPUAN AFZAN KUANTAN, PAHANG & DEPARTMENT OF OBSTETRICS AND GYNAECOLOGY.....	XI
6 ABSTRACT OF DISSERTATION	
A) BAHASA MALAYSIA VERSION.....	XVI
B) ENGLISH VERSION.....	XVIII
7 INTRODUCTION	1
8 OBJECTIVES.....	46
9 MATERIALS AND METHODOLOGY.....	47
10 RESULTS.....	58
11 DISCUSSIONS.....	120
12 SUMMARY	155
13 CONCLUSIONS.....	159
14 RECOMMENDATIONS.....	160
15 LIMITATIONS.....	162
16 BIBLIOGRAPHY.....	163



The

S T A T E O F
P A H A N G

THE STATE OF PAHANG

Evidence of habitation in Pahang dates back to the Mesolithic Era. Long famous for the deposits of tin and gold found along the upper reaches of the Tembeling River, Pahang had attracted the interest of outside powers long before the founding of Malacca in 1400. Under the control of the maritime empire of Srivijaya (centered around Palembang in southeast Sumatra), Pahang had expanded to cover the entire southern portion of the Malay peninsula in the eight and ninth centuries.

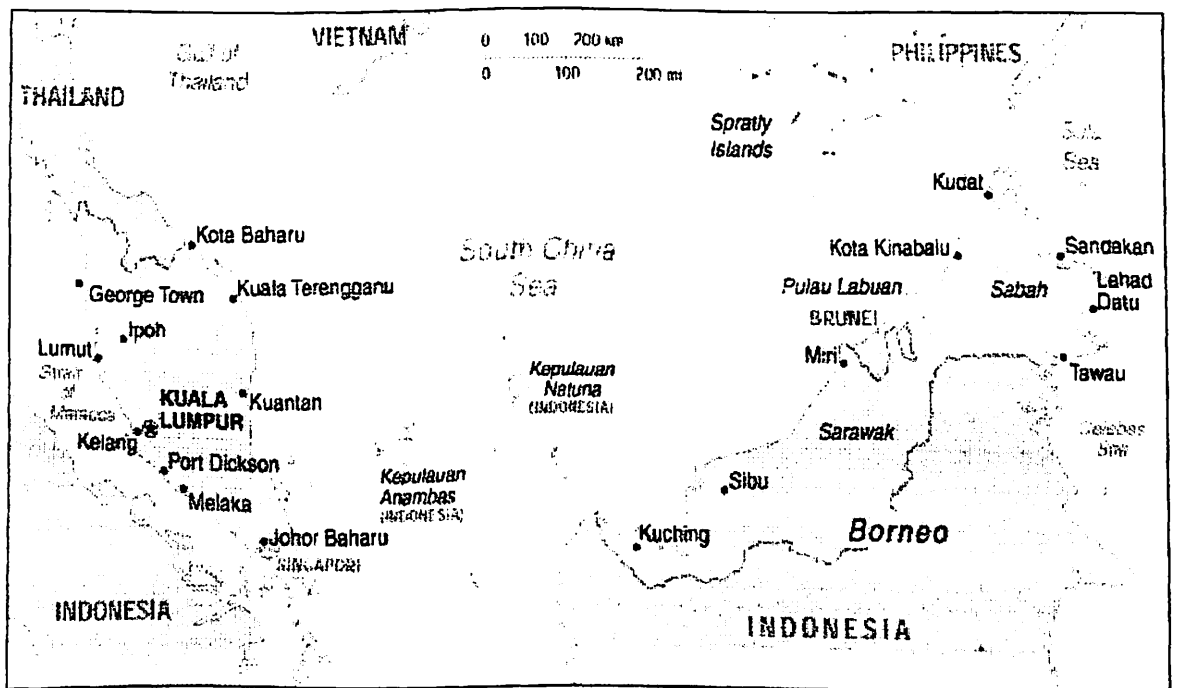


FIGURE 1: EAST AND WEST MALAYSIA

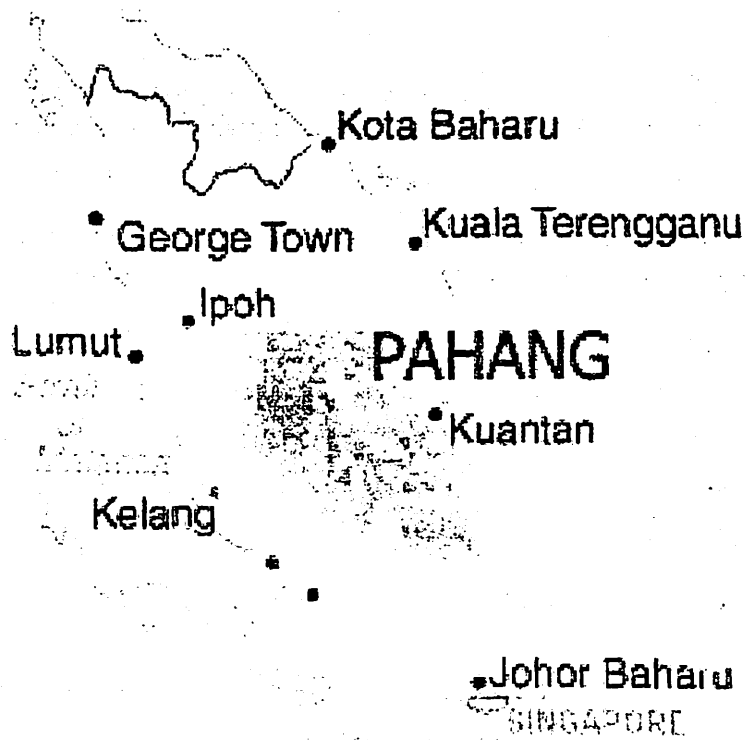


FIGURE 2: STATE OF PAHANG

With the collapse of Srivijaya power around 1000, Pahang was claimed first by the Siamese and then, in the late fifteenth century, by Malacca. After Malacca fell to the Portuguese in 1511, Pahang became a key part of the territorial struggles between Aceh, Johor, the Portuguese, and the Dutch. Repeated raids, invasions, and occupations devastated the state, until the decline of both Achenese and Portuguese power in the early 17th century allowed Johor (the successor state to Malacca) to reestablish its influence. In the late eighteenth century Pahang gradually gained

autonomy, and in the middle of the nineteenth century it had become an independent state.

Mention Pahang to a Malaysian, and he will probably conjure up visions of lush tropical forests, cool mountain air, beaches, lakes and waterfalls nestling in the arms of mountain crevices. The largest state in peninsular Malaysia is, in many ways, one of its most wild and Edenic. Two thirds of it is covered by unspoiled rain forest.

Visitors to Pahang are usually there to visit the state's famous hill resorts, its internationally-known islands and beaches, or Taman Negara, the Peninsula's finest park. Each of these attractions is substantial enough to merit special attention in our pages. Pahang's other attractions, though less well-known, should not be missed by anyone visiting the state

The natural heart of Pahang is unquestionably Taman Negara, Malaysia's oldest national park, lovingly referred to as "The Green Heart." Within the park is also the peninsula's highest point, the forest encrusted Gunung

Tahan. Also in the interior are many of Malaysia's hill stations, mountain resorts where the tropical heat is kept at bay by the altitude. On the coast of Pahang, the jungle gives way to clean, palm-lined beaches, fishing villages, and the multicultural state capital, Kuantan.

Pahang is the largest state in Peninsular Malaysia and is situated in the eastern coastal region. The state's 35,964 sq. km encompasses a remarkable range of Malaysia's many different environments, from the majestic peaks and cool hill regions of the state's western region to the miles of soft sand beach along the South China Sea. Pahang's nearly one million people constitute a representative mix of Malaysia's three main ethnic communities Malay, Chinese, Indian and Orang-asli. The total population of Malaysia in Census 2000, about 21,890 thousand or 94.1% were Malaysian citizens. Of the total Malaysian citizens, Bumiputera comprised 65.1%, Chinese 26.0% and Indians 7.7%, the ethnic composition being 60.6%, 28.1% and 7.9% respectively in 1991. Non-Malaysian citizens totalled 1,385 thousand (or 5.9%) in Census 2000 as against 805 thousand (or 4.4%) in 1991.



The

HOSPITAL TENGKU AMPUAN AFZAN KUANTAN PAHANG DM

H T A A

HOSPITAL TENGKU AMPUAN AFZAN

KUANTAN PAHANG D.M

Hospital Tengku Ampuan Afzan (HTAA) is the main hospital for the state of Pahang which is one of the component states of Malaysia . The Obstetrics and gynaecology unit provides specialist services as and integral part of the HTAA complex.

The Hospital consists of 900 beds and 1300 staff. It serves the town of Kuantan which is the capital own of the state of Pahang. It also serves as the referal centre for the outlying district hospital, out-patient clinic and the private medical practioners.

The department of obstetrics and gynaecology has five consultant specialist , five registrar, five medical officer and a minimum of ten house-officer . The trainees do an averages

number of eight calls a month . They involve actively in the management of emergency cases during on call under close supervision of the specialist consultants.

There are 36 bed in the antenatal ward cases which are admitted to the antenatal ward will usually be assessed in the screening / admission room . The Obstetrics unit also provides day care services to patients who come for observation for maternal and fetal well being or blood investigations such as blood sugar profile .

The Labour room has 10 beds of which 2 beds are used for monitoring of pre-eclampsia cases . Being a husband friendly ward , there are 3 beds whereby the patient's husbands or companion are allowed to be with the patients throughout process as well as during deliveries of the baby . For the year 1995-1999 ,there was a total number 39011 deliveries . In year 1999 total deliveries was 8647 . The statistics are as follows :

Table 2: Deliveries in HTAA in a year of 1999

Total number of deliveries	8647
Normal deliveries	7057
Breech deliveries	181
Twins	65
Triplet	1
Forceps	57
Vacum	81
Caesarian sections	1205 (13.9%)

The postnatal ward has 44 beds and being a baby friendly hospital almost 99% of the post natal mother achieves breast feeding fully. the gynaecological ward has 36 beds with an average admission of 10 cases a day and a total 331 admission for the year 1999.

There are two operative sessions per week for elective cases. The facility for caesarean sections is shared between the general operating theatre and the maternal operating theatre which is located adjacent to the labour ward.

We perform a wide variety of the gynecological operation which include total abdominal hysterectomy, vaginal hysterectomy, wertheim hysterectomy, oophorectomy, cystectomy, myomectomy, laparoscopic and hysteroscopy procedure, sterilization, culposuspension and minor procedure such as evacuation of product of conception and marsupilazation and so on.

The department also conduct regular teaching sessions such as the weekly registrar presentation, viva sessions, and journal club. We also have a regular caesarean audit and perinatal mortality and morbidity audit every fortnightly and a combined meeting with the paediatric department monthly.

Since 1999 HTAA also become the teaching hospital for the medical faculty of University Islam Antarabangsa (International Islamic University). With the Input of this university , the hospital is expected to be even better equipped

with medical facilities and have more academic programmes in the near future.

Table 3 : THE CLINIC SCHEDULE

DAY	Morning	Afternoon
Monday	Antenatal Clinic Day	Postgraduate programme
Tuesday	Gyneacology clinic	House Officer teaching session
Wednesday	Operation Day	Caesarean Census / Perinatal Morbidity and Mortality Census
Thursday	Gyneacology Clinic	Journal club
Friday	Operation Day	HPE or Oncology discussion
Saturday	Grand ward round/ IUI	



An

ABSTRACTS

(Malay version)

A B S T R A K

OBJECTIF : *Mengkaji epidemiologi dan keadaan penyakit , rawatan GTD dan melihat corak penurunan B-hCG penyakit H.M. Mengesan faktor yang boleh menambah risiko pembentukan GTT dan H.M..Membandingkan kesan rawatan yang diberi kepada GTT yang diketahui anteseden kandungan (H.M) dan GTT yang tidak diketahui anteseden kandungan.*

METODOLOGI: *Ia adalah kajian Cross-Sectional ke atas 96 pesakit GTD di Hospital Besar Tengku Ampuan Afzan Kuantan, selama 5 tahun(Januari 1995- Disember 1999).*

KEPUTUSAN: *Dalam kelahiran sebanyak 39,011 dalam tempoh kajian di HTAA terdapat 96 kes GTD, kadar GTD di Hospital 1:410 kelahiran. Kadar penyakit dilihat lebih kerap dalam golongan minoriti, umur 41 tahun dan ke atas , sosio-ekonomi yang rendah dan pariti lebih dari 5 . Gejala yang kerap dilihat ialah pendarahan haid yang tidak menentu, (87%). "Snow storm" dapat dilihat dengan ultrasound pada 74% pesakit.*

Pada pesakit Hydatidiform Mole didapati 64% mempunyai rahim besar dari tarikh amenorhea. Ujian bersiri serum bHCG (n=71) . 79%

(n=56) beransur susut dengan spontan dalam tempoh 14 minggu dan 21% (n= 15) pesakit mempunyai susutan yang tidak normal dan bertukar ke GTT. Faktor yang dapat mengesan risiko pembentukan GTT adalah umur 40 tahun ke atas, pariti lebih dari 5, rahim besar dari tarikh haid, bacaan awal BHCG > 100,000 miu/ml selepas evakuasi dan darah tinggi. Jenis HM, Theca lutein cyst, jenis darah tidak mempunyai risiko yang signifikan. Lapan puluh lima kes dirawat dengan 'cuci' (suction and curretages) dan 8 kes histerektomi (termasuk 7 pesakit di 'cuci' sebelum histerektomi). 62.5% dari pesakit GTT menerima regim kemoterapi risiko rendah. 17.4% menerima regim risiko sederhana dan 17.4% menerima regim risiko tinggi. Kita dapati tiada hubungan yang signifikan di antara dua status antesedan kandungan dalam konteks histerektomi, jenis kemoterapi dan respon terhadap kemoterapi dan kematian.

KESIMPULAN: *GTD berlaku pada kadar 1 dalam 410 kelahiran dan faktor risiko untuk bertukar ke GTT boleh dikenal pasti. Perhatian yang serius adalah penting lantas dapat merawat dengan betul. Harapan untuk sembuh dari penyakit GTD adalah besar walaupun telah menular ke GTT.*



An

ABSTRACTS

A B S T R A C T S

OBJECTIVES: *To study the epidemiology, features, treatment of Gestational Trophoblastic Disease (GTD) and regression of serum B-hCG in Hydatidiform mole. To identify factors that predict the risk of developing Gestational Trophoblastic Tumour (GTT) from Hydatidiform mole and to compare the outcome of treatment between Gestational Trophoblastic Tumour (GTT) from known antecedent pregnancy (Hydatidiform mole) and unknown antecedent pregnancy.*

METHODOLOGY: *A Cross Sectional study of 96 cases of Gestational Trophoblastic Disease in General Hospital of Tengku Ampuan Afzan Kuantan for a period of 5 years (January 1995-December 1999).*

RESULTS: *The prevalence rate of GTD in this hospital was 1 : 410 deliveries. There were 96 cases of GTD out of 39,011 deliveries. The prevalence rate was higher in the minority ethnic groups, women of lower socio-economic status, age ≥ 41 years and parity more than 5. The commonest presentations was irregular vaginal bleeding (87%). Typical snow storm appearance was seen in 74.4% of the patients .*

In patient with hydatidiform mole , 64% has uterus larger than date. In patient with available serial serum B-hCG (n=71), 79% (n=56)

regressed spontaneously within 14 weeks and 21% (n=15) had abnormal regression and were diagnosed to have Gestational Trophoblastic Tumour (GTT) . The significant risk predictors for development of GTT were age above 40 years , parity 5 and above, uterus larger than date , initial pre-evacuation B-hCG more than 100,000 miu/ml and pre-eclampsia. . Type of hydatidiform mole, presence and size of theca lutein cyst and blood group were not significant predictor of GTT. Eighty five patients were treated with suction curettage only and 8 patients (including 7 patients that had evacuation initially) had hysterectomy. 65.2% of GTT received low risk, 17.4% received moderate and 17.4% received high risk regime of chemotherapy. There was no significant correlation between GTT from known and unknown antecedent pregnancy in relation to hysterectomy, type of chemotherapy, response of chemotherapy and mortality.

CONCLUSIONS : *GTD occurred in about 1: 410 deliveries and risk factors for development of GTT had been identified. Close monitoring of GTD was mandatory so that appropriate management could be given. The prognosis for cure of these patients even when they developed GTT was good.*



An

INTRODUCTION

INTRODUCTION

Gestational trophoblastic disease is a spectrum of heterogenous conditions which arise from products of conception and which may threatened the livelihood and health of the young women . Although uncommon, its importance lies in the need for early recognition if the treatment is to be translated into cure and continued fertility. It is a health hazard which must be included in the differential diagnosis of a wide variety of clinical conditions.

CLASSIFICATION

Because the spectrum is wide and heterogenous, there have been several attempts to classify GTD. These were handicapped by plethora of terms which have been applied to this disease and the diversify of diagnostic tool available.

The World Health Organization (WHO) 1983 Classification

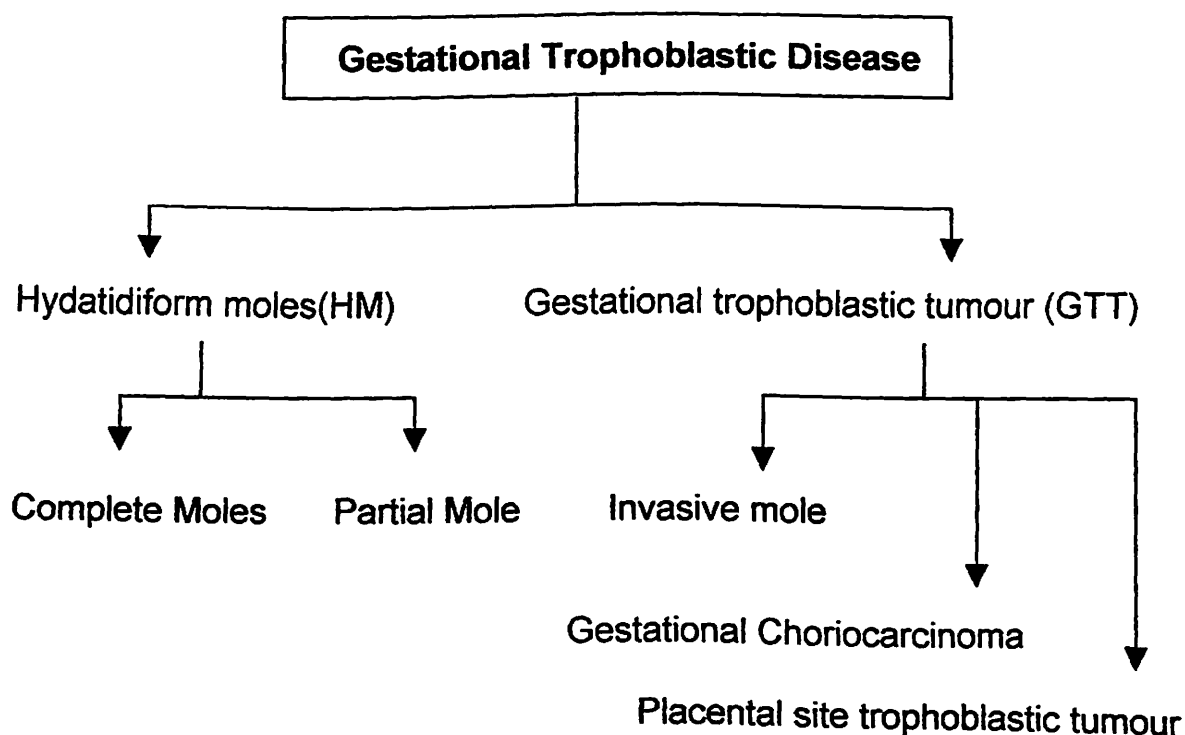


FIGURE 1: CLASSIFICATION OF GTD (WHO1983)

Gestational trophoblastic diseases (GTD) refer to both the benign and malignant permutations of proliferative trophoblastic allograft: Hydatidiform moles, invasive mole, choriocarcinoma, and placenta-site trophoblastic tumour (PSTT)

Hydatidiform mole : is a general term that includes two distinct entities, complete Hydatidiform mole and partial moles. (i) Complete mole : is an abnormal conceptus without the embryo or fetus characterized by loss of villous vascularity leading to gross hydropic swelling and central cistern formation and to pronounced cytotrophoblastic and syncytiotrophoblastic hyperplasia. (ii) Partial mole: is an abnormal conceptus with persistent embryonic and fetal elements and a placenta with a mosaic of normal -appearing villi alternating with areas of focal villous swelling and trophoblastic hyperplasia.

Invasive mole : is a Hydatidiform mole that has invaded the myometrium, metastasized, or both. It often progresses but usually regressed spontaneously.

Gestational Choriocarcinoma : is a malignant neoplasm of cytotrophoblastic and syncytiotrophoblastic elements without villous formation. It usually progresses and metastasizes and is fatal without treatment.

Placental site trophoblastic tumour : is composed mainly of cytotrophoblastic intermediates cells arising from the placental implantation.

CELLULAR CLASSIFICATION

Gestational trophoblastic tumors may be classified as follows: hydatidiform mole, chorioadenoma destruens (invasive mole), choriocarcinoma, and placental-site trophoblastic tumor. Hydatidiform mole is defined as products of conception that lack an intact fetus and show gross cyst-like swellings of the chorionic villi due to accumulation of fluid. There is disintegration and loss of blood vessels in the villous core.

Invasive mole (chorioadenoma destruens) is a locally invasive, rarely metastatic lesion characterized microscopically by trophoblastic invasion of the myometrium with identifiable villous structures. Microscopically, this lesion is characterized by hyperplasia of cytotrophoblastic and syncytial elements and persistence of villous structures.

Choriocarcinoma is a malignant tumor of the trophoblastic epithelium. Uterine muscle and blood vessels are invaded with areas of hemorrhage and necrosis. Columns and sheets of trophoblastic tissue invade normal tissues and spread to distant

sites, the most common of which are lungs, brain, liver, pelvis, vagina, spleen, intestines, and kidney.

Placental-site trophoblastic disease is an extremely rare tumor arising from the placental implantation site and resembles an exaggerated form of syncytial endometritis. Trophoblastic cells infiltrate the myometrium, and there is vascular invasion. Human placental lactogen is present in the tumor cells, while immunoperoxidase staining for HCG is positive in only scattered cells, and serum HCG is relatively low

GENERAL COMPARISON BETWEEN NORMAL PREGNANCY & GTD

Table 1: Comparison Between Normal Pregnancy And GTD

	NORMAL GESTATION	TRANSITIONAL MOLE	PARTIAL MOLE	COMPLETE MOLE	CHORIOCARCINOMA
Synonyms	"Gerber Baby"	"Blighted Ovum"	"Incomplete"	"Classic"	
Histology	Villi with fetal vessels.	Some swelling. Most normal villi with normal vessels.	Focal swelling of villi without vessels. Many are normal and contain vessels.	All villi swollen and empty (no vessels).	No villi.
	Single layer of cytotrophoblast and syncytiotrophoblast	Hypoplasia of cytotrophoblast and syncytiotrophoblast	Focal syncytial hyperplasia (scalloping).	Circumferential atypical overgrowth of cytotrophoblast and syncytiotrophoblast	All atypical overgrowth of cytotrophoblast and syncytiotrophoblast
	No cisterna		Few cisterna	Many cisterna	
B-hCG	hCG 50-100,000	hCG Low	HCG <50,000 (75%)	HCG >50,000 usually	hCG >50,000
Genetic	XX, XY 1:1	Trisomy Triploidy	Triploidy 80% 2:1	46XX 95% 2:0	
Baby Weight	Appropriate for Gestational Age	Small Gestational Age 85%	Small for gestational age 65%	Small for Gestational Age 33%	

Data from Kate O Hanlan MD Gynaecology Oncology ,Surgey, endoscopy
<http://www.ohanlan.com/tneoplasia.htm>

INCIDENCES

Table 2: Examples of Hydatidiform mole incidence by region (WHO 1983)

	Country	Period of study	Rate per 1000		
			Pregnancies	Deliveries	Live-births
Population Based Study					
Latin America	Paraguay	1960-1969	0.2	-	-
North America	Canada	1969-1973	-	-	0.7
	Greenland	1950-1974	-	1.2	-
	USA	1970-1977	1.1	-	-
Asia	Japan	1974-1980	1.96	-	-
	Singapore	1963-1965	-	1.2	-
Europe	Norway	1953-1961	-	0.8	-
Hospital based Study					
Africa	Nigeria	1969-1973	-	5.8	-
	Nigeria	1974-1977	-	2.6	-
	Nigeria	1966-1975	-	1.7	-
	Uganda	1967-1970	-	1.0	-
Latin America	Jamaica	1953-1967	-	1.0	-
	Mexico	1961-1965	4.6	-	-
	Venezuela	1939-1968	0.9	1.1	1.1
North America	USA	1930-1965	0.7	-	-
	Alaska	1969-1974	-	3.9	-
	USA	1932-1942	-	0.5	-
	Hawaii	1951-1965	0.8	-	-
	Hawaii	1950-1970	-	-	1.0
Asia	China	1951-1960	-	8.0	-
	Indonesia	1962-1963	10.0	11.6	-
	Iraq	1960-1964	4.5	-	-
	Iran	1964-1965	7.8	10.6	-
	Iran	1970-1975	3.2	-	-
	Israel	1950-1965	-	-	0.8
	Japan	1972-1977	1.9	2.6	-
	Lebanon	1956-1960	2.6	-	-
	Malaysia	1972-1976	-	1.5	-
	Philippines	1955-1957	1.1	-	-
	Thailand	1966-1972	2.8	2.9	-
Europe	Italy	1961-1974	-	0.8	-
Oceania	Australia	1940-1959	-	2.4	-
	Australia	1950-1966	0.9	1.0	-

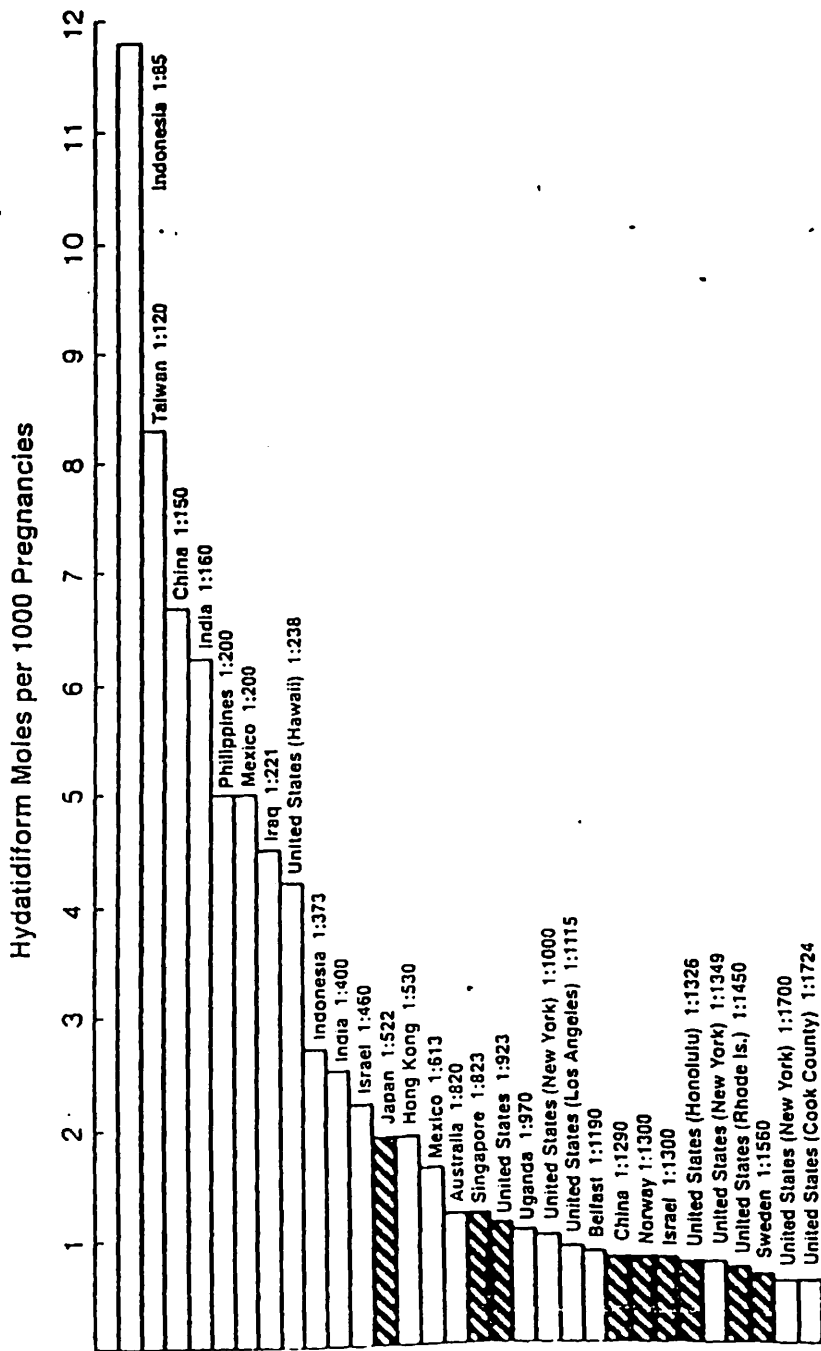


FIGURE 2: THE REPORTED INCIDENCE OF HYDATIDIFORM MOLE BY COUNTRY: SHADED BAR, THE RESULTS OF STUDIES OF A DEFINED POPULATION; OPEN BARS, ESTIMATE FROM THE RECORDS OF ONE OR MORE HOSPITALS (Buckley J.D 1984)

PREGNANCY IMMUNOLOGY

The uterus is not an immunologically privileged site. Fetal tissue, as well as trophoblastic neoplasia, does demonstrate antigenic immaturity with respect to ABO and HLA. There is, importantly, a nonantigenic barrier formed by the syncytiotrophoblastic cells which produce a mucoprotein layer of sialomucin, which is protective. Furthermore, maternal immunoglobulins recognizing any foreign antigens will attach to this basement membrane and function as "blocking antibodies" covering the antigens. Despite this, due to significant normal vascular invasion by the trophoblast, some of the epithelial cells of the villi will "deport", and travel through the venous return through the heart, imbedding in the lung parenchyma.

GENETIC BACKGROUND

Hydatidiform can be categorized as either complete mole or partial mole on the basis of karyotype, gross morphology, and histopathology as table below: Palmer JR (1994)

Table 3: General Comparison between Complete & Partial Mole

Characteristic	Complete Mole	Partial Mole
Karyotype	46, XX (90%) 46, XY (10%)	Triploid(90%)
Fetal Tissue	Absent	Present
Hydatidiform swelling	Extensive	Limited
Trophoblastic hyperplasia	Extensive	Limited

Data from Kate O Hanlan MD Gynaecology Oncology, Surgery, endoscopy
<http://www.ohanlan.com/tneoplasia.htm>

Complete moles lack identifiable embryonic or fetal tissue, the chorionic villi exhibit generalized hydropic swelling and diffuse trophoblastic hyperplasia, and implantation site trophoblast has diffuse and marked atypia.

GROWTH FACTORS & ONCOGENES

The excess of paternal chromosomes in moles probably contributes to the induction of trophoblastic hyperplasia . The genomic imbalance may cause changes in the gene expression of growth factors located on the paternal allele (Berkowitz RS, et al 1985). An insulin growth factors (IGF2) specifically located on the paternal allele may be inappropriately expressed in molar pregnancies, thus stimulating uncontrolled growth.

Both normal placentas and molar pregnancies contain paternal antigens; therefore, upon implantation , an immunologic response is initiated with infiltration of lymphocytes and macrophages and secretion of cytokines. The growth of choriocarcinoma may be related to the abundant expression of epidermal growth factor receptor. Macrophage derived cytokines interleukin (IL-1 alpha, Il-1 beta), and tumour necrosis factor can suppress cell growth and increase EGF receptor expression in choriocarcinoma cell lines, thus acting as paracrine mediators of cell growth.

The contribution of several oncogenes to the malignant transformation of GTD also has been examined. Growth regulation in the trophoblast recently has been found to be associated with expression of the transcription factor Mash-2. Cheung et al (1993) have demonstrated increase expression of c-fm RNA in complete mole compare with that in normal placenta . In choriocarcinoma, increase expression of c-myc and ras RNA has been observed. At present, the significance of these findings is uncertain. Because trophoblast are, by nature, rapidly dividing and invasive, increase expression of these oncogenes may be essential for normal cell function. Further studies are needed to elucidate these findings. Recently, expression of the c-erb B-2 oncogene product in persistent GTD was examined and found to have a significant contribution. Thus far, no gene mutation or rearrangement in GTD have been reported.

Progression of the tumour has been associated with the inactivation of tumour suppressor gene. The inactivation of p53 by mutation of the p53 gene has been observed in nearly 50% of patient with ovarian cancer. Expression of p53 in hydatidiform moles has recently been studied. Expression of p53 in

hydatidiform mole was observed to be increased over that normal trophoblast. No p53 mutation were found and further noted an over accumulation of p53 protein in 50% choriocarcinoma and 78% of hydatidiform moles but none in partial mole and normal placenta. Increase p53 expression may thus be an attempt to abrogate excessive trophoblast proliferation in hydatidiform moles.

Table 3.1: Clinicopathological Characteristic Of The Various Classes Of Molar Pregnancy

Features	Complete mole	Partial Mole	Transitional Mole
Synonym	Classic; True	Incomplete	Blighted Ovum
Villi	Pronounced swelling of all villi	Crinkled hydropic villi are focal , haphazard : many villi normal	Cystic, hydropic and normal
Trophoblast	Cyto and syncytial hyperplasia is variable	Mostly syncytial hyperplasia; focal and mild	No hyperplasia, may be hypoplasia
Embryo	Dies very early : No remnant found	Usually dies by 9 weeks ; may survive till term	Amnion and slanted embryo
Villous capillaries	No fetal Red blood cell	Many fetal red blood cell	Present
Gestational Age	8-16 weeks usual	10-22 weeks	6-14 weeks
HCG values	>50,000 miu/ml	75% <50,000miu/ml	Low
Malignant Potential	15-25%	5-10%	Slight, if any
Karyotype	46,XX (95%) 46, XY (10%)	Triploid (80%)	Trisomic, triploid

Data from Szulman and Surti 1984

STAGE INFORMATION

Hydatidiform mole (molar pregnancy) is disease limited to the uterine cavity. Invasive mole (chorioadenoma destruens) is a locally invasive, rarely metastatic lesion.

The FIGO staging system is as follows:

Stage I: Disease confined to the uterus

Stage IA: Disease confined to the uterus with no risk factors

Stage IB: Disease confined to the uterus with one risk factor

Stage IC: Disease confined to the uterus with two risk factors

Stage II: GTT extends outside of the uterus but is limited to the genital structures (ovary, tube, vagina, broad ligament)

Stage IIA: GTT involving genital structures without risk factors

Stage IIB: GTT extends outside of the uterus but limited to genital structures with one risk factor

Stage IIC: GTT extends outside of the uterus but limited to the genital structures with two risk factors

Stage III: GTT extends to the lungs, with or without known genital tract involvement

Stage IIIA: GTT extends to the lungs, with or without genital tract involvement and with no risk factors

Stage IIIB: GTT extends to the lungs, with or without genital tract involvement and with one risk factor

Stage IIIC: GTT extends to the lungs, with or without genital tract involvement and with two risk factors

Stage IV: All other metastatic sites

Stage IVA: All other metastatic sites, without risk factors

Stage IVB: All other metastatic sites, with one risk factor

Stage IVC: All other metastatic sites, with two risk factors

Table 4: Staging and survival rate of GTT

Staging of Gestational Trophoblastic Tumour		
		5 – Years Survival
Stage 0	Hydatidiform mole	100%
Stage I	Persistent Hydatidiform mole	100%
Stage II	Metastases to pelvis or vagina	80 - 100%
Stage III	Metastases to lung	100%
Stage IV	Metastases to liver, brain, etc.	40 -80%

Data from Kate O Hanlan MD Gynaecology Oncology ,Surgey, endoscopy
<http://www.ohanlan.com/tneoplasia.htm>

HUMAN CHORIONIC GONADOTROPIN ASSAY

Success in the treatment of GTD has been achieved in part because of the technical ability to quantitate serum or urinary concentrations of human chorionic gonadotrophin (hCG). Regular monitoring of hCG concentrations during treatment provides information regarding disease status and the response to therapy that permits appropriate intervention on an individualized basis. The hCG assay thus has become essential to the clinical management of trophoblastic disease, and basic understanding of the assay methods and their limitations is the important for the clinician involved in the care of these patients.

It has recently been recognized that hCG is present in patients in multiple forms : intact hCG, nicked hCG where the binding site of the tumour has been split, hCG which has lost the carboxy terminal part of the beta subunit, free beta and beta core fragment . Early in a normal pregnancy the majority of hCG is in intact form and nicking occurs increasingly through the

pregnancy. In GTT there is a much higher proportion of hCG degradation products present and not all pregnancy test detect these efficiently. The ideal hCG test for monitoring GTT is one which detects all the beta epitopes present in intact hCG through the beta core fragment. (Cole et al 1994).

Human chorionic gonadotrophin (hCG) is a sensitive and specific marker for the diagnosis and treatment of gestational trophoblastic tumour. Bagshawe (1976) defined the risk more specifically, noting the fatality rate of 4 % if the hCG was less than 10,000 IU, 15% at 10,000 – 100,000 IU, 27 % at 100,000-1,000,000 IU and 61% when the level was greater than 1,000,000 IU. Lurain et al (1982) reported that hCG level greater than 100,000 IU /L were significantly associated with fewer remission in patients with metastatic GTT.

The usefulness of the HCG subunit assays in the prediction of the development of malignant disease has not been settled. Recent reports suggest that secretion of free b-hCG subunit in comparison to whole HCG secretion showed an increasing trend from pregnancy to mole to choriocarcinoma, and the free b-hCG subunit level may be used in the prediction of GTD (Patillo & Houssa 1984, Khazaeli 1986, Fan 1987). Free b-hCg subunit secretion appeared to be related to the maturity or degree of

differentiation of the trophoblast. Nigerian pregnant women were found to secrete a persistently higher percentage of alfa - hCG free subunit when compared with American pregnant women (Elegbe 1984). During the IVth World Congress of Gestational Trophoblastic Disease held in Beijing in October 1988, preliminary results of b-hCG core fragment estimation reported that this may be useful for the early diagnosis of malignant disease during the follow up of mole patients. Ma H.K. et al (1990).

Normal postmolar pregnancy curve for serum b-hCG

RIA

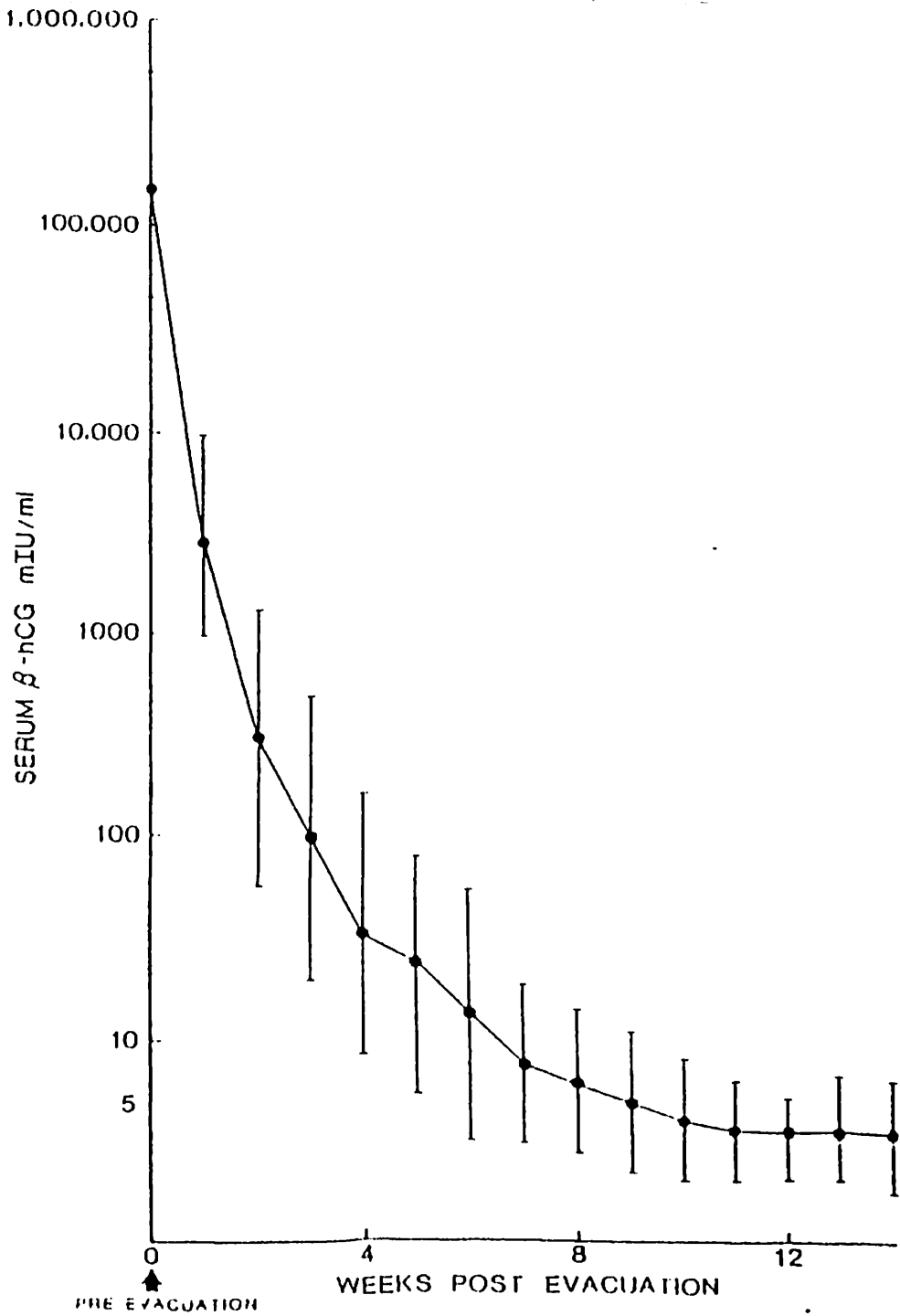


FIGURE 3: NORMAL POST MOLAR PREGNANCY CURVE FOR SERUM B-hCG RIA. VERTICAL BARS INDICATE THE 95% CONFIDENCE LIMIT (Morrow et al 1998)

Abnormal Regression of serum hCG

Brewer et al (1971), Bagshawe et al (1973) provide a basis for the interpretation of post molar gonadotrophin values relative to the diagnosis of GTT and the need of therapeutic intervention. Brewer et al (1971) reported that by 60 days after molar evacuation, approximately 70% of their patients achieved a normal hCG level, that is, less than 25miu/ml. An additional 15% demonstrates continuous drop in their values, although the values were still higher than normal. In the remaining 15% of the group with an elevated hCG at 60 days after evacuation, the values were either plateau or rising.

COMPLETE HYDATIDIFORM MOLE

This entity is characterized by the absence of a fetus and a uterus filled by grossly swollen avascular villi made up of oedematous stroma surrounded by hyperplastic syncytiotrophoblast. The incidence, which is difficult to determine and varies geographically, is approximately 1 per 1000 live births. Genetically it is usually diploid.

Symptomatology

Patients with Hydatidiform mole present as a complication of an existing pregnancy and a positive pregnancy test. The presenting symptoms can be bleeding, passage of grapes like product or hyperemesis gravidarum (30%). Pain is not a dominant symptom.

Clinical sign .

These patients are usually well with no overt distress or haemodynamic compromise but they may be pale. If hyperemesis is present, they may be signs of dehydration and ketosis.

In 65% of patients, uterine examination will reveal a fundal height discordant with gestational age. The consistency of the uterus is doughy rather than cystic.

Vaginal examination may confirm bleeding or a dilated cervix with vesicles products of conception in the vagina.

Twenty percent of patients will show features of pre-eclampsia. Proteinuric hypertension before 20 weeks of pregnancy should raise the possibility of GTD. Hyperthyroidism may manifest as clinical thyrotoxicosis in 10% of cases.

Diagnosis and investigation

The ultrasound appearance of an enlarged uterus with echolucent black hole surrounded by a rim of white is absolutely specific. Abdominal x ray may provide useful information (an absent fetal skeleton) and excessive opacification in the region of the uterine shadow. But if ultrasonography not available, patients with suspected molar disease, if at all possible, should be referred to an institution with this facility. Pelvic angiography and amniography are specific but excessively invasive. Extensive investigation for metastatic disease is not