

# Rapid Diagnosis Of *Helicobacter Pylori* In Gastric Imprint Smear

Gurjeet Kaur, M Madhava, Amir Hakim B\*, Abd Hamid MS\*\*, Mohd Syaiful BH\*\*,  
NN Naing\*\*\*

Departments of Pathology, \*Medicine, \*\*Surgery, \*\*\*Unit of Epidemiology and Medical  
Statistics, Universiti Sains Malaysia, Kota Bharu, Kelantan, Malaysia

## Objective

To determine the sensitivity, specificity, negative (NPV) and positive predictive values (PPV) of Diff-Quick-stained gastric imprint cytology smears in the detection of *H. pylori* against histology.

## Methodology

Air-dried imprint smears from 100 gastric biopsies were stained immediately by Diff-Quick method in the endoscopy suite and the presence or absence of *H. pylori* was determined by a single pathologist within minutes. The same biopsy was processed by routine histology and Warthin-Starry stain. These were reviewed by another pathologist blind to the imprint cytology results.

## Results

Sixty of the 100 patients were males with a mean age of 50 years. Based on histology, *H. pylori* prevalence was 11%. Sensitivity and specificity of imprint cytology were 81.8% and 100% respectively. NPV was 97.8% and PPV was 100%. There were no false positives. Two positive cases on imprint smear were initially diagnosed as negative on histology but on review, minimal numbers of *H. pylori* were found in the biopsies. There were two false negative cases.

## Discussion

The Diff-Quick staining of imprint smears was rapid and simple and no support staff was required. Bacteria were easily visualized. Though reliable, this method may not be sensitive enough or cost-effective in an area with a low prevalence of *H. pylori* infection. Conclusion: Gastric imprint smears stained with Diff-Quick method is a rapid and reliable method for detection of *H. pylori*.

**RAPID DIAGNOSIS OF *HELICOBACTER PYLORI*  
INFECTION IN GASTRIC IMPRINT SMEAR**

**Dr Gurjeet Kaur,  
Department of Pathology,  
School of Medical Sciences,  
Universiti Sains Malaysia.**

**8 January 2003.**

**Research Grant**

Universiti Sains Malaysia short-term research grant,  
304/PPSP/6131180.

**RAPID DIAGNOSIS OF *HELICOBACTER PYLORI* INFECTION IN  
GASTRIC IMPRINT SMEAR**

**Dr Gurjeet Kaur,  
Department of Pathology,  
School of Medical Sciences,  
Universiti Sains Malaysia.**

**8 January 2003.**

**Research Grant**

Universiti Sains Malaysia short-term research grant, 304/PPSP/6131180.

# **RAPID DIAGNOSIS OF *HELICOBACTER PYLORI* INFECTION IN GASTRIC IMPRINT SMEAR**

Gurjeet Kaur, MD, MMed(Pathology), MIAC;

Manoharan Madhavan, MBBS, MD, MIAC;

Amir Hakim Basri, MD, MMed(Internal Medicine);

Abdul Hamid Mat Sain, MBBS, MS, FRCS, MD;

Mohd. Shaiful Bahrin Hussain, MBBS, MMed(Surgery);

Mohd. Kamal Yatiban, MD, MMed(Surgery);

Nyi Nyi Naing, MBBS, DTM&H, MSc(CTM), MPH, MMed Stats.

---

From the Departments of Pathology, Medicine, Surgery and Unit of Biostatistics and Research Methodology, School of Medical Sciences, Universiti Sains Malaysia, Kubang Kerian, 16150 Kelantan, Malaysia.

Source of financial support: This work was supported by the Universiti Sains Malaysia short-term research grant, 304/PPSP/6131180. The authors have no connection to any companies or products mentioned in this article.

**Running title:** Rapid diagnosis of *H pylori*

**Keywords:** *H pylori*, gastric imprint, Diff-Quik

## **ABSTRACT**

**OBJECTIVE:** To determine the sensitivity, specificity, positive (PPV) and negative predictive values (NPV) of Diff-Quik-stained gastric imprint cytology smears in the detection of *H pylori* against histology.

**STUDY DESIGN:** Air-dried imprint smears of gastric biopsies from 150 patients were stained by Diff-Quik method in the endoscopy suite and examined for *H pylori*, providing results within minutes. Presence of inflammation and intestinal metaplasia were documented. The same biopsy was processed and stained with H&E and Warthin-Starry, and reviewed by a different pathologist blind to the imprint cytology results.

**RESULTS:** Ninety-four of the 150 patients were male with a mean age of 50 years. Based on histology, *H pylori* prevalence was very low at 8%. Sensitivity and specificity of imprint cytology in the detection of *H pylori* were 83.3% and 100% respectively. The PPV and NPV were 100% and 98.6% respectively. There were two false negatives and no false positives. A combination of imprint cytology and histology achieved 100% sensitivity. Imprint smears did not provide added value over histology with regards to inflammation and metaplasia.

**CONCLUSION:** Gastric imprint smears stained with Diff-Quik method is a rapid, cheap and reliable method for detection of *H pylori* and has best results when complemented with histology.

## INTRODUCTION

*Helicobacter pylori* colonization of the gastric mucosa is associated with the pathogenesis of gastritis, peptic ulcer disease and gastric malignancy. As eradication of this organism has become part of clinical practice, much research has been done in assessing the sensitivity and reliability of the available diagnostic methods for the detection of this organism.<sup>1</sup> Though culture is the gold standard, it lacks sensitivity, is technically difficult and costly. Urease test and histological examination of gastric specimens are frequently used methods in this country while histology is the only method employed in our institution with a turnaround time of several days.

Cytology of gastric brushings and imprint smears have been described as reliable methods for detection of *H pylori*.<sup>2-11</sup> The Papanicolaou and May-Grunwald-Giemsa staining methods are widely used and the procedures take about 30 minutes. The Diff-Quik staining method is even more rapid, cheap and can be performed in the endoscopy suite with identification of *H pylori* made within minutes.

The aim of this study was to determine the sensitivity, specificity, positive (PPV) and negative predictive values (NPV) of Diff-Quik-stained gastric imprint smears in the detection of *H pylori* compared to histology of the same biopsy used for imprint. It was also hoped that its usefulness as a diagnostic method could be determined in this region of the country, an area with a low prevalence of *H pylori* infection.<sup>12,13</sup> The value and agreement of signs of inflammation and intestinal metaplasia of imprint compared to histology were also of interest.

## MATERIALS AND METHODS

A total of 150 patients undergoing oesophago-gastro-duodenoscopy (OGDS) for upper gastrointestinal symptoms were included in the study, which had prior approval from the ethical committee of this institution. Exclusion criteria included patients undergoing OGDS as an emergency procedure and in which stomach biopsies were not indicated such as oesophageal and other systemic diseases. During endoscopy three gastric biopsies are usually taken, two from the antrum and one from the body. In this study only one of the gastric biopsy specimens, preferably from the antrum, was rolled gently on a clean glass slide using a forceps to make an imprint smear before placing it in 10% formalin for subsequent histopathological examination. Only one gastric imprint smear per patient was prepared. The smears were air-dried and stained by Diff-Quik (Lab Aids Pty Ltd) method by a pathologist in the endoscopy suite. This staining method took an average of 2 minutes. The smears were then air-dried, mounted and examined for *H pylori* under 400x magnification. The bacterium was identified by its spiral or S shaped morphology and purple-violet colour within the well-preserved gastric mucus. Presence of neutrophils, large number of lymphocytes, lymphoid aggregates and goblet cells reflecting intestinal metaplasia were documented when present.

The gastric biopsy was processed in the usual way for histology and stained with haematoxylin and eosin (H&E) and Warthin-Starry for *H pylori* detection. The slides were reviewed by a different pathologist, blinded to the imprint cytology results. Besides identification of *H pylori*, other parameters such as grade of chronic inflammation, activity, and intestinal metaplasia were also determined.

The results of imprint smears in the detection of *H pylori* were compared to histology. The sensitivity, specificity, positive and negative predictive values were calculated. As for the other variables such as inflammation and metaplasia, imprint smears and histology were compared.

## RESULTS

Ninety-four of the 150 patients were male with a mean age of 50 years (range 11 to 84 years). The ethnic composition of the patients was as follows: Malay 110 (73.3%), Chinese 28 (18.7%), Indian 6 (4%) and 'Other races' 6 (4%) which comprised 2 Thai, 2 Pakistani, 1 Burmese and 1 Iraqi.

The Diff-Quik staining method was simple and rapid, taking about 2 minutes. Imprint smears produced good cytologic preparations. The cellular content was adequate and gastric mucus stained a light violet. Only two smears had poor cellularity. *H pylori* was easily visualized within the gastric mucus (Figure 1). Although other bacteria were also stained by the Diff-Quik method, the characteristic spiral shape of *H pylori* proved its positive identification.

Gastric biopsy specimens from which imprint smears were made were of good quality and histological examination was not compromised in any way.

Based on histology, the overall *H pylori* prevalence in this endoscoped population was 8% (12/150). The frequency of *H pylori* infection among the endoscoped population according to the ethnic distribution was as follows: Malay 3/110 (2.7%), Chinese 7/28 (25%), Indian 1/6 (16.7%), and one Burmese.

Sensitivity and specificity of imprint cytology compared to histology for identification of *H pylori* were 83.3% and 100% respectively. PPV was 100% and NPV was 98.6% (Table 1). There were two false negative cases. Two positive cases on imprint smear that were initially diagnosed as negative on histology showed low density of *H pylori* on review. Sensitivity, specificity, PPV and NPV of 100% was achieved if imprint cytology and histology were combined.

There was very poor agreement between imprint smears and histology with regards to inflammation, and intestinal metaplasia. The presence of lymphocytes or lymphoid aggregates on imprint smears did not correspond to chronic inflammation or its severity in histology. Goblet cells were not identified in imprint smears and noted in only 2 biopsies of *H pylori*-positive cases. Of the 12 subjects with *H pylori* infection, only 2 showed presence of neutrophils on imprint smears while activity was seen in 11 cases in histology.

## DISCUSSION

The available methods for the detection of *H pylori* organisms are many and broadly categorized as invasive and non-invasive methods.<sup>1-11</sup> Invasive methods that require gastrointestinal endoscopy and biopsy of the stomach, include culture, histology, urease tests and cytology. Non-invasive techniques comprise breath tests and serology. Histology is often accepted as the “gold standard” in diagnosing *H pylori* infection as culture has marked limitations. Information with regards to histopathology of the gastric mucosa is an important advantage. As *H pylori* is found in the gastric mucus on the surface epithelium and gastric foveolae, cytology of imprint smears and brushings have proven be reliable methods for its detection.<sup>2-10</sup> Previously reported studies used various combinations of technique and staining methods. Brushings and touch imprints were common while stains used included Papanicolaou, May-Grunwald-Giemsa, Hema-Gurr and Diff-Quik. We decided that performing imprint smears of gastric biopsy specimens before routine histological processing added no extra procedure or inconvenience on the endoscopist or patient. Comparing imprint smears and matching histology was ideal in eliminating sample bias.

Imprint smears provided good cellularity and one smear per patient was adequate. Epithelial and inflammatory cells as well as *H pylori* were easily visualized with the Diff-Quik stain. Other bacteria often present in de-acidified stomachs may be confused with *H pylori*. However the characteristic morphology of *H pylori* can be readily made on 400x magnification.

The Diff-Quik staining procedure was simple and rapid, requiring no additional staff besides the pathologist who stained and interpreted the imprint smears. The turnaround time was on average 10 minutes compared to three to five days for a histological report. This provides a tremendous advantage as therapy can be commenced before the patient leaves the endoscopy suite on the same day.

The sensitivity of *H pylori* detection in brush or imprint cytology using various stains has been reported to be between 71% and 100% while specificity was 90% to 100%.<sup>3-9</sup> In our study the sensitivity and specificity of imprint cytology compared to histology were 83.3% and 100% respectively. The PPV was 100% and NPV was 98.6%, which is comparable to another study quoting PPV as 93.8% and NPV of 94.6% of Diff-Quik-stained gastric antral brushings.<sup>5</sup> False negatives can arise when the bacteria load is poor as was seen in two of our subjects. Review of the imprint smears were confirmed negative while the biopsies revealed low density and patchy distribution of the organism. On the other hand, two *H pylori*-infected patients were identified by imprint smears but not by histology (H&E and Warthin-Starry). Careful scrutiny of the biopsies showed a low and patchy bacterial load again. The density of *H pylori* organisms seen on imprint smears did not reflect that seen in biopsies. In subjects with low bacterial load, imprint smears and gastric brushings probably provide better sampling of *H pylori*, which reside in the gastric surface mucus layer. Brushing technique has the disadvantage of requiring an added procedure. Variable loss of this mucus layer is unavoidable during histological processing. The sensitivity in our study is affected by the low bacterial load and to a certain extent the low

prevalence of *H pylori* in the study population. However imprint cytology combined with histology achieved 100% sensitivity.

Though Warthin-Starry was performed to facilitate identification of *H pylori*, it is expensive and in the hands of experienced pathologists, can be omitted.

Inflammatory changes on imprint smears did not correlate well with histology and therefore did not provide any added value though it was considered useful in a previous study.<sup>4</sup> It is clear that histological examination is necessary to provide information on mucosal inflammation, metaplasia, atrophy and other histopathological changes.

The quality of gastric biopsies from which the imprints were made was not adversely affected, and proper histological examination could be done, validating previous studies.<sup>2,9</sup> With this advantage imprint cytology can easily complement histological examination with minimal added cost.

The prevalence rate of *H pylori* infection of 8% among an endoscoped population is unusually low but it is in concordance with previous studies done in this region of the country.<sup>12,13</sup> The interesting ethnic distribution of *H pylori* infection, being very low in the Malays (2.7%) compared to non-Malays (20%) is also a commonly reported phenomenon in this multiracial country.<sup>14,15</sup> The predominant Malay population in this part of the country lowers the prevalence rates even further. This being so, the value and cost effectiveness of imprint cytology is questionable when taking into consideration the whole patient population undergoing endoscopy. However, with a higher index of suspicion of *H pylori* infection among the non-Malays, imprint

cytology may prove to be of great added value as infected patients can begin therapy immediately.

## CONCLUSION

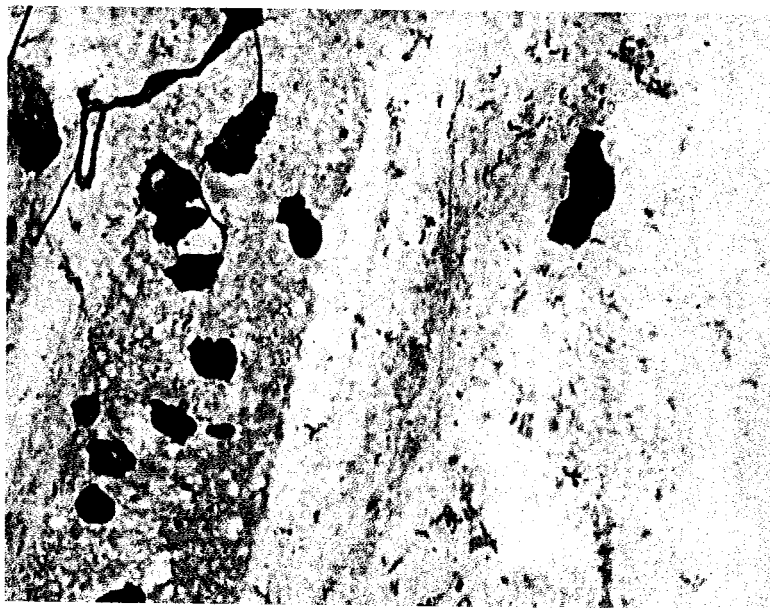
Air-dried gastric imprint smears stained by Diff-Quik method is a simple, rapid, cheap and reliable method in detection of *H pylori* with an enormous advantage of immediate commencement of eradication therapy. This technique can achieve maximum sensitivity and added useful information when combined with histological examination, especially in ethnic groups that have a higher prevalence of the infection.

## REFERENCES

1. Loffeld RJLF, Stobberingh E, Arends JW. A review of diagnostic techniques for *Helicobacter pylori* infection. *Dig Dis* 1993;11:173-180.
2. Debongnie JC, Delmee M, Mainguet P, Beyaert C, Haot J, Legros G. Cytology: A simple, rapid, sensitive method in the diagnosis of *Helicobacter pylori*. *Am J Gastroenterol* 1992;87:20-23.
3. Trevisani L, Sartori S, Ruina M, Caselli M, Abbasciano V, Grandi E, et al. Touch Cytology. A reliable and cost-effective method for diagnosis of *Helicobacter pylori* infection. *Dig Dis Sci* 1997; 42:2299-2303.
4. Pinto MM, Meriano FV, Afridi S, Taubin HL. Cytodiagnosis of *Campylobacter pylori* in Papanicolaou-stained imprints of gastric biopsy specimens. *Acta Cytol* 1991;35:204-6.
5. Carmona T, Munoz E, Mar Abad M, Paz JI, Gomez F, Alonso MJ, et al. Usefulness of antral brushing samples stained with Diff-Quik in the cytologic diagnosis of *Helicobacter pylori*. A comparative methodologic study. *Acta Cytol* 1995;39:669-672.
6. Mendoza ML, Rabadan PM, Carrion I, Morillas JD, alonso GL, Rubio MD. *Helicobacter pylori* infection. Rapid diagnosis with brush cytology. *Acta Cytol* 1993;37:181-5.
7. Faraker CA. Diagnosis of *Helicobacter pylori* in gastric brush and biopsy specimens stained by Rowmanowsky and immunocytochemical methods: comparison with the CLOtest. *Cytopathology* 1996;7:108-119.

8. Rey E, Carrion I, Mendoza ML, Rubio MD. Imprint cytology in the diagnosis of *Helicobacter pylori* infection. *Acta Cytol* 1997;41:1144-1146.
9. Cubukcu A, Gonullu NN, Ercin C, Alponat A, Kaur AC, Canturk Z et al. Imprint cytology in the diagnosis of *Helicobacter pylori*. Does imprinting damage the biopsy specimen? *Acta Cytol* 2000;44:124-127.
10. Rodriguez IN, Santamaria JS, Rubio MMA, Acevedo JMP, Jaen MP, Orellana AMC et al. Cytologic brushing as a simple and rapid method in the diagnosis of *Helicobacter pylori* infection. *Acta Cytol* 1995;39:916-919.
11. Mason CH, Coghill SB, Champ CS. Identification of *Campylobacter*-like organisms in gastric brushings(letter). *Acta Cytol* 1989;33:284-285.
12. Uyub AM, Raj SM, Visvanathan R, Nazim M, Aiyar S, Anuar AK et al. *Helicobacter pylori* infection in north-eastern peninsular Malaysia. Evidence for an unusually low prevalence. *Scan J Gastroenterol* 1994;29:209-13.
13. Kaur G, Raj SM. A study of the concordance between endoscopic gastritis and histological gastritis in an area with a low background prevalence of *Helicobacter pylori* infection. *Singapore Med J* 2002; 43:90-2.
14. Goh KL. Prevalence of and risk factors for *Helicobacter pylori* infection in a multiracial dyspeptic Malaysian population undergoing endoscopy. *J Gastroenterol Hepatol* 1997;12:S29-35.
15. Goh KL, Parasakhti N. The racial cohort phenomenon: seroepidemiology of *Helicobacter pylori* infection in a multiracial South-East Asian country. *Eur J Gastroenterol Hepatol* 2001;13:177-83.

**Figure 1.** *H pylori* and gastric epithelial cells in gastric imprint cytology (Diff-Quik, x 400)



**Table 1.** Comparison of gastric imprint smear to matching histology in *H pylori* detection.

Imprint smear cytology	Gastric biopsy histology	
	Positive	Negative
Positive	10	0
Negative	2	138