

Pseudocolouring Enhancement Processing Of Ovarian Ultrasound Images

Nafiza Saidin¹, Umi Kalthum Ngah², Mohd Yusoff Mashor³

^{1,2,3}School of Electrical & Electronic Engineering, Universiti Sains Malaysia, Engineering Campus,
14300 Nibong Tebal, Penang, Malaysia.

¹Tel: +604-5937788 x 6049, Fax: +604-5941023, E-mail: faza_02@hotmail.com

²Tel: +604-5937788 x 6022, Fax: +604-5941023, E-mail: umi@eng.usm.my

³Tel: +604-5937788 x 6013, Fax: +604-5941023, E-mail: yusof@eng.usm.my

ABSTRACT

Image processing may be employed on ovarian ultrasound images to assist doctors in diagnostic analysis. The gray levels of ovarian images are usually concentrated at the zero end of the spectrum, making the image too low in contrast and too dark for the naked eye. This paper examines the effectiveness in displaying monochrome ultrasound images as colour images and proposes a pseudocolouring approach for enhancing features in ultrasound ovarian image, which allows easy discrimination of texture information. A combination of the pseudocolouring method with other image enhancement manipulations such as contrast stretching and seed based region growing was also investigated. The combination of the pseudocolouring approaches with the other image enhancement techniques can dramatically increase the information in ovarian ultrasound.

Keywords: Ultrasound, medical imaging, image enhancement, pseudocolouring

1. INTRODUCTION

Ultrasound is non-invasive and does not interfere with physiological functions. The use of ultrasound enables observation of structures in the female pelvis. The gray levels of ovarian ultrasound images are usually concentrated at the zero end of the spectrum, making the image too low in contrast and too dark for the naked eye. Image processing is used to help doctors or sonographers to better diagnose these images.

The effectiveness in displaying monochrome ultrasound images as colour images is examined and a pseudocolour enhancement technique for enhancing features in ultrasound ovarian image is presented. Hence, a pseudocolouring method is proposed, which allows an easy discrimination of texture information. The aim of this study is to evaluate the effectiveness of pseudocolouring ultrasound image in diagnosis of ovarian cyst.

Much more visual contrast is noticeable in the colour images than in the gray level images, which consequently, enables the viewer to better delineate the detail of the organ structure. Attention is given to delineate the anechoic and hypoechoic region with the other region such as moderately echogenic, iso-echogenic and hyperechoic. Intensity or luminance value of the output or the colour image is increased such as the intensity or luminance of the input gray level image. A combination of this pseudocoloring method with other image enhancement techniques such as contrast stretching and seed based region growing is also introduced. The combination of the pseudocoloring approaches with the other image enhancement techniques can dramatically increase the information in ovarian ultrasound images.

The shape and intensity of the echoes depends on how dense the tissue is. Since each colour in the pseudocoloured image enhanced image represents a similar region, e.g. hypoechoic or hyperechoic region, its impedance between tissues can easily be determined. This paper also discusses the selection of colours and presents a scheme, which uses the RGB uniform colour space to select 256 colours for replacing the 256 gray shades used to represent the monochrome image.

2. ULTRASOUND INTERPRETATION OF OVARIAN CYST

Two-dimensional ultrasound of the female pelvis has been established for several decades as the most reliable and effective way to image the uterus and ovaries and the surrounding structures.

Ultrasound is the primary imaging tool for a patient considered having an ovarian cyst. Findings can help define morphologic characteristics of ovarian cysts. Endovaginal ultrasound can help in a detailed morphologic examination of pelvic structures. This requires a hand-held probe to be inserted into the vagina. Transabdominal ultrasound is more preferable than endovaginal ultrasound for evaluating large masses. However, it requires a full bladder [1].

The majority of ovarian masses are simple cysts. Ultrasound is valuable in differentiating cystic from solid masses. Ultrasound criteria for a simple cyst and a complex cyst are shown on *Table 1* [2-6]. Since conventional ultrasound image is in gray level, doctors have to be skillful in interpreting the image. Benign lesions are often associated with posterior enhancement, malignant lesions with posterior shadowing and simple cysts with relative posterior hyperechogenicity. Computerized analysis allows for an objective assessment of posterior acoustic shadowing which is an important factor in the discrimination of cysts from non-cysts. Accurate identification of lesion margin and shape is generally difficult in ultrasound images. The focus of the research presented in this paper is therefore to investigate the use of pseudocolouring features describing the lesion, extracted from two dimensional (2D) ovarian ultrasound images for the characterization

Table 1 The Criteria for A Simple Cyst and A Complex Cyst.

Characteristic	Simple Cystic	Complex Cystic
Shape of mass	Unilocular (solitary) spherical	Multilocular (more than 1 compartment)
Internal Consistency	-No internal echo -Homogenous -Anechoic/, hypoechoic (fluid) contents	-Internal echo (containing bot a cyst, and solid component) -Heterogenous -Variuos echogeneicity (ranging from anechoic to echogenic)
Definition of border	-Well defined	-Moderately well define
Common	Functional ovarian cyst (follicular and corpus luteum) Cystic Teratoma Para-Ovarian	-Hemorrhagic cyst -Endometriomas -Ectopic pregnancy -Cystadenoma -Hydrosalpinx -Abscess -Teratoma (dermoid)
Uncommon	Serous cystadenomas, inclusion cyst	Polycystic ovary
Malignant potential	Low	Intermediate/High
Posterior details	Posterior hyperechogenicity or good acuastic enhancement	Posterior enhancement/ Shadowing

3. ULTRASOUND IMAGE AND PSEUDOCOLORING

The basic aim of image enhancement is to highlight or enhance particular aspects of an image. Images such as an ultrasound image can be made more susceptible for interpretation by a doctor or sonologist. A simple method of pseudocoloring ultrasound gray level images is proposed. In many applications, the human eye is more sensitive to colour changes rather than to intensity changes [7-9]. Therefore, it is natural to encode the intensity of gray level images by using colour information. This process is called pseudocoloring. A pseudocolour enhancement technique is normally applied to a single band monochrome image in digital image processing. It is considered an effective way of highlighting different but apparently homogeneous areas within an image by 'slicing' the range of grayscale values and assigning different colours to each of those slices. The technique utilizes the knowledge that gray levels (intensities) in the image represent the linear absorption coefficients of the elements in tissues and groups pixels with similar gray levels and hence similar absorption coefficients into a region, with colour representing the region. The colour assignment to each of the gray level section was chosen on a trial and error basis. Much more visual contrast is noticeable in the colour images than in the gray level images, which consequently, enables the viewer to better delineate the detail of the organ structure. Pseudocoloring allows an easy discrimination of texture information.

The majority of the techniques perform a gray level to colour transformations. The idea is to perform 3 transformations on a particular gray level and to feed these to the three colour inputs (RGB) of a colour monitor. The result is a composite image whose colour content depends on the gray level to colour transformations. The algorithm used to perform pseudocoloring is:

$$c(x,y) = T(f(x,y)) \quad (\text{Eq. 1})$$

where $f(x,y)$ is a gray level image. Pixels with low values are assigned dark gray-levels, and high pixel values are assigned bright gray-levels. $c(x,y)$ is a colour image. It is usually expressed in terms of its red, green and blue components $c = [c_R, c_G, c_B]$. The transformation function T produces a three-channel output [10-14].

Pseudocoloring is usually judged only subjectively. There is two different ways to find pseudocoloring transformations. The first method is based on intensity quantization. N is the total number of

region with different colour and L is the total number of gray level.

Another modification of image intensity pseudocoloring is based on arbitrary image thresholding. In this case, a set of $N - 1$ thresholds f_i , $i = 1, \dots, N-1$, is defined by the user. The transformation function takes the form:

where $f(k,l)$ is the original intensity of the gray level

$$T(f(k,l)) = \begin{cases} c_i & \text{if } i \left\lfloor \frac{L}{N} \right\rfloor \leq (f(k,l)) < (i+1) \left\lfloor \frac{L}{N} \right\rfloor, \\ & i = 0, 1, \dots, N-2 \\ c_{N-1} & \text{if } (N-1) \left\lfloor \frac{L}{N} \right\rfloor \leq (f(k,l)) < L \end{cases} \quad (\text{Eq. 2})$$

image. It must be noted that all transformations are point wise non-linear operator. This study concentrate on the second, approach, which is arbitrary image

$$T(f(k,l)) = \begin{cases} c_0 & 0 \leq f(k,l) < f_1 \\ c_i & f_i \leq f(k,l) < f_{i+1}, \\ & 1 \leq i \leq N-2 \\ c_{N-1} & f_{N-1} \leq f(k,l) < L \end{cases} \quad (\text{Eq. 3})$$

thresholding pseudocoloring the ultrasound gray level image. The thresholding is chosen based on the echo pattern of ultrasound image.

There are various approaches for assigning colour to gray-level images. Attention is given to delineate the anechoic and hypoechoic region with the other region such as moderately echogenic, echogenic and hyperechoic.

The focus in this pseudocoloring method is to highlight the differential between anechoic and hypoechoic region with anechoic and hyperechoic region. The increase in luminance of the output colour image is proportional to the luminance of the gray scale image. As the gray level values increase from low to high value, this mapping produces colour varying from dark colour to light colour.

It is important to maintain the tone between hypoechoic region and echogenic region because an ultrasound image is interpreted based on the tone. Arbitrary image thresholding can be used to implement the transformation. Pseudo 2 uses the same concept as Pseudo 1, with a similar hue chosen to represent the echo pattern. On the other hand, Pseudo 3 and 4 emphasizes a different colour to represent anechoic and hypoechoic region compared to the other regions. This pseudocoloring technique is demonstrated on an ultrasound image of ovarian cysts. Fig. 1 (a) shows an

ovarian cyst which appears as a relatively dark region, whereas the surrounding solid tissues appear brighter. Fig. 1 (b) is the histogram of the ovarian ultrasound image, which indicates that the gray level image is usually concentrated at the zero end of the spectrum.

The results of pseudocoloring are shown in Fig. 1 (c)-(f) for four types of pseudocolouring (Pseudo 1 – Pseudo 4), with transparent fluid represented by a dark colour, whereas solid tissues appear brighter

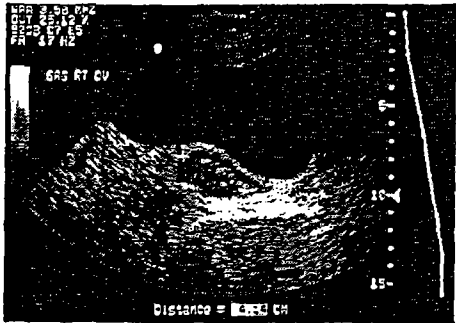


Fig. 1 (a) Gray Level Image of Ovarian Cyst

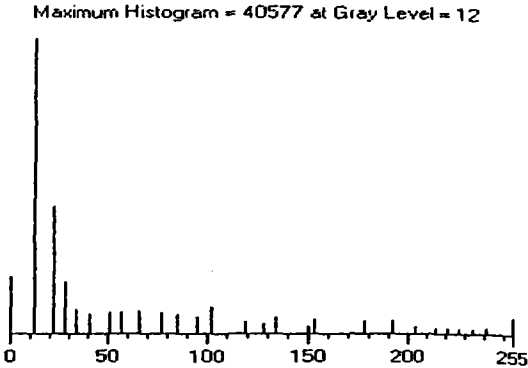


Fig. 1 (b) Histogram of Image (a)

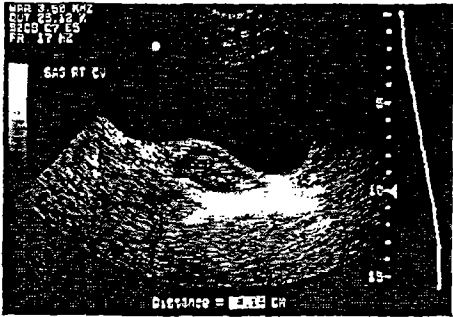


Fig. 1 (c) Pseudo 1 of Image (a)

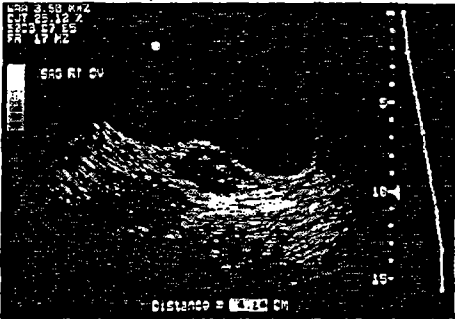


Fig. 1 (d) Pseudo 2 of Image (a)

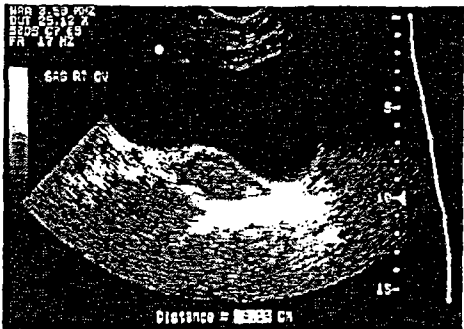


Fig. 1 (e) Pseudo 3 of Image (a)

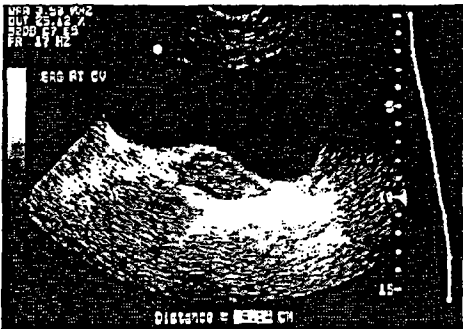


Fig. 1 (f) Pseudo 4 of Image (a)

Fig. 1 Gray Level and Pseudocolour Ultrasound Image of Ovarian Cyst.

4. OTHER IMAGE ENHANCEMENT WITH PSEUDOCOLOURING

An effective image enhancement method for ovary ultrasound will provide better input not only for visual inspection by doctors or sonographers but also for medical imaging applications such as ovarian cyst border detection. Part of the goal of this study is to further enhance the image contrast while maintaining information.

Ultrasound images with less contrast should be pre-processed before the pseudocolouring method is applied. Contrast stretching can elevate the contrast, while region selection can highlight area of interest. The seed based region growing can segment the disease area and pseudocolouring can enhance particular differences of impedance between tissues. The combination of the image enhancement techniques such as contrast stretching, region selection, seed based region growing and the pseudocolouring approach can dramatically improve the contrast and provide more information in the ovarian ultrasound images.

The seed based region growing is a segmentation method to segment a region of interest (ROI). In the seed based region growing, a pixel in the region is used as a seed point and then all the similar pixels (spatially close pixels sharing the same features, i.e. neighbors) are gathered together in the same region. The region growing method for defining ROI is based on gray scale difference. It has the

potential to improve clinical diagnosis and research. Defining the ROI is one of the most important steps in characterizing the tissue since it forms the basis for all the subsequent steps.

A local rectangular region centered at the point is defined. If this rectangular satisfies a certain local homogeneity criterion, it is taken as the seed region. Otherwise, the region is contracted successively until the contracted region satisfies the homogeneity criterion. Once the seed region is determined in this way, the next step is to grow the homogeneous region by absorbing a thin rectangular adjacent side region, which has the same statistical properties as that of the current region. *Fig. 2 (a)* is an ultrasound image of endometriomas, which appear as spherical lesions. Contrast Stretching applied to image (a) is shown in *Fig. 2 (b)*. Referring to *Fig. 2 (c)*, the hypoechoic part is better segregated from the echogenic part through the use of pseudocolour. For images containing multiple follicles as in *Fig. 3 (a)*, an ROI can be chosen to highlight the region, which contain the cysts and to avoid the detection of edge outside the region when the seed based region growing is applied. The seed based region growing that is used for thresholding contains a similar amount of pixels from the cysts and from the surrounding tissue. *Fig. 3 (b)* shows multiple follicles, which appear as black bubbles. The anechoic portion is better demarcated from the echogenic part using pseudocolouring

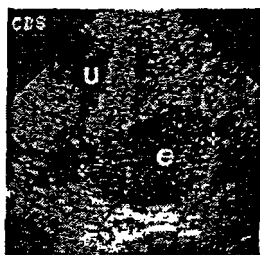


Fig. 2 (a) Original Image of Endometriomas Posterior

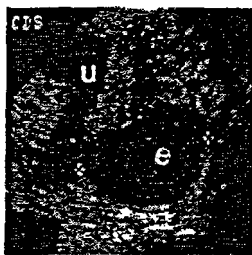


Fig. 2 (b) Image 1 Processed by Contrast Stretching (CS).

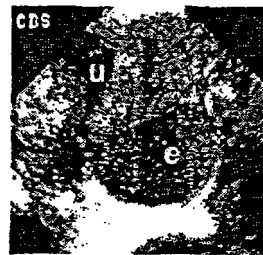


Fig. 2 (c) Image 2 Processed by CS and Followed by

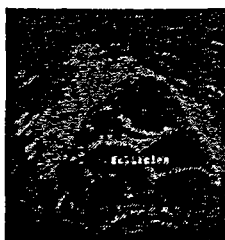


Fig. 3 (a) Original Image of Multiple Follicles Cyst.

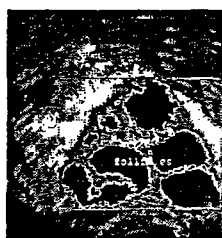

Fig. 3 (b) Processed Image 3 with ROI, Seed Based Region Growing and Followed by Pseudocolouring.

5. CONCLUSION

A method of pseudocolouring in ultrasound images has been proposed. The potential of the method was demonstrated using images of ovarian cyst. The technique is effective not only for detection but also for subjective visual enhancement of images. In the context of image enhancement however, it may be of value to include the information, if the resultant images are more easily interpretable. The models developed in this study can be used as part of a computer-aided-diagnosis system to characterize ovarian lesions. To conclude, computerized analysis of ultrasound images has the potential to increase the specificity of ovarian ultrasound and to aid in better characterization of cystic lesions.

6. REFERENCE

- [1] C. William Helm "Ovarian Cyst", Radiology - Obstetrics/gynecology Articles, (August 2002). URL <http://www.emedicine.com/MED/topic1699.htm>
- [2] Sandra Hagen-Ansert, Edward A. Lyons, "Sonographic Assessment Of The Adnexa", Online CME Course, GE Medical Systems, (April 1999). URL <http://www.gemedicalsystems.com/cgi-bin/print/print.cgi>
- [3] Aniruddha Malpani, Dr. Anjali Malpani, "Ultrasound - Seeing with Sound", from the book How to have a baby: Overcoming Infertility. (2002). URL <http://www.drimalpani.com/book/chapter9a.html>
- [4] Dr. W. Romano, Dr. Dean Smith, UWO Clinical Clerkship Teaching Files, Radiology in Obstetrics and Gynecology, (August 2001). URL <http://www.med.uwo.ca/ume/radiology/yea3/main/OBGYN.htm>
- [5] Ibrahim I Bolaji, "Grimsby Basic Transvaginal Ultrasound Workshop ", Northern Lincolnshire and Goole Hospitals, (2003).
- [6] Thomas M. Lehmann, Andreas Kaser and Rudolf Reppes, "A simple parametric equation for pseudocoloring grey scale images keeping their original brightness progression", Image and Vision Computing 15, (1997) 251-257.
- [7] Richard N. Czerwinski, Douglas L. Jones, William D. O'Brien, Jr., "Linear Feature Enhancement by False Color", IEEE 5 Ultrasonics Symposium, (1996).
- [8] Gonzalo E. Diaz Murillo, "High Tech Medical Projects: Ultrasound Color Processing and tissue characterization Color Based Ultrasound CAD (Computer Aided Detection System)" . (1996). URL <http://www.drgdiaz.com/index.shtml>

- [9] Tomihisa Welsh ,Michael Ashikhmim, Klaus Mueller, "Transferring Color to Greyscale Images" , SIGGRAPH 2002, Conference Proceeding 21, (July 2002), 277-280.
- [10] Jang-Hee Yoo and See-Young Oh, "A Coloring Method of Gray-Level Image using Neural Networks", Network Computing Department, Systems Engineering Research Institute, (2002).
- [11] I. Pitas, Digital Image Processing Algorithms and Application, John Wiley & Sons, Inc. , New York, pp. 166-167, 1999.
- [12] Rafael C. Gonzalez, Richard E. Wood, Digital Image Processing, Prentice Hall, Pearson Education International, (2002).
- [13] Aristofanes C. Silva, Paulo Cezar P. Carvalho,"Visualization of Density Variation in Lung Nodules" , (May 2002).
- [14] Shawn Daly, Eric Outwater, "Endometrioma/Endometriosis", Radiology - Obstetrics/gynecology Articles (December 2001).
URL<http://www.emedicine.com/radio/topic250.htm>