

KELOID: MULTICENTRE STUDY ON THE OUTCOME OF MULTIMODALITY MANAGEMENT

DR NICHOLAS FRANKLIN TOW MUN CHONG

DISSERTATION SUBMITTED IN PARTIAL FULFILLMENT OF THE
REQUIREMENT FOR THE DEGREE OF MASTER OF SURGERY
(PLASTIC SURGERY)



UNIVERSITI SAINS MALAYSIA

2020

Acknowledgement

First and foremost, I would like to offer this endeavour to Almighty God for gathering and organising all that is invaluable towards the completion of this dissertation. I would like to extend my highest regards to my ever supportive parents, family and friends for their lifelong contribution to my career.

I would also like to express my deepest gratitude and appreciation to the following individuals who has extended unconditional help throughout this journey: -

- My beloved supervisor, Y.Bhg. Prof. Dato' Dr. Ahmad Sukari Halim for his precious time, guidance, advice and encouragement.
- All my patients who took the time to take part in this study.
- The Plastic & Reconstructive Surgery Unit of Hospital Kuala Lumpur (HKL) and Reconstructive Sciences Unit of Hospital Universiti Sains Malaysia (USM) for their diligent assistance.
- Last but not least, to my fellow colleagues and researchers for their kind help.

Table of Contents

	Acknowledgement.....	ii
	Table of Contents.....	iii
	List of Tables.....	vii
	List of Figures.....	viii
	List of Appendices.....	ix
	List of Abbreviations.....	xi
	Abstrak.....	xiii
	Abstract.....	xv
1	Introduction.....	1
	1.1 Background.....	1
	1.1.1 Definition of Keloids.....	1
	1.1.2 Aetiology.....	1
	1.1.2(a) Genetics and Immunology.....	2
	1.1.2(b) Environmental Triggers.....	4
	1.1.3 Pathomechanisms.....	6
	1.1.3(a) Normal Wound Healing.....	6

	1.1.3(b)	Pathological Wound Healing in Keloid Scarring.....	11
	1.1.4	Clinical Features.....	15
	1.1.5	Management Options for Keloids.....	16
	1.1.6	Management in Our Setting.....	16
	1.1.7	Intralesional Triamcinolone Acetonide (TAC) Injection.....	17
	1.1.8	Scar Massage.....	20
	1.1.9	Algorithm for Management of Keloids.....	20
	1.1.10	Patient Observer Scar Assessment Scale (POSAS).....	22
1.2		Aims of research study.....	28
1.3		General objective.....	28
1.4		Specific objectives.....	28
1.5		Hypotheses.....	28
2		Methodology.....	29
	2.1	Study Design.....	29
	2.2	Study Area.....	29
	2.3	Study Population.....	29
	2.4	Subject Criteria.....	30
	2.4.1	Inclusion Criteria.....	30

	2.4.2	Exclusion		30
		Criteria.....		
	2.4.3	Withdrawal Criteria.....		30
2.5	Sample		Size	31
		Calculation.....		
2.6	Sampling Method.....			32
2.7	Data		Collection	32
		Method.....		
2.8	Study		Flow	33
		Chart.....		
2.9	Statistical			34
		Analysis.....		
2.10	Budget Proposal.....			38
2.11	Gantt	Chart	and	38
		Milestones.....		
2.12	Ethical Considerations.....			38
2.13	Benefits of the Research.....			40
3	Results.....			41
3.1	Descriptive	Analysis	for	41
		Demography.....		
3.1.1	Age,	Gender	and	42
		Ethnicity.....		
3.1.2	Site.....			42
3.1.3	Inciting			42
		Events.....		

3.1.4	Duration between Injury and Onset of Keloid.....	44
3.1.5	Duration of Keloid before First Visit.....	44
3.2	POSAS Analysis.....	45
3.2.1	Descriptive Analysis.....	46
3.2.1(a)	Patient Scale.....	46
3.2.1(b)	Observer Scale.....	48
3.2.2	One-way Repeated Measures ANOVA and Bonferroni Post-hoc.....	50
3.2.2(a)	POSAS Patient Scale – Overall Score.....	50
3.2.2(b)	POSAS Patient Scale – Total Score	53
3.2.2(c)	POSAS Observer Scale – Overall Score	56
3.2.2(d)	POSAS Observer Scale – Total Score.....	59
3.2.2(e)	Percentage of Improvement of POSAS Patient Scale Scores	65
3.2.2(f)	Percentage of Improvement of POSAS Observer Scale Scores..	69
4	Discussion.....	70
5	Conclusion.....	82
6	References.....	83
7	Appendices.....	89

LIST OF TABLES

Table	Page
3.1 Patient Demographic and Clinical Data	41
3.2 POSAS Patient Scale Results over 5 Visits	46
3.3 POSAS Observer Scale Results over 5 Visits	48
3.4 POSAS Patient Scale – Overall Score: Multivariate Test and Sphericity	50
3.5 Comparison of POSAS Patient Scale – Overall Score by Bonferroni’s Post-hoc Test	51
3.6 POSAS Patient Scale – Total Score: Multivariate Test and Sphericity	53
3.7 Comparison of POSAS Patient Scale – Total Score by Bonferroni’s Post-hoc Test	54
3.8 POSAS Observer Scale – Total Score: Multivariate Test and Sphericity	56
3.9 Comparison of POSAS Observer Scale – Overall Score by Bonferroni’s Post-hoc Test	57
3.10 POSAS Observer Scale – Total Score: Multivariate Test and Sphericity	59
3.11 Comparison of POSAS Observer Scale– total Score by Bonferroni’s Post-hoc Test	60
3.12 Percentage of Improvement of POSAS Patient Scale Scores	65
3.13 Percentage of Improvement of POSAS Patient Scale Scores	69

LIST OF FIGURES

Figure	Page
1.1 The temporal patterns of repair phase, cellular influx, and vascular response during wound repair events	6
1.2 The SMAD signal-transduction pathway as a downstream mediator of TGF- β action	14
1.3 Review of the evidence and current developments in corticosteroid intralesional injection treatments	18
1.4 TAC (Shincort by Y.S.P. Industries) in 10mg/ml TAC Preparation	19
1.5 Scar Management Algorithm	22
1.6 POSAS Patient Scale	24
1.7 POSAS Observer Scale	25
1.8 Directions for assessment of parameters of Observer Scale	26
2.1 Sample Size Calculation	31
2.2 Study Flowchart	33
3.1 Error Bar Plots of POSAS Patient Parameter Scores	62
3.2 Error Bar Plots of POSAS Patient Overall and Total Scores	63
3.3 Error Bar Plots of POSAS Observer Parameter Scores	66
3.4 Error BarPlots of POSAS Observer Overall and Total Scores	67

LIST OF APPENDICES

Appendix	Page
A Ethical Approval Letters	89
B Patient Information Sheet and Informed Consent Form (English)	95
C Patient Information Sheet and Informed Consent Form (Bahasa Malaysia)	99
D Data collection sheet	103
E Translated and validated version of POSAS (Patient Scale) in Bahasa Malaysia	137
F Gantt Chart and Milestones	138
G POSAS Patient Scale – Overall Score: Mauchly’s Test, Multivariate Test, Test of Within-subjects Effects	139
H POSAS Patient Scale – Overall Score: Pairwise Comparisons	141
I POSAS Patient Scale – Overall Score: Histograms and Boxplots of Residuals	142
J POSAS Patient Scale – Total Score: Mauchly’s Test, Multivariate Test, Test of Within-subjects Effects	147
K POSAS Patient Scale – Total Score: Pairwise Comparisons	149
L POSAS Patient Scale – Total Score: Histograms and Boxplots of Residuals	150
M POSAS Observer Scale – Overall Score: Mauchly’s Test, Multivariate Test, Test of Within-subjects Effects	155
N POSAS Observer Scale – Overall Score: Pairwise Comparisons	157
O POSAS Observer Scale – Overall Score: Histograms and Boxplots of Residuals	158
P POSAS Observer Scale – Total Score: Mauchly’s Test, Multivariate Test, Test of Within-subjects Effects	163

Q	POSAS Observer Scale – Total Score: Pairwise Comparisons	165
R	POSAS Observer Scale – Total Score: Histograms and Boxplots of Residuals	166
S	CD with SPSS data set	171

LIST OF ABBREVIATIONS

$\alpha_v\beta_3$	Alpha-v beta-3
ANOVA	Analysis of Variance
ECM	Extracellular matrix
EGF	Epidermal growth factor
FGF	Fibroblast growth factor
GAG	Glycosaminoglycans
G -G	Greenhouse – Geisser
H ₂ O ₂	Hydrogen peroxide
HTS	Hypertrophic scar
IFN- γ	Interferon – γ
IGF	Insulin-like growth factor
IL	Interleukin
KGF	Keratinocyte growth factor
LT	Leukotriene
NO	Nitrous oxide
OPN	Osteopontin
PDGF	Platelet-derived growth factor
PG	Prostaglandin
PGI	Prostacyclin
POSAS	Patient observer scar assessment scale
SE	Standard Error
SMAD	fusion of <i>Caenorhabditis elegans</i> Sma genes and the <i>Drosophila</i> Mad, Mothers against decapentaplegic

TAC	Triamcinolone acetonide
TNF- α	Tumor necrosis factor – α
TGF- β	Transforming growth factor – β
TX	Thromboxane
VEGF	Vascular endothelial growth factor
vWF	Von Willerbrand factor

HASIL RAWATAN KELOID DENGAN PELBAGAI MODALITI DI KALANGAN PUSAT-PUSAT RAWATAN

Abstrak

Pengenalan: Parut keloid adalah sejenis ketumbuhan fibroblas dermal yang tidak merbahaya. Ia melibatkan pemendapan komponen – komponen matrik ekstraselular seperti kolagen, fibronectin, elastin, proteoglycans dan “growth factor” seperti TGF- β secara berlebihan. Kondisi ini adalah amat sukar dirawat, walaupun dengan penggunaan pelbagai strategi rawatan yang kerap diperhatikan dalam amalan klinikal harian. Oleh itu, pelbagai modaliti rawatan disyorkan digunakan bersama untuk pengawalan optimum penyakit ini. Kajian ini bertujuan menilai hasil rawatan parut keloid dengan suntikan triamcinolone acetonide (TAC) dan urutan parut di hospital-hospital tempatan, bagi menentukan rawatan optima untuk parut keloid bagi populasi tempatan.

Kaedah: Ini adalah kajian prospektif yang dijalankan di Unit Sains Rekonstruktif, Hospital Universiti Sains Malaysia (Hospital USM) dan Jabatan Pembedahan Plastik dan Rekonstruktif, Hospital Kuala Lumpur (HKL). Kajian ini melibatkan pengumpulan skor – skor POSAS dari pesakit – pesakit keloid di sepanjang rawatan dengan suntikan TAC dan urutan parut. Skor – skor POSAS ini akan digunakan untuk menganalisis hasil rawatan keloid bagi populasi Malaysia.

Keputusan Kajian: Hasil rawatan dianalisis dengan menggunakan 'one-way repeated measures ANOVA'. Kesemua komponen-komponen pesakit dan pemerhati POSAS menunjukkan penambahbaikan parut keloid dari awal hingga ke penghujung rawatan. Komponen pesakit: kesakitan (39.04%), kegatalan (36.45%), ketebalan (30.40%), ketegangan (23.62%), ketidaksekataan (20.50%), warna (10.18%) (NS), secara keseluruhan (20.50%) and total (26.74%). Komponen pemerhati: vaskulariti (44.19%), kelegaan (36.94%), ketebalan (34.67%), keluasan permukaan (34.55%), kelembutan (34.22%), pigmentasi (16.58), secara keseluruhan (34.63%) and total (33.93%). Skor-skor pesakit secara keseluruhan dan total menunjukkan penambahbaikan yang ketara dengan perbezaan mean 1.43 ($p=0.016$) dan 9.50 ($p<0.001$) masing-masing, dan skor-skor pemerhati secara keseluruhan dan total menunjukkan penambahbaikan yang ketara dengan perbezaan mean 2.99 ($p<0.001$) dan 9.30 ($p<0.001$) masing-masing.

Kesimpulan: Rawatan parut keloid dengan suntikan TAC dan urutan parut adalah efektif bagi populasi Malaysia.

Penambahbaikan ini ditunjukkan melalui penggunaan skala POSAS.

Kebimbangan berkaitan kosmetik mendahului tingkahlakumendapatkan rawatan, dan ciri-ciri parut tersebut berterusan sehingga ke penghujung rawatan.

Walaupun bagaimanapun, penilaian klinikal menunjukkan kecacatan kontur adalah factor yang lebih penting, dan bukan ketidak konsistensi warna. Secara keseluruhan, suntikan TAC dan urutan parut adalah kos efektif dan berkesan dalam penambahbaikan parut keloid di kalangan pesakit tempatan.

Kata Kunci: Keloid; Pelbagai modaliti; Triamcinolone acetonide; TAC;
Urutan parut; POSAS

KELOID: MULTICENTRE STUDY ON THE OUTCOME OF MULTIMODALITY MANAGEMENT

Abstract

Introduction: Keloids are benign hyperproliferative growths of dermal fibroblasts characterized by the excessive deposition of extracellular matrix components, especially collagen, fibronectin, elastin, proteoglycans, and growth factors such as TGF- β . They remain difficult to improve despite a plethora of advocated treatment strategies frequently observed in daily clinical routine. Hence, multimodality treatment is often recommended for optimum control of the disease. This study aims to assess the outcome of intralesional triamcinolone acetonide (TAC) injections with concurrent scar massage in management of keloid scarring in our setting, in order to optimise its management in the local population.

Methods: This is a prospective observational study conducted in the Reconstructive Sciences Unit, Hospital Universiti Sains Malaysia (Hospital USM) and the Department of Plastic & Reconstructive Surgery, Hospital Kuala Lumpur (HKL). This study involves the collection of POSAS scores from patients with keloid scars while they undergo treatment with intralesional TAC injections with concurrent scar massage. The POSAS scores is used to analyse the treatment outcome of keloid scars in the Malaysian population.

Results:The one-way repeated measures ANOVA was applied to assess the outcome of treatment. All patient and observer components of the POSAS showed improvements in keloid scars between the initial and conclusion visit. Patient components: pain (39.04%), itch (36.45%), thickness (30.40%), stiffness (23.62%), irregularity (20.50%), colour (10.18%) (NS), overall (20.50%) and total (26.74%). Observer components: vascularity (44.19%), relief (36.94%), thickness (34.67%), surface area (34.55%), pliability (34.22%), pigmentation (16.58), overall (34.63%) and total (33.93%). The overall and total patient scores showed significant improvements by mean differences of 1.43 ($p=0.016$) and 9.50($p<0.001$)respectively, while the overall and total observer scores showed significant improvements by mean differences of 2.00 ($p<0.001$) and 9.30 ($p<0.001$) respectively.

Conclusion:The treatment of keloid scars with intralesional TAC injections and concurrent scar massage is found to be effective in the Malaysian population. These improvements were demonstrated through the use of the POSAS. Cosmetic concerns appear to predominate the help-seeking behaviour of patients, with a persistence of these characteristics at the end of the study. Clinical assessment, however reveal contour deformity to be tenacious, rather than colour inconsistency. Nevertheless, in totality, the combination of intralesional TAC with scar massage is a cost effective yet clinically potent regime effective in improving keloid scars in the local setting.

Keywords: Keloid; Multimodality management; Triamcinolone acetonide; TAC; Scar massage; POSAS

1 Introduction

1.1 Background

1.1.1 Definition of Keloids

In 1806, French dermatologist, Jean Louis Alibert was the first to coin the term keloid from the Greek word “cheloides”, of which carries the meaning of “claw” to describe the leg-like projections of scars into the surrounding normal skin.

Keloids are benign hyperproliferative growths of dermal fibroblasts characterized by the excessive deposition of extracellular matrix components, especially collagen, fibronectin, elastin, proteoglycans, and growth factors such as TGF- β ⁽¹⁾. It is a variant of abnormal scarring resulting from abnormal wound healing after dermal injury, in which the healing process results in aberrant scar tissue formation.

While keloids have some tumor-like properties, they are actually inflammatory conditions that drive the excessive proliferation of dermal fibroblasts and the aberrant accumulation of dermal matrix⁽²⁾.

1.1.2 Aetiology

Its aetiology is unknown, but studies suggest that it results from the interaction of genetic and immunological factors with environmental triggers⁽³⁾. The risk of developing keloids is particularly high if the injury is

deep enough to damage the reticular layer of the dermis and if various genetic, systemic, and/or local risk factors that prolong the inflammatory stage of wound healing are present⁽²⁾.

1.1.2(a) Genetic and Immunology

The genetic basis of keloid pathogenesis has been studied extensively throughout the past decades. The observation that keloids occur more frequently in darker skinned individuals provided an initial suggestion of genetic predisposition towards its development⁽⁴⁾. Halim AS et al. presented a comprehensive summary on the genetic basis of keloid scarring⁽³⁾.

Evidence from Ethnic Groups

The distribution of keloid scarring in relation to ethnicity is well observed and documented. It was found to be the fifth most common skin disease in adult black patients in the United Kingdom, after acne, acne keloidalis nuchae/scalp folliculitis, eczema and psoriasis⁽⁵⁾. It was also found to be the most common in Chinese in comparison to other races in multiracial Malaysia⁽⁶⁾.

Evidence from Families and Twins

Both autosomal dominant⁽⁷⁾ and recessive⁽⁸⁾ modes of inheritance have been suggested in the literature. In 1969, Marneros and

coworkersexamined the pedigree of 14 families with familial keloids, over up to 4 generations, and concluded that the pattern of inheritance observed is consistent with an autosomal dominant mode with incomplete clinical penetrance and variable expression⁽⁷⁾. Marneros et al. later extended the study with gene scans, and provided the first evidence for keloid susceptibility loci on chromosomes 2 (2q23) and 7 (7p11)⁽⁹⁾. In addition, the high frequency of identicaltwins both developing keloids also strongly supports a role ofgenetics in keloid etiology⁽⁸⁾.

Evidence from Syndromes with Keloid Scarring

Individuals with certain rare syndromes have been found to have higher propensity to develop keloids. These include Rubinstein–Taybi syndrome, Goeminne syndrome, Ehler–Danlos syndrome, Dubois syndrome, Pachydermoperiostosis, Progeria and Osteopoikilosis⁽¹⁰⁾.In contrary, the absence of reported cases of keloids in certain subsets of individuals, as in individuals with albinism, reinforces the genetic background of the condition.

1.1.2(b)Environmental Triggers

Systemic factors

Endocrine Dysfunction

Endocrine dysfunction is associated with the keloid disease. Various hormones have been described, in particular the sex hormones oestrogen and androgens. Other hormones postulated to be associated with keloids include the melanocyte stimulating hormone (MSH) and growth hormone (thyrotropin).

The onset or worsening of keloid scars during adolescence and pregnancy, as well as its regression in the post-menopausal period provided early suggestions that alterations in hormonal status may be associated with keloids. Cases discussing on the increased keloidal tendencies accompanying pregnancy has been reported in the literature (11, 12). As oestrogen is known to exert its influence on all phases of wound healing (13), it may have a role in keloid scarring.

States of hyperpituitarism may explain the mechanism whereby aberrations in the hypothalamic-pituitary-glandular axis results in increased propensity to develop keloids. MSH metabolism abnormalities, hyperthyroidism, acromegaly or even pregnancy has been linked to keloid formation based on this observation.

Hypertension

In their publication in 2014, Huang and Ogawa explored the link between hypertension and the development of pathological scars, and found that hypertension is associated with the development of severe keloids⁽¹⁴⁾. The development of keloids was proposed to be the result of excessive wound healing characterized by a prolonged and stronger inflammatory phase due to inappropriately released cytokines, namely TGF- β and TNF- α in hypertension⁽¹⁵⁾.

Local Factors

Mechanical Forces

Mechanical forces exerted on cutaneous wounds contribute to the generation of keloids⁽¹⁶⁾. Clinically, this is evidenced by the site-specific incidence and shape of keloids in accordance to the region-specific distribution of skin tension⁽¹⁶⁾. Not only does this explain the usual site distribution of keloids (shoulder, arm and anterior chest), but also its corresponding shapes (butterfly, dumbbell and crab claw).

Trauma, Infection, Foreign Body

Recurrent local trauma, infection and presence of foreign bodies are also known to trigger inflammation and downstream fibroproliferative events⁽¹⁷⁾. This may explain the occurrence of keloids at the earlobes:

mechanical forces from heavy earrings, repeated injury from attaching/detaching earrings, recurrent infections from handling.

1.1.3 Pathomechanisms

1.1.3(a) Normal Wound Healing

The American Wound Society defines a wound as a disruption in anatomical structure and function. Therefore, wound healing is the response mounted by an organism in order to limit the disruption, restore the integrity and stabilize the physiology of the entire organism. It is a highly coordinated process consisting of overlapping phases which proceeds in a timely manner⁽¹⁸⁾ (Figure 1.1). Howes, Sooy and Hawey (1929) temporally grouped wound healing into 3 distinct phases; inflammation, proliferation and remodelling. Scarring is the final outcome of cutaneous wound healing.

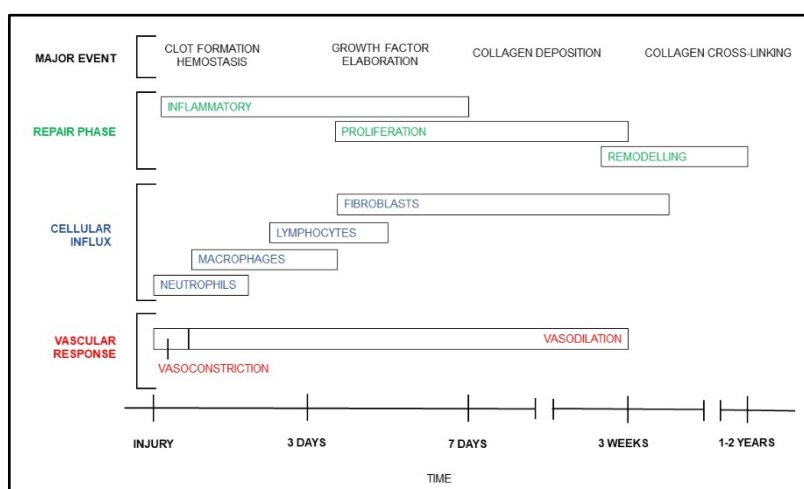


Figure 1.1: The temporal patterns of repair phase, cellular influx, and vascular response during wound repair events

Inflammation

Immediately following wounding, TXs, PGs and serotonin released by damaged cells cause transient vasoconstriction lasting 5 – 10 minutes. The exposure of collagen and subendothelium to the blood stream triggers platelet aggregation and activation of the coagulation and complement cascades. This results in the formation of a platelet plug. Subsequent platelet degranulation leads to the formation of a stable clot, which consists of a provisional fibrin matrix with embedded platelets. Platelet degranulation leads to the release of potent cytokines such as PDGF, vWF, IGF1, EGF and TGF- β . These factors serve as chemotactic agents which recruits neutrophils, macrophages, epithelial cells, mast cells, endothelial cells and fibroblasts into the wound.

The inflammation phase, which follows hemostasis, is characterized by spatial and temporal changing patterns of leukocyte subsets, proceeding from neutrophils to macrophages to lymphocytes. Serotonin, NO, histamine, PGI₁, PGE₁, LTC₄/D₄ and bradykinins causes vasodilation and increased permeability of local vasculature. Neutrophils, the first cell population to arrive at the site of injury, moves from the intravascular space into tissues via margination and diapedesis. They not only scavenge the wound bed of cellular debris, bacteria and foreign bodies, but also secrete inflammatory products (NO, H₂O₂, oxygen free radicals) and initiate the first stages of the proliferative phase by elaboration of IL1 and TNF- α . IL1 and TNF- α is involved in the activation of fibroblasts and epithelial cells.

Within 48 – 96 hours, circulating monocytes becomes macrophages upon crossing the vessel walls. In addition to phagocytosis of cell debris and apoptotic neutrophils, macrophages are involved in the orchestration of a wide range of growth factors necessary for the healing process to move into the proliferative phase. These growth factors attract and stimulate local endothelial cells, fibroblasts and keratinocytes to begin the repair function, matrix deposition, neovascularization and angiogenesis. Factors elaborated influences the chemotaxis and proliferation of fibroblasts and keratinocytes (PDGF, TGF- β , TNF- α , IL1, KGF7), angiogenesis (VEGF, FGF2, PDGF), and deposition of ECM (PDGF, TGF- β , TNF- α , OPN, IL1, collagenases, MMPs). The role of macrophages is considered critical to wound healing, as their depletion is shown to result in poor debridement, delayed fibroblast proliferation and inadequate angiogenesis⁽¹⁸⁾.

Lymphocytes are seen within wounds beginning day 5 – 7. They can be divided into B and T lymphocytes, based on their respective sites of development in the thymus and bone marrow. Apart from modulating immune responses, T lymphocytes are proposed to be involved in the process of wound healing via regulation of collagenases and ECM remodelling. These cells can be subdivided into 4 major subsets with specific functions; helper, cytotoxic, memory and regulatory T cells. Of these, the T helper cells (Th cells), also known as CD4+ cells, have been implicated in fibrogenesis.

Proliferation

The process then transitions into the proliferative phase, lasting for up to 2 – 4 weeks. This phase begins with the degradation of the fibrin-platelet provisional matrix, effected by 3 major classes of proteases: serine proteases, cysteine proteases, MMPs). The MMPs are endopeptidases (collagenase, gelatinase, stomelysin), and are responsible for degrading matrix proteins and activating growth factors. The functions of the proliferative phase can be divided into 4 major processes: fibroplasia, granulation, contraction, epithelialization.

Fibroblasts from perivascular tissue migrate along fibrin networks into wound. They undergo hypertrophy (by increasing protein synthesis needed for cell division) and hyperplasia (proliferation). Fibroblasts takes over macrophages to become the predominant cell type at day 3 to day 5 in clean wounds. Fibroblasts secretes hyaluronidases to digest the provisional extracellular matrix of hyaluron and fibronectin. Larger sulphated GAGs (chondroitin-4-sulphate, dermatan sulphate, heparin sulphate) are then secreted, along with the deposition of collagen and elastin in a disorganized manner. Major fibrillary collagens in the ECM are type I and III in the ratio of 4:1.

The hallmark of granulation tissue formation is angiogenesis. Tissue hypoxia, thrombus, platelets and VEGF secreted by activated macrophages and fibroblasts serve as stimulus for angiogenesis. VEGF causes the proliferation of endothelial cells. Endothelial cells secrete

zinc-dependent MMPs to degrade the ECM to make way for cell migration, while their leading tips express Integrin $\alpha V\beta 3$ which causes directional endothelial cell migration. This process eventually results in the formation of a dense population of blood vessels.

Wound contraction is effected by myofibroblasts, specialized fibroblasts with contractile cytoplasmic microfilaments (filamentous actin) and distinct cellular adhesion structures (desmosomes, maculae adherens). They are present throughout the granulating wound, and contract in concert to result in a centripetal force which pulls the wound edges circumferentially. In response to KGF, keratinocytes re-establishes the epithelial layers. They undergo mobilization by losing contact inhibition at the wound edges, followed by migration via leapfrogging, guided by 'railroad tracts' of tenascin and fibronectins. Upon completion of wound bridging, they regain contact inhibition and differentiate into the layers of the epidermis.

Remodelling

The final phase, remodelling, begin at 2 – 4 weeks after wounding, and may last up to 1 – 2 years. This phase aims to replace granulation tissue with the stronger avascular scar tissue. As the equilibrium between collagen synthesis and degradation is reached, no net change in the quantity of collagen is observed. Instead, the existing collagen fibres remodel from type III to type I, and undergo cross-linking to improve tensile strength. Collagen is degraded by MMP 1, 2, 3, 9, and deposited

by TIMP. Cutaneous wound healing eventually results in wound strength of 3% at 1 week, 30% at 3 weeks, and 80% at 3 months as compared to that of uninjured skin.

1.1.3(b) Pathological Wound Healing in Keloid Scarring

As scar formation is the ultimatum of the wound healing process, any abnormality in any of its phases may result in pathological scarring.

Inflammation

After wounding, the internal milieu is exposed to a variety of agents that are capable of prolonging or exaggerating this phase. These include microorganisms and foreign bodies, which are usually promptly eliminated by neutrophils and macrophages during inflammation.

It has been found that both the severity, as well as type of immune response can result in HTS and keloids. Of particular mention is the roles of Th cells in fibrogenesis. The characteristic cytokine expression profile of Th cells represents the basis for describing either a predominantly Th1 or Th2 response to a specific or unspecific stimulus ⁽¹⁹⁾. A Th2 response (with production of interleukin IL-4, IL-5, IL-10 and IL-13) has been strongly linked to fibrogenesis, while a predominance of Th1 cells has been shown to almost completely attenuate the formation of tissue fibrosis via production of IFN- γ and IL-12 ^(20, 21).

Nevertheless, the elaboration of these mediators are essential for subsequent processes, such as angiogenesis, fibroplasia and ECM deposition.

Proliferation

Failure to improve fibroproliferative diseases, not only that of skin but also those involving internal organs with anti-inflammatory therapy provide the basis that inflammation is not the critical step in the development of the fibrotic response. Abnormalities in fibroblasts, TGF- β and the SMAD pathway, mast cells and the interactions between keratinocytes and fibroblasts have been implicated.

Alterations in the fibroblast phenotype is seen in keloids. As compared to normal fibroblasts, keloid fibroblasts exhibit higher numbers of growth factor receptors and greater response to growth factors like PDGF, TGF- β , IGF and IL-1, which results in upregulation of their functions.

TGF- β 1, - β 2 and - β 3 are the principal isoforms of TGF- β found in mammals. TGF- β 1 and - β 2 stimulates ECM deposition, while TGF- β 3 inhibits it. Over-expression of TGF- β 1 and - β 2 and under-expression of TGF- β 3 have been found in keloids and keloid-derived fibroblasts. The SMAD pathway is the downstream signal transduction pathway for TGF- β action⁽²⁵⁾ (Figure 1.2).

SMAD intracellular signaling proteins can be categorized into receptor-regulated SMADs (R-SMADs), common-mediator SMADs (co-SMADs), and inhibitory SMADs⁽²²⁾. The pathway begins by the binding of TGF- β to

its cell surface receptor. This results in phosphorylation and activation of the type I receptor. The activated type I receptor then phosphorylates and activates the R-SMADs (SMAD 2, 3 and 4). These R-SMADS is then able to form complexes with the common mediator Co-SMAD SMAD 4. The complex of R-SMADs and Co-SMAD then translocates to the nucleus. The end point of the activation of this pathway is the activation of target genes in the nucleus, mediating their expression via the biological effects of TGF- β . SMAD 7 has inhibitory actions on the pathway via prevention of phosphorylation of R-SMADs. Hence, manipulation of this pathway, specifically by downregulating SMAD 2, 3 and 4, and/ or upregulating SMAD 7 may be potential targets in the management of pathological scarring.

Keratinocytes have been found to influence the activity of fibroblasts. With its secretion of KGF, and its interaction with fibroblasts to form the basement membrane via deposition of laminin and type IV collagen, keratinocytes have an intimate collaboration with fibroblast in the process of epithelialization. Co-culturing of keratinocytes with keloid-derived fibroblasts have been shown to result in greater neodermis thickness⁽²³⁾. The role of keratinocytes in pathological scarring requires further study.

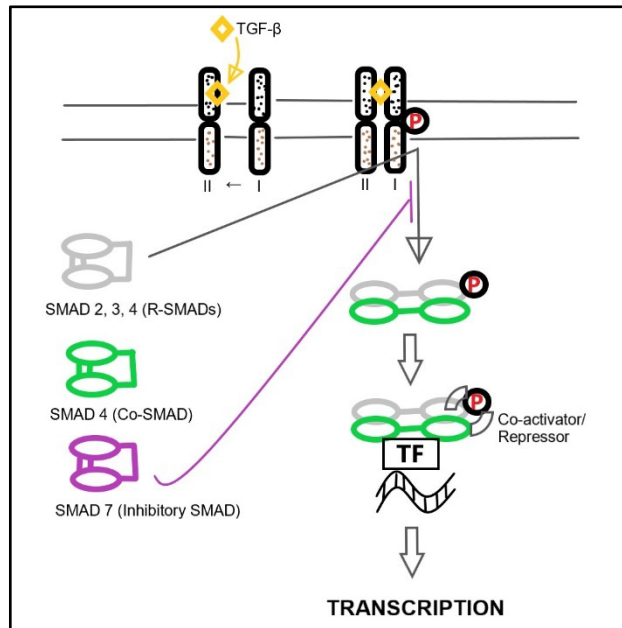


Figure1.2: The SMAD signal-transduction pathway as a downstream mediator of TGF-β action

Increased numbers of mast cells are seen in active keloids. Their secretion of proinflammatory mediators such as histamine, heparin and cytokines are responsible for the symptoms of pruritus and erythema commonly experienced by patients with keloids. These mediators, however, have also been found to promote fibroblast proliferation.

Remodelling

A delicate balance of ECM degradation by MMPs and its deposition by TIMPs is maintained throughout the normal remodelling process. MMP-2 has been found to degrade collagen type III, while MMP-9 degrades collagen type I, resulting in the final outcome of collagen type I to type III of 4:1 in normal scar tissue. In keloids, high levels of MMP-2 and low levels of MMP-9 can result in the ratio to be as high as 17:1.

Decorin, a small proteoglycan with one dermatan sulfate sugar chain, is found in normal dermal ECM. It binds and neutralizes the action of TGF- β . Lower levels than normal has been found in keloids. This suggests that decorin may have a role as an antifibrotic agent in keloids⁽²⁴⁾. In addition, delayed apoptosis of myofibroblasts and a continuing high-turnover state similar to the proliferative phase is also proposed in the pathogenesis of keloids.

1.1.4 Clinical Features

Keloids not only result in bothersome physical symptoms, but is also associated with significant psychosocial impact.

Typical complaints include a painful, red, pruritic and often unsightly 'growing' scar, of which extends onto normal skin beyond the borders of the initial injury. Physical examination usually shows a thick warm lesion with erythematous edges encroaching onto normal skin. They often have site-specific shapes, namely, the typical butterfly, crab's claw, and dumbbell shapes on the shoulder, anterior chest, and upper arm, respectively⁽¹⁷⁾. In relation to its size, keloids can be further subdivided into minor (focally raised) and major (>0.5cm in thickness) keloids⁽²⁵⁾.

Scar tissue projecting beyond the original wound margins is the cardinal distinguishing feature of keloids from HTS. In addition, they tend to appear years after cutaneous insult, is persistent, does not regress spontaneously and exhibit high recurrence rates after excision⁽²⁶⁾.

1.1.5 Management Options for Keloid

Keloid scarring remains difficult to improve despite a plethora of advocated treatment strategies as frequently observed in daily clinical routine ⁽²⁷⁾. Various modes of treatment ranging from non-invasive strategies to surgical intervention have been proposed and utilized over the past decades. The outcome of usage of these modalities as monotherapy or in combination, and in consecutive or concurrent fashion has been studied. Multimodality treatment is often recommended for optimum control of the disease.

These modalities can be grouped into conservative, non-surgical and surgical therapies. Conservative approaches include silicone gel sheeting, silicone tapping, pressure therapy (scar massage, pressure garment), as well as make-up/ camouflage therapy. Non-surgical modalities include topical applications (silicone gel, onion extract, imiquimod 5% cream), and injectibles (intralesional TAC, intralesional cryotherapy, 5-fluorouracil, interferon, recombinant TGF β). Finally, surgery may be opted to either radically excise the lesion, or merely for mass reduction.

1.1.6 Management in our Setting

In our setting, patients who are diagnosed with keloid scarring are commenced on intralesionally instituted TAC, in combination with advice for scar massage. TAC with the concentration of 10mg/ml are given every

4 – 6 weeks. This combined therapy is both clinically potent and cost effective.

1.1.7 Intralesional Triamcinolone Acetonide (TAC) Injection

TAC is a synthetic corticosteroid. One of the earliest uses of triamcinolone acetonide for the treatment of keloids was reported in 1965 - 9-year-old girl with keloid scarring secondary to burn injury ⁽²⁸⁾. TAC is central in the management of keloid. Its use as a monotherapy in fixed, escalating or tapering doses, or in combination with other modalities has been widely studied⁽²⁹⁾(Figure 1.3).

The TAC used in our centre is of concentration 10 mg/ml, preserved in benzyl alcohol, and is available in 5ml sterile glass vials⁽³⁰⁾ (Figure 1.4). The solution is administered using 1cc syringes with 27 gauge needles for a more precise control of infiltration. In general, the solution is infiltrated intralesionally until blanching of the keloid scar is observed.

Study	Type of scar	Combination Therapy	Corticosteroid dosage	Interval	Result	Side effect
Park et al. (2013)	Keloids	Surgical excision + full thickness skin graft + postoperative TAC	NA	4 injections at monthly intervals postoperatively	- 78.5%: successful treatment - 21.5%: recurrence	- Recurrence - Slight marginal elevation & redness
Martin et al. (2013)	Keloids	CO2 fractional laser (10,600 nm), pulsed dye laser (585 nm), TAC	TAC 40 mg/ml 0.5 ml + 0.4 ml lidocaine with epinephrine	7 injections at monthly intervals	- Minimal flatness - Minimal effect on size - Diminished pruritus - Lighter pigmentation	NA
Camacho-Martinez et al. (2013)	Keloids and hypertrophic scars	Bleomycin + TAC	TAC 40 mg/ml 4–5 mg/cm ² (0.10–0.125 ml in a syringe of 0.5 ml)	3 monthly	- Flattening - Scar height reduction - Softening	- Erythema - Telangiectasias - Atrophy - Ulceration - Recurrence
Son et al. (2014)	Keloids and hypertrophic scars	578 nm copper bromide Laser + TAC	TAC 10 mg/ml	4 weekly combined treatment	- Reduced vascular components of scars - Decreased erythema - Improved pruritus - Improve telangiectasia 8%: ≤25% improvement 17%: 25 - 50% improvement 33%: 51 - 75% improvement 42%: ≥75% improvement	- Moderate pain during treatment - Transient erythema & edema - Mild hyperpigmentation
Emad et al. (2010)	Keloids	Surgical excision + immediate postoperative radiotherapy vs. Cryotherapy + TAC	TAC 10 mg/ml (maximum 40 mg/ session)	Every 20 days	- 66.7%: satisfied - 22.2%: partially satisfied - 11.1%: unsatisfied	- Hypopigmentation (9.4%) - Ulceration + necrosis (31.2%) - Telangiectasia (18.8%)
Sadeghinia et al. (2011)	Keloids	5-fluorouracil Tattooing + TAC	TAC 40 mg/ml (20 mg (0.5 ml)/ cm ² lesion)	4 weekly for 12 weeks	- Reduced erythema & pruritus - Reduced surface & height	NA
Al Aradi et al. (2013)	Keloids	Keloidectomy with core fillet flap + TAC	TAC 40 mg/ml (0.25 ml)	Monthly	- Efficacy: 87.6% - Immediate recurrence: 9.5% - Subjectively, 82.3% patients were highly satisfied	- Full-flap necrosis - Abscess-like nodule - Neuroma
Anthony et al. (2010)	Keloids	TAC	- Non-bearded area of face (mean dose 8.75 mg) - Bearded area, upper limb, earlobes, occipital, sternum (mean dose 20.37 mg) - Regimen 1: 10 mg/ml - Regimen 2: 40 mg/ml - Regimen 3: 10 then 40 mg/ml - Regimen 4: 10 then 40 then 10 mg/ml - Regimen 5: 40 then 10 mg/ml	4 weekly	Regimen 3 was the most effective, with the lowest recurrence rate (10%)	Recurrence: - Regimen 1: 22% - Regimen 2: 25% - Regimen 3: 10% - Regimen 4: 24% - Regimen 5: 50%
Niessen et al. (1999)	Keloids and hypertrophic scars	TAC (review)	TAC 10–40 mg/ml	Monthly	Decreased recurrence rates, collagen and glycosaminoglycan synthesis, inflammatory processes & fibroblast proliferation	- Atrophy - Ulceration - Necrosis - Telangiectasia - Depigmentation - Cushingoid features - Hypopigmentation
Davison et al. (2011)	Keloids	5-fluorouracil + TAC	TAC 0.1 ml of solution/cm lesion	4 weekly	- 92% average reduction in lesion size - Reduction of pruritus - Pain resolved	Telangiectasias
Gupta et al. (2011)	Keloids and hypertrophic scars	5-fluorouracil + TAC	Generally TAC 10–20 mg/ml, 40 mg/ml for tough bulky lesions	3 – 4 weekly	- Reduced volume of lesions	Irreversible atrophy

Figure 1.3: Review of the evidence and current developments in corticosteroid intralesional injection treatments

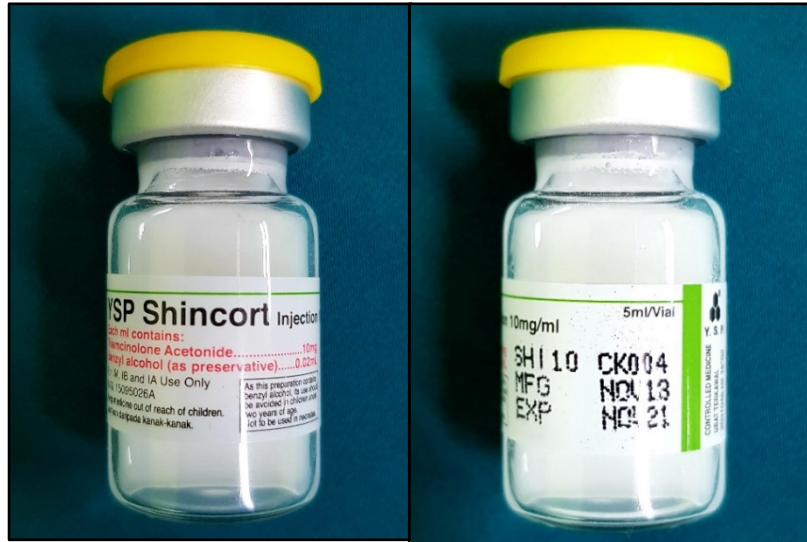


Figure 1.4:TAC in 10mg/ml preparation (Shincort by Y.S.P. Industries)

The intralesional administration of TAC is known to decrease inflammation, increase vasoconstriction and inhibit fibroblast proliferation in a dose-dependent fashion ⁽³¹⁾. Via the inhibition of fibroblast proliferation and collagenase inhibitors, collagen and glycosaminoglycan synthesis is reduced⁽³²⁾. On top of that, it also decreases the production of inflammatory cytokines, chemokines, and lysosomal enzymes⁽³³⁾. More recently, TAC has been found to inhibit vascular endothelial growth factor (VEGF) and TGF- β 1 expression and to induce apoptosis in fibroblasts ^(34, 35).

When used as monotherapy, steroid injections have a highly variable response rate of 50% to 100% and a recurrence rate of 9% to 50%⁽³²⁾. In general, existing studies on the applications of intralesional triamcinolone acetonide for keloid scars not only resulted in a reduction in extension and thickness of the keloid scar, but also an improvement in clinical symptoms of pruritus, pain, and hyperemia⁽³⁶⁾.

1.1.8 Scar Massage

The exact mechanism of massage in improving keloids remains unknown. Several studies suggest that scar massage can alter ECM remodelling and influence fibroblast apoptosis. It is proposed that the mechanical forces of scar massage can alter the structural and signalling milieu within scars via induction of changes in the expression of ECM proteins and proteases, on top of increasing scar pliability by disrupting fibrotic tissue⁽³⁷⁾. Furthermore, in vitro studies on human scar tissue showed that pressure can induce apoptosis and reduce TNF- α levels⁽³⁸⁾.

Besides being cheaper, scar massage allows patients to be more involved in their treatment and aids in the resolution of swelling and induration of scars⁽³⁷⁾. However, it can also cause irritation from friction and contact dermatitis from the lubricant used, in addition to be a waste of patient's time if it is not an efficacious treatment⁽³⁷⁾.

Shin et al. recommends friction massage with the application of sufficient pressure to blanch the scar for 10 minutes twice a day, titrated up or down as tolerated⁽³⁷⁾. This therapy is not suitable in open wounds, acute infections and bleeding. Massage is best performed with clean hands and hypoallergenic emollients.

1.1.9 Algorithm for Management of Keloids

In addition to the vast degree to which keloids respond to various treatment modalities, numerous variables found to influence the outcome of treatment makes its management even more challenging. These

include ethnicity, age, gender, site and size of keloids, and the methods used to measure response rates and patient satisfaction. In view of this high variability of response rates, earlier algorithms suggest less invasive modalities such as silicone sheeting or TAC for a duration of 3-12 months, before opting for more invasive modalities such as surgery⁽²⁵⁾.

In 2010, Ogawa proposed an algorithm for the management of keloids after extensive evidence-based review of relevant literature⁽³⁹⁾(Figure 1.5). The algorithm suggests to stratify patients according to size and number of lesions present. Small and/or single lesions can either be treated with excision and adjuvant therapy, or with non-surgical monotherapy. On the other hand, goals of treatment should first be set in patients with large and/or multiple lesions, or those with lesions limiting range of motion. These latter group of patients may either opt for mass reduction surgery or symptomatic management with non-surgical multimodality therapy. Long-term follow-up is recommended for all patients with keloids.

All patients recruited for assessment in this study presented with small single lesions. Therefore, in accordance with the treatment algorithm for keloids suggested by Ogawa, patients were started on non-surgical monotherapy with intralesional TAC. The monotherapy was supplemented with scar massage, one of the most cost effective mode of conservative therapy.

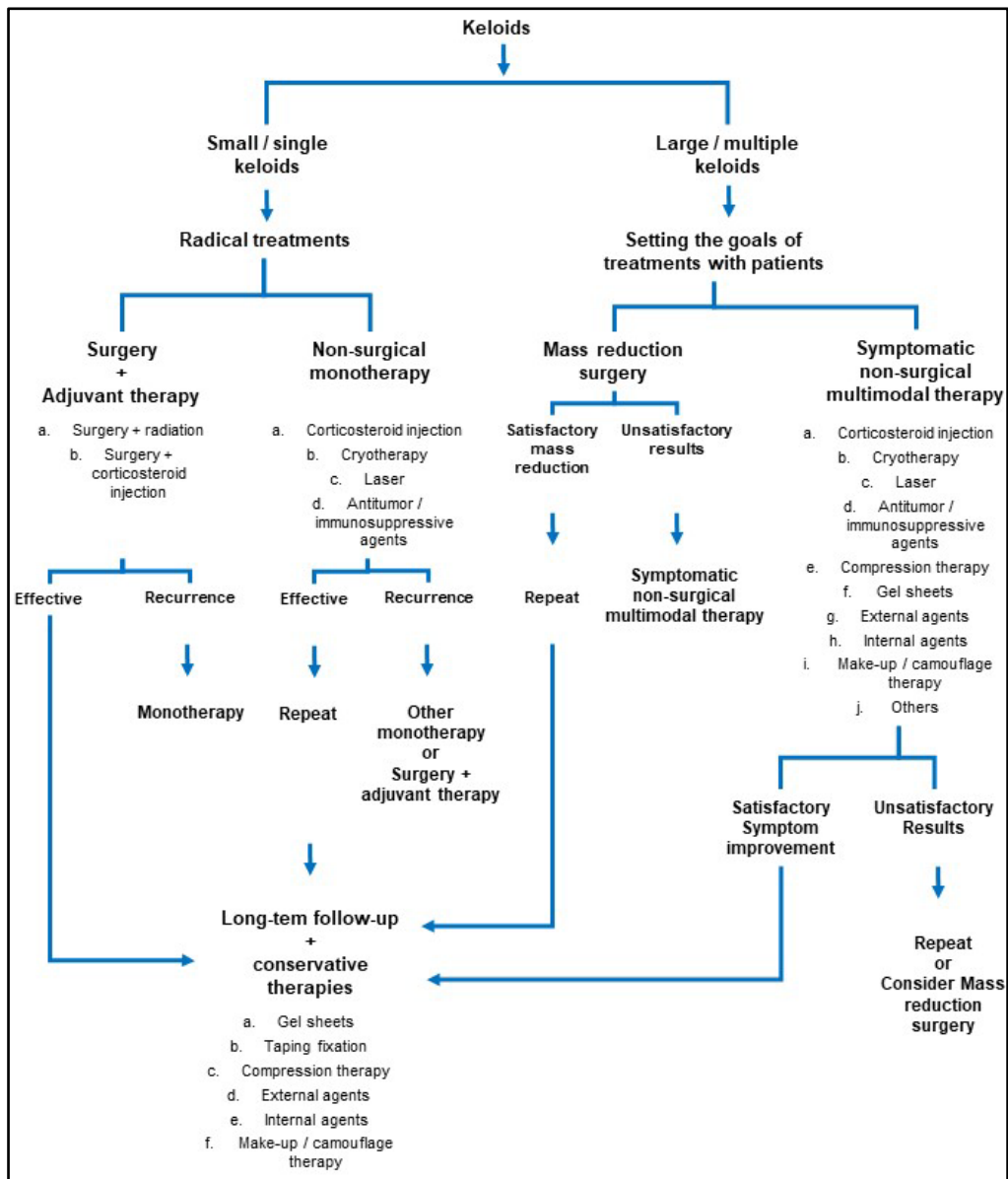


Figure 1.5: Treatment Algorithms for Keloids

1.1.10 Patient Observer Scar Assessment Scale (POSAS)

The POSAS is a scoring system for subjective scar assessment which focuses on scar severity from both the clinician's and patient's point of view. It was first published by Draaijers et al. in 2004 (Version 1.0). A year later, Van Der Kar et al. published POSAS version 2.0 (POSAS

v2.0). Further development and refinement of the scale is still underway. The POSAS v2.0 is the version utilized in this study.

The scoring system consists of 2 numerical scales – the patient (Figure 1.6) and the observer (Figure 1.7) scales v2.0⁽⁴⁰⁾. Although the scale was initially developed with a focus on burn scars, it has been applied in assessing various types of scars, including linear surgical scars. Its uses include evaluation of response to treatment, evaluation of new therapies, and as a tool for communication between clinicians ⁽⁴¹⁾.

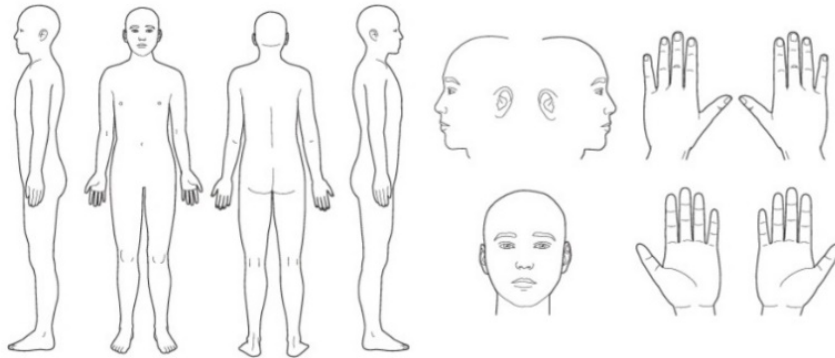
Each of the 2 scales consists of 6 items that are scored numerically on a ten-step scale. The score of 10 corresponds to the worst imaginable scar. Each of these items carry a minimum score of 1 and a maximum score of 10. The sum of scores from both of the scales make up the 'Total Score' of the POSAS, with a minimum total score of 6, and the maximum total score of 60. In addition, the patient and the observer each also score their 'Overall Opinion' on a ten-step scale. During scoring, all parameters are compared to the normal skin at a comparable anatomical site whenever possible.

POSAS Patient scale

The Patient and Observer Scar Assessment Scale v2.0 / EN

Date of examination: _____
 Observer: _____
 Location: _____
 Research / study: _____

Name of patient: _____
 Date of birth: _____
 Identification number: _____



	1 = no, not at all	yes, very much = 10
	<input type="radio"/> 1 <input type="radio"/> 2 <input type="radio"/> 3 <input type="radio"/> 4 <input type="radio"/> 5 <input type="radio"/> 6 <input type="radio"/> 7 <input type="radio"/> 8 <input type="radio"/> 9 <input type="radio"/> 10	
HAS THE SCAR BEEN PAINFUL THE PAST FEW WEEKS?	<input type="radio"/> <input type="radio"/> <input type="radio"/> <input type="radio"/> <input type="radio"/> <input type="radio"/> <input type="radio"/> <input type="radio"/> <input type="radio"/> <input type="radio"/> <input type="radio"/>	
HAS THE SCAR BEEN ITCHING THE PAST FEW WEEKS?	<input type="radio"/> <input type="radio"/> <input type="radio"/> <input type="radio"/> <input type="radio"/> <input type="radio"/> <input type="radio"/> <input type="radio"/> <input type="radio"/> <input type="radio"/> <input type="radio"/>	
	1 = no, as normal skin	yes, very different = 10
IS THE SCAR COLOR DIFFERENT FROM THE COLOR OF YOUR NORMAL SKIN AT PRESENT?	<input type="radio"/> <input type="radio"/> <input type="radio"/> <input type="radio"/> <input type="radio"/> <input type="radio"/> <input type="radio"/> <input type="radio"/> <input type="radio"/> <input type="radio"/> <input type="radio"/>	
IS THE STIFFNESS OF THE SCAR DIFFERENT FROM YOUR NORMAL SKIN AT PRESENT?	<input type="radio"/> <input type="radio"/> <input type="radio"/> <input type="radio"/> <input type="radio"/> <input type="radio"/> <input type="radio"/> <input type="radio"/> <input type="radio"/> <input type="radio"/> <input type="radio"/>	
IS THE THICKNESS OF THE SCAR DIFFERENT FROM YOUR NORMAL SKIN AT PRESENT?	<input type="radio"/> <input type="radio"/> <input type="radio"/> <input type="radio"/> <input type="radio"/> <input type="radio"/> <input type="radio"/> <input type="radio"/> <input type="radio"/> <input type="radio"/> <input type="radio"/>	
IS THE SCAR MORE IRREGULAR THAN YOUR NORMAL SKIN AT PRESENT?	<input type="radio"/> <input type="radio"/> <input type="radio"/> <input type="radio"/> <input type="radio"/> <input type="radio"/> <input type="radio"/> <input type="radio"/> <input type="radio"/> <input type="radio"/> <input type="radio"/>	
	1 = as normal skin	very different = 10
WHAT IS YOUR OVERALL OPINION OF THE SCAR COMPARED TO NORMAL SKIN?	<input type="radio"/> <input type="radio"/> <input type="radio"/> <input type="radio"/> <input type="radio"/> <input type="radio"/> <input type="radio"/> <input type="radio"/> <input type="radio"/> <input type="radio"/> <input type="radio"/>	

COPYRIGHT © P.J.M. VAN ZUIJLEN, BEVERWIJK.NL

Figure 1.6: POSAS Patient Scale v2.0