



Final Examination
2017/2018 Academic Session

May/June 2018

JIB325 – Histology and Anatomy
[Histologi dan Anatomi]

Duration : 3 hours
[Masa : 3 jam]

Please ensure that this examination paper contains **FOUR** printed pages before you proceed.

Answer **FIVE (5)** questions in the answer booklet provided.

Mark for each sub question is given at the end of that sub question.

You may answer **either** in Bahasa Malaysia or English.

In the event of any discrepancies in the exam questions, the English version shall be used.

*Sila pastikan bahawa kertas peperiksaan ini mengandungi **EMPAT** muka surat yang bercetak sebelum anda memulakan peperiksaan ini.*

*Jawab **LIMA (5)** soalan dalam buku jawapan yang disediakan.*

Markah untuk setiap subsoalan diperlihatkan di penghujung subsoalan tersebut.

*Anda dibenarkan menjawab soalan **sama ada** dalam Bahasa Malaysia atau Bahasa Inggeris.*

Sekiranya terdapat sebarang percanggahan pada soalan peperiksaan, versi Bahasa Inggeris hendaklah diguna pakai.

...2/-

Answer **FIVE (5)** questions.
Jawab LIMA (5) soalan.

1. (a). Draw, label and describe the histology of transitional and pseudostratified epithelium.

Lukis, label dan huraikan histologi epitelium peralihan dan pseudoberlapis.

(10 marks/markah)

- (b). Define

- (i). osteoblast
- (ii). osteocytes
- (iii). oligodendrocyte
- (iv). chondrocytes
- (v). astrocyte

Takrifkan

- (i). osteoblast
- (ii). osteosit
- (iii). oligodendrosit
- (iv). kondrosit
- (v). astrosit

(10 marks/markah)

2. (a). With the aid of a diagram, draw and label components of connective tissue.

Dengan bantuan gambar rajah, lukis dan label komponen tisu perantara.

(10 marks/markah)

- (b). Draw and discuss **THREE (3)** types of cartilage.

Lukis dan bincangkan TIGA (3) jenis rawan.

(10 marks/markah)

...3/-

3. (a). List and describe the **FIVE (5)** keratinocyte layers of the skin.
*Senarai dan huraikan **LIMA (5)** lapisan keratinosit pada kulit.*
(10 marks/markah)

- (b). Discuss the histology of
(i). small intestine
(ii). adrenal glands

Bincangkan histologi

- (i). *usus kecil*
(ii). *kelenjar adrenal*

(10 marks/markah)

4. Discuss the histology of nephron.
Bincangkan histologi nefron.

(20 marks/markah)

5. (a). Referring to Figure A, name the components of the non-crocodalian reptile heart.

Merujuk kepada Rajah A, namakan komponen jantung reptilia bukan-buaya.

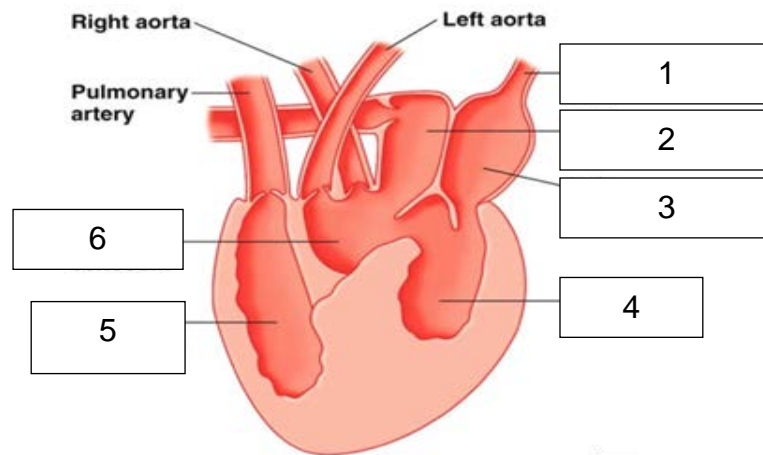


Figure A
Rajah A

(3 marks/markah)

- (b). Draw, label and explained the histological structure of the heart muscle.

Lukis, label dan jelaskan struktur histologi otot jantung.

(7 marks/markah)

- (c). Write short notes on the anatomy structure of a bird's lung.

Tulis nota ringkas struktur anatomi paru-paru burung.

(10 marks/markah)

6. Draw and label the gastro intestinal tract of shark, turtle, chicken and ruminant.

Lukis dan label trek gastrousus yu, penyu, ayam dan ruminan.

(20 marks/markah)