

**CONE-BEAM COMPUTED TOMOGRAPHY STUDY
OF ROOT AND ROOT CANAL MORPHOLOGY
USING NEW CLASSIFICATION IN THREE
ETHNIC GROUPS IN KELANTAN, MALAYSIA**

MOHMED ISAQALI KAROBARI

UNIVERSITI SAINS MALAYSIA

2020

**CONE-BEAM COMPUTED TOMOGRAPHY STUDY
OF ROOT AND ROOT CANAL MORPHOLOGY
USING NEW CLASSIFICATION IN THREE
ETHNIC GROUPS IN KELANTAN, MALAYSIA**

by

MOHMED ISAQALI KAROBARI

**Thesis submitted in the fulfilment of the requirement
for the degree of
Master of Science**

April 2020

ACKNOWLEDGEMENT

In the name of Allah, the most beneficent and most merciful all praise be to Allah the Almighty and heartily thanks to Rasool Ullah (SWT), for giving me the blessings, the strength, the chance and endurance to complete my research work.

I would like to express my sincere gratitude to my supervisor Dr. Tahir Yusuf Noorani for his expert guidance and support throughout my study. The door of his office was always open whenever I ran into a trouble spot or had a question about my research work or writing. He not only made sure that I complete my work with perfection and on time, but also steered me in the right direction whenever he thought I needed it. Furthermore, my appreciation also goes to my co-supervisors, Dr. Mohamad Syahrizal Bin Halim and Dr. Hany Mohamed Aly Ahmed for their insightful encouragement, support and knowledge regarding this study. Without their passionate participation and input, this study could not have been successful. Financial support from Universiti Sains Malaysia (short term grant no. 304/PPSG/6315195) is also highly acknowledged.

Sincere thanks to all my dear friends for their kindness and moral support during my study. Thanks for the friendship and memories. My acknowledgement also goes to all the technicians and office staffs of School of Dental Sciences, Universiti Sains Malaysia.

Last, but not least, my deepest gratitude goes to my beloved Father; Mr. Mohammed Khasim Ali Karobari, brothers, sister and my darling wife Dr Ayesha Parveen & kids Hamza & Hussain for their endless love, prayers and encouragement. Also not forgetting my in laws Mrs.& Mr. Mohammed Abdul Khadeer for their support, love and care. To those who indirectly contributed in this research. Thank you very much.

TABLE OF CONTENTS

ACKNOWLEDGEMENT	ii
TABLE OF CONTENTS	iii
LIST OF APPENDICES.....	viii
LIST OF TABLES.....	ix
LIST OF FIGURES.....	xi
ABSTRAK.....	xiv
ABSTRACT.....	xvi
CHAPTER 1:INTRODUCTION.....	1
1.1 Background of the study	1
1.2 Problem Statement	3
1.3 Justification of the Study.....	4
1.4 Research Questions	5
1.5 Research Hypotheses	6
1.5.1 Null hypotheses.....	6
1.6 Objectives of the study.....	8
1.6.1 General objective	8
1.6.2 Specific objectives	8
CHAPTER 2:LITERATURE REVIEW.....	9
2.1 Diagnostic Tools for Identifying Root and Root Canal Morphology	9
2.1.1 Historical sectioning technique.....	9
2.1.2 Staining and clearing technique	10
2.1.3 Two-dimensional radiography	12

2.1.4 Cone beam computed tomography	13
2.1.4.(a) Types of CBCT machines	16
2.1.4.(b) Benefits and limitations of CBCT.....	18
2.2 Characterization and Classification of the Root and Root Canal system.....	24
2.2.1 Weine's classification	25
2.2.2 Vertucci's classification and its supplemental configurations.....	27
2.2.3 The new classification for root canal morphology	31
2.3 Maxillary Anterior Teeth	35
2.3.1 Number of roots	37
2.3.2 Root canal configurations	37
2.3.2.(a) Ethnicity	38
2.3.2.(b) Gender	39
2.3.2.(c) Age	40
2.3.3 Experimental and clinical studies	40
2.4 Mandibular Anterior Teeth	44
2.4.1 Number of roots	46
2.4.2 Root canal configurations	46
2.4.2.(a) Ethnicity	47
2.4.2.(b) Gender	48
2.4.2.(c) Age	48
2.4.3 Experimental and clinical studies	49
2.5 Prevalence of Root Canal Morphology in Malaysian population	54
CHAPTER 3:MATERIALS AND METHODS.....	57
3.1 Study design	57

3.2 Reference Population	57
3.3 Source of Population	57
3.4 Ethical Approval	58
3.5 Inclusion and Exclusion Criteria	58
3.5.1 Inclusion criteria	58
3.5.2 Exclusion criteria	58
3.6 Sampling Method	59
3.7 Sample size Calculation.	59
3.7.1 Objective 1	59
3.7.2 Objective 2	60
3.7.3 Objective 3	61
3.7.4 Objective 4 and Objective 5	61
3.8 Methods	62
3.9 Research Tools	63
3.10 Data collection	66
3.10.1 Radiological assessment	66
3.10.2 Patient record	67
3.11 Variables	67
3.11.1 Dependent variables	67
3.11.2 Independent variable	72
3.12 Subject Vulnerability	74
3.13 Privacy and Confidentiality	74
3.14 Declaration of Absence of Conflict of Interest	74
3.15 Community Sensitivity and Benefits	74

3.16 Honorarium and Incentives	75
3.17 Statistical Analysis	75
3.18 Intra Examiner reliability	75
3.18.1 Radiographic evaluation reliability	75
CHAPTER 4:RESULTS.....	76
4.1 Demographic Data Analysis	76
4.2 Evaluation of Number of Roots in Maxillary And Mandibular Anteriors	76
4.3 Evaluation of Root Canal Morphology Variations in Maxillary Anteriors Using Vertucci's Classification	79
4.4 Evaluation of Root Canal Morphology Variations in Mandibular Anteriors Using Vertucci's Classification	79
4.5 Evaluation of Root Canal Morphology Variations in Maxillary Anteriors Using Ahmed <i>et al</i> Classification.	82
4.6 Evaluation of Root Canal Morphology Variations in Mandibular Anteriors Using Ahmed <i>et al</i> . Classification.	82
4.7 Evaluation of Root Canal Morphology Based on Gender in Permanent Anteriors	92
4.8 Evaluation of Root Canal Morphology Based on Ethnicity in Permanent Anteriors.....	92
4.9 Evaluation of Root Canal Morphology Based on Age in Permanent Anteriors	97
CHAPTER 5:DISCUSSION.....	104
5.1 The use of CBCT in Endodontics	104
5.2 Root Morphology in Permanent Anterior Teeth	105
5.3 Root Canal Morphology in Permanent Anterior Teeth.....	106
5.3.1 Maxillary permanent anteriors.....	106

5.3.2 Mandibular permanent anteriors	107
5.3.3 Ethnicity	109
5.3.4 Gender	111
5.3.5 Age	114
5.4 Comparison Between Vertucci's and the New Classification Systems	115
5.5 Limitations of the Study	117
CHAPTER 6:CONCLUSIONS AND RECOMMENDATIONS.....	118
6.1 Conclusions	118
6.2 Clinical benefits	119
6.3 Recommendations	119
REFERENCES.....	120
APPENDICES	

LIST OF APPENDICES

APPENDIX A:	Human Ethical Approval
APPENDIX B:	Turnitin Report
APPENDIX C:	Conference Presentations
APPENDIX D:	Publication

LIST OF TABLES

	Page
Table 2.1: CBCT unit design based on scan volume height.	17
Table 2.2: Uses of CBCT in endodontics.....	19
Table 2.3: Principles recommended by European and North American Guidelines.	20
Table 2.4: Effective radiation dose by ICRP and American Academy of Oral and Maxillofacial Radiology.....	22
Table 4.1: Demographic characteristics.	77
Table 4.2: Number of roots in anterior teeth.	78
Table 4.3: Distribution and percentage of root canal morphology variants in maxillary anterior according to Vertucci's classification.	80
Table 4.4: Distribution and percentage of root canal morphology variants in mandibular anterior according to Vertucci's classification.	81
Table 4.5: Distribution and percentage of root canal morphology variants in maxillary anterior according to Ahmed et al classification.	83
Table 4.6: Distribution and percentage of root canal morphology variants in mandibular anterior according to Ahmed et al classification.	84
Table 4.7: Distribution of root canal morphology based on gender in maxillary anterior using Pearson Chi-square/Fisher's exact tests.	93
Table 4.8: Distribution of root canal morphology based on gender in mandibular anterior.	94

Table 4.9: Distribution of root canal morphology based on ethnicity in maxillary	
anterior.	95
Table 4.10: Distribution of root canal morphology based on ethnicity in mandibular	
anterior.	96
Table 4.11: Distribution of root canal morphology based on age in maxillary central	
incisors.	98
Table 4.12: Distribution of root canal morphology based on age in maxillary lateral	
incisors.	99
Table 4.13: Distribution of root canal morphology based on age in maxillary	
canines.	100
Table 4.14: Distribution of root canal morphology based on age in mandibular central	
incisors.	101
Table 4.15: Distribution of root canal morphology based on age in mandibular lateral	
incisors.	102
Table 4.16: Distribution of root canal morphology based on age in mandibular	
canines.	103

LIST OF FIGURES

	Page
Figure 2.1: IOPA film of mandibular second premolar	15
Figure 2.2: Weine's classification of root canal morphology from Type I to Type IV. .	26
Figure 2.3: Vertucci's classification of root canal morphology from type I to type VIII.	28
Figure 2.4: Supplemental configuration types to Vertucci's classification system for root canal morphology.....	30
Figure 2.5: New classification of root and root canal morphology in single rooted teeth.....	34
Figure 2.6: Maxillary anterior teeth	36
Figure 2.7: Mandibular anterior teeth	45
Figure 3.1: Planmeca Promax 3D CBCT machine (Planmeca OY Helsinki, Finland)...	64
Figure 3.2: The software used for image analysis, Romexis ver.2.9.2 (Planmeca Promax 3D).....	65
Figure 3.3: CBCT images with root and canal morphology in axial plane.	70
Figure 3.4: Showing types of root canal morphology.....	71
Figure 4.1: CBCT sagittal view of maxillary anteriors showing root canal morphology.	85
Figure 4.2: CBCT sagittal and axial (coronal, middle and apical) views of maxillary canines showing root canal morphology.....	86
Figure 4.3: CBCT sagittal view of various mandibular anteriors showing different root canal morphologies.	88

Figure 4.4: CBCT images of mandibular anteriors showing different root canal morphologies.....	89
Figure 4.5: CBCT images of mandibular anteriors showing different root canal morphologies.....	90
Figure 4.6: CBCT images sagittal and axial (coronal, middle and apical) views of mandibular canines showing two roots.....	91

LIST OF ABBREVIATIONS

ALARA	As Low As Reasonable Achievable
CBCT	Cone Beam Computed Tomography
CCD	Charged Coupled Device
CT	Computed Tomography
FDA	Food and Drug Administration
FDI	Federation Dentaire Internationale
FOV	Field of View
HERS	Hertwig's Epithelial Root Sheath
ICRP	International Commission on Radiological Protection
JEPeM	Jawatankuasa Etika Penyelidikan Manusia
LLI	Lower Lateral Incisors
MA	Maxillary Anteriors
MCT	Micro Computed Tomography
MD	Mandibular Anteriors
0-C-F	Orifice-Canal-Foramen
PSP	Photostimulable Phosphor Plate
RN	Registration Number
SD	Standard Deviation
UC	Upper Canine
2D	Two Dimensional
3D	Three Dimensional

**KAJIAN TOMOGRAFI BERKOMPUTER PANCARAN KON KE ATAS
MORFOLOGI AKAR DAN KANAL AKAR MENGGUNAKAN KLASIFIKASI
BARU DI KALANGAN TIGA KUMPULAN ETNIK DI KELANTAN,
MALAYSIA**

ABSTRAK

Pengetahuan yang lengkap dan kefahaman mendalam terhadap sistem kanal akar adalah penting bagi pra-syarat rawatan endodontik. Secara umumnya, kedua-dua gigi anterior maksila dan mandibel mempunyai akar tunggal yang melitupi kanal tunggal. Namun begitu, maklumat menunjukkan dua kanal pada gigi kacip mandibel mempunyai prevalen yang lebih tinggi, di mana kepelbagaian bergantung kepada etnik, jantina dan umur. Oleh itu, tujuan kajian ini adalah untuk mengenalpasti morfologi akar dan kanal dalam kalangan sub-populasi rakyat Malaysia menggunakan tomografi pancaran kon berkomputer bim-kon (CBCT) menerusi dua sistem pengkelasan. Imej CBCT membabitkan 856 orang pesakit, berusia di antara 14 sehingga 70 tahun yang mempunyai 10080 anterior dinilai menggunakan perisian Romexis ver.2.9 (Planmeca Promax 3D). Bilangan dan morfologi akar dan kanal akar bagi gigi kekal anterior ditentukan menerusi satah berbeza (korona, aksial, sagital) dan diklasifikasikan menggunakan kaedah pengkelasan Vertucci's dan Ahmed *et. al.* Pearson Chi-square/Fisher's exact tests digunakan untuk menganalisis statistik ($P=0.05$). Berdasarkan pengkelasan Ahmed *et. al* dan Vertucci, kod $^1MA^1$ (MA- anterior maksila) dan Jenis 1 merupakan yang paling lazim (98.2%), diikuti gigi kacip sentral mandibel (64.7%) dan taring (90.5%) manakala kod $^1MD^{1-2-1}$ (MD- anterior mandibel) dan Jenis III merupakan yang paling lazim pada gigi

kacip lateral mandibel (51%). Beberapa variasi di luar pengkelasan Vertucci dikenalpasti dan diklasifikasikan menggunakan sistem baharu. Kod berkenaan termasuklah kod ${}^1\text{MD}^{2-1-2-1}$ (2.1%) dan ${}^1\text{MD}^{2-1-2-1-2-1}$ (0.1%). Dua akar taring mandibel juga dikenalpasti dalam enam sampel. Prevalen variasi terhadap kanal akar pada gigi kacip mandibel adalah tinggi dalam kalangan lelaki berbanding perempuan ($P<0.001$), Melayu diikuti Cina dan India ($P<0.001$), dan kumpulan umur 20-30 tahun berbanding kumpulan umur yang lain ($P<0.001$). Tiada perbezaan signifikan didapati pada anterior maksila. Anterior mandibel menunjukkan variasi yang ketara di antara anatomi akar dan kanal. Tatarajah kanal akar yang kompleks dipengaruhi oleh jantina, etnik dan umur. Sistem pengkelasan baharu ini memudahkan dan dapat menunjukkan morfologi kanal akar dengan lebih tepat terutama dengan kehadiran variasi yang rumit.

CONE-BEAM COMPUTED TOMOGRAPHY STUDY OF ROOT AND ROOT CANAL MORPHOLOGY USING NEW CLASSIFICATION IN THREE ETHNIC GROUPS IN KELANTAN, MALAYSIA

ABSTRACT

Adequate knowledge and comprehensive understanding of the root canal system is an essential pre-requisite for endodontic treatment. It is a general conviction that both maxillary and mandibular anterior teeth have single roots encasing single canals. However, literature shows higher prevalence of two canals in mandibular incisors which varies according to ethnicity, gender and age. Hence the aim of this study was to evaluate the root and canal morphology in Malaysian sub-population using cone beam computed tomography (CBCT) interpreted using two different classification systems. CBCT images of 856 patients with age ranging from 14 to 70 years, having 10080 anteriors were examined using software Romexis ver.2.9 (Planmeca Promax 3D). The number of roots and the root canal morphology of permanent anterior teeth were determined in different planes [coronal, axial and sagittal] and classified using Vertucci's and Ahmed *et al* classification systems. Pearson Chi-square/Fisher's exact tests were used for statistical analysis ($P=0.05$). According to Ahmed *et al* and Vertucci's classifications, code $^1MA^1$ (MA- maxillary anteriors) and Type I were the most common in maxillary anteriors (98.2%), mandibular central incisors (64.7%) and canines (90.5%) respectively, whereas code $^1MD^{1-2-1}$ (MD- mandibular anteriors) and Type III were the most common in mandibular lateral incisors (51%). Several Vertucci's non-classifiable variations were identified which were classified using the new system. These include codes $^1MD^{2-1-2-1}$

(2.1%), and $^1\text{MD}^{2-1-2-1-2-1}$ (0.1%). Two-rooted mandibular canines were identified in six samples. The prevalence of root canal variations in mandibular incisors was higher in males compared to females ($P<0.001$), Malay followed by Chinese and Indians ($P<0.001$), and in 20-30 age group as compared to other age groups ($P<0.001$). No significant difference was found in maxillary anteriors. Mandibular anteriors show a wide range of root and canal anatomical variations. The complexity of the root canal configuration is significantly affected by sex, ethnicity and age. The new classification system provides a simple and accurate presentation of the root canal morphology, especially in cases where complex root canal morphology is present.

CHAPTER 1

INTRODUCTION

1.1 Background of the study

Adequate knowledge and comprehensive understanding of the root canal system is an essential pre-requisite for endodontic treatment. In addition, clinicians must be aware of complex root canal configurations to ensure complete chemo-mechanical instrumentation of all canals followed by three dimensional filling of the root canal space (Peikoff and Trott, 1977; Vertucci, 2005).

Literature shows that apical percolation from incomplete root canal treatment or the presence of an untreated root canal is the main cause of root canal treatment failures (Ingle and Baumgartner, 2008). There are differences in the root canal morphology of different populations; thus, identifying the root canal anatomy of different ethnic populations is required for successful endodontic treatment (Altunsoy *et al.*, 2015). Furthermore, dental practitioners should be familiar with the normal as well as unusual root and root canal morphological variations encountered in daily practice (Zhengyan *et al.*, 2016).

It is a general conviction that both maxillary and mandibular anterior teeth have single roots encasing single canals. However, literature shows higher prevalence of two canals in mandibular incisors (Nogueira Leal da Silva *et al.*, 2016; Rankine-Wilson and Henry, 1965), which varies according to ethnicity, gender and age (Cleghorn *et al.*, 2008; Zhengyan *et al.*, 2016).

Conventional methods used for analysing root and root canal morphology such as sectioning, canal staining and root clearing technique (Gupta *et al.*, 2014; Habib and Kalaji, 2015), electron microscopy, and stereomicroscopy (Cheung *et al.*, 2007) are usually invasive and require special preparations. Radiography is one of the major clinical tools in endodontic treatment. However, clinicians cannot consider a conventional radiograph as an appropriate assessing tool in case of complex root canal morphology. This is because of limitations such as distortion and superimposition of supporting structures, wherein it fails to identify the complexity of root canal characteristics (Aminsobhani *et al.*, 2013; Cotton *et al.*, 2007).

Cone-beam computed tomography (CBCT) scanning has been used in the field of endodontics since 1990. It offers a non-destructive technique and provides more precise analysis of the root canals. It helps in accurate examination of internal and external anatomy of the tooth and surrounding structures (Patel *et al.*, 2010). Obtained anatomy can be examined in 360-degree axis with three-dimensional view from different angles allowing both qualitative and quantitative assessment of characteristics of the tooth. The most important advantage of CBCT when compared with conventional CT includes less radiation exposure with high quality image allowing the evaluation of tooth and its bony structures. Thus, this three-dimensional, non-interventional technique has more advantages in endodontic practice with respect to enhanced diagnostic quality and image analysis with automated function (Cotton *et al.*, 2007; Zhengyan *et al.*, 2016).

1.2 Problem Statement

Root canal configurations in permanent anteriors vary with gender (Altunsoy *et al.*, 2014; Nogueira Leal da Silva *et al.*, 2016). Different populations also have influence on the complexity of the root canal morphology of anterior teeth and several studies conducted amongst Turkish, Chinese, Iranian, Jordanian and American populations revealed variations in root canal morphology of permanent anterior teeth (Al-Qudah and Awawdeh, 2006; Caliskan *et al.*, 1995; Rahimi *et al.*, 2013; Sert and Bayirli, 2004; Vertucci, 1978; Weng *et al.*, 2009).

The prevalence of accessory roots and canals was more in mandibular anteriors than maxillary, however, maxillary incisors had more prevalence of accessory canals mainly caused by anomalies (Ahmed and Hashem, 2016). A study conducted earlier to determine the root morphology in mandibular anteriors found that 4.7% of mandibular canines had two roots (Aminsobhani *et al.*, 2013). Another study found that 0.1% lateral incisors and 3.1% canines had two roots (Kayaoglu *et al.*, 2015). These results show that adequate understanding of the root and canal morphology in different population groups is essential before practicing root canal treatment.

Vertucci's classification and its supplemental configurations do not classify all root canal configurations. Few studies conducted have revealed non-classifiable root canal morphology during determination of anatomical canal variation using 3D imaging methods (Kim *et al.*, 2013; Lee *et al.*, 2014; Leoni *et al.*, 2014; Verma and Love, 2011). Another study found that about 13% of the root canal anatomy did not fit the Vertucci's

classification system and its modifications (Filpo-Perez *et al.*, 2015). A new system for classifying the root and canal morphology has been introduced, which has generated an interest in research and clinical practice (Ahmed *et al.* 2017).

1.3 Justification of the Study

Several studies found a high percentage of mandibular anterior teeth presenting with different root canal morphology (Type II, III, IV, V, VI and VII, according to Vertucci's classification) and found significant difference with respect to ethnicity and gender (Aminsobhani *et al.*, 2013; Sert and Bayirli, 2004; Zhengyan *et al.*, 2016). Several studies conducted in American and Turkish populations have reported that maxillary central incisor teeth have one canal in 100% population (Caliskan *et al.*, 1995; Vertucci, 1978). However, studies conducted in Turkish, Chinese, American and Brazilian population show a small percentage (0.7% to 1.8%) of maxillary incisors presenting a different morphology [TYPE II, III, IV and V, according to Vertucci's classification]. However, maxillary canines presented only with Type 1 configuration (Altunsoy *et al.*, 2014; Nogueira Leal da Silva *et al.*, 2016; Weng *et al.*, 2009).

To the best of our knowledge, only few studies have been conducted to study the root canal morphology of permanent anterior teeth using CBCT (Altunsoy *et al.*, 2014; Nogueira Leal da Silva *et al.*, 2016). Up to date, no clinical study has been conducted to evaluate the root and root canal morphology in permanent anterior amongst Malaysian population. Furthermore, few studies were conducted using the new classification system

given by Ahmed *et al* (Saber *et al* 2019), and till date no study has been conducted in Malaysian population to evaluate the root and canal morphology in permanent anteriors using new classification system.

Hence, this study will help Malaysian clinicians to understand the root and canal morphology and avoid endodontic treatment failures because of missed canals. Studies have demonstrated that variation in root canal morphology of anterior permanent teeth with respect to sex and ethnicity does exist. Malaysian population has three major ethnic groups (Malay, Chinese, and Indian), hence, it is important to understand the canal morphology in populations with different ethnic groups.

1.4 Research Questions

1. Is there a significant variation in the number of roots in anterior permanent teeth in Malaysian population determined using CBCT?
2. Is there a significant variation in the root canal morphology of anterior permanent teeth in Malaysian population determined using CBCT?
3. Is there a significant variation in number of roots and root canal morphology of anterior permanent teeth in Malaysian population determined using CBCT based on gender?
4. Is there a significant difference in the number of roots and root canal morphology of anterior permanent teeth in Malaysian population determined using CBCT based on ethnicity?

5. Is there a significant difference in the number of roots and root canal morphology of anterior permanent teeth in Malaysian population determined using CBCT based on age?
6. Is there a significant difference in Vertucci's root canal classification and new classification system in classifying root canal morphology of anterior permanent teeth in Malaysian population?

1.5 Research Hypotheses

1.5.1 Null hypotheses

1. There is no significant difference in the number of roots in permanent anterior teeth in Malaysian population determined using CBCT.
2. There is no significant difference in the root canal morphology of permanent anterior teeth in Malaysian population determined using CBCT.
3. There is no significant difference in the number of roots and root canal morphology of permanent anterior teeth in Malaysian population based on gender determined using CBCT.
4. There is no significant difference in the number of roots and root canal morphology of permanent anterior teeth in Malaysian population based on ethnicity determined using CBCT.
5. There is no significant difference in the number of roots and root canal morphology of permanent anterior teeth in Malaysian population based on age determined using CBCT.

6. There is no significant difference in Vertucci's root canal classification and new classification system in classifying root canal morphology of anterior permanent teeth in Malaysian population.

1.6 Objectives of the study

1.6.1 General objective

To evaluate the root and root canal morphology in anterior permanent teeth using CBCT in a Malaysian population using a new classification system (Ahmed *et al.* 2017).

1.6.2 Specific objectives

1. To determine the variation in number of roots in anterior permanent teeth in Malaysian population using CBCT.
2. To determine the variation in root canal morphology of the anterior permanent teeth in Malaysian population using CBCT.
3. To evaluate the effect of gender on the variation in number of roots and root canal morphology in Malaysian population using CBCT.
4. To evaluate the effect of ethnicity on the variation in number of roots and root canal morphology in Malaysian population using CBCT.
5. To evaluate the effect of age on the variation of root canal morphology in Malaysian population using CBCT.
6. To compare between Vertucci's root canal classification with new classification system (Ahmed *et al* 2017) in classifying root canal morphology of anterior permanent teeth in Malaysian population.

CHAPTER 2

LITERATURE REVIEW

2.1 Diagnostic Tools for Identifying Root and Root Canal Morphology

The investigation of external and internal anatomy of different teeth using many *in vitro* and *in vivo* techniques was initiated many years ago. Various *in vitro* techniques were used to identify root and canal morphology which includes root sectioning, staining and tooth clearing, microscopic investigation, radiographic investigations using conventional radiographs and three-dimensional techniques such as CBCT and micro-computed tomography (MCT) (Ahmad, 2015). The *in vivo* techniques include conventional radiographic examinations, retrospective evaluation of patient's data, clinical evaluation during root canal treatment, digital radiography and advanced radiographic technique like CBCT (Ahmad, 2015).

2.1.1 Historical sectioning technique

The root canal vulcanite replicas were made in the year 1925, which was used as a teaching aid during that period. But the authors did not include the pulp chambers (Hess, 1925). Sommer *et al* (1957) showed a technique by using longitudinal sectioning to produce a sagittal view of pulp space from pulp chamber to the root apex (Sommer, 1957). Opaque wax was used to fill the exposed canals, but this method showed lateral canals very rarely (Gupta *et al.*, 2014). Rosenstiel (1957) introduced a technique using a Radio

opaque material to reproduce the root canals. Papain digesting solution was used to remove the pulp remnants. A hole was drilled at the proximal surface of the tooth to the pulp chamber, then using a syringe the material was introduced. Radiographs were taken and examined by mounting together or superimposing on one another. Drawback of this technique was three-dimensional feature of the pulp and its complexity was lost, only two-dimensional radiographs were produced (Rosenstiel, 1957).

Sectioning of teeth involves the longitudinal cross section. Weine *et al.* (1969) did sectioning of the maxillary molar teeth using coarse sand paper disks, thus exposing the root canals (Weine *et al.*, 1969). Greene *et al.* (1973) studied the root canal morphology of 1300 teeth by sectioning vertically and found high incidence of double canal in single roots (Green, 1973). Perrini *et al.* (1991) evaluated the incidence of number of canals in coronal, middle, and apical third of the root in mandibular incisors using horizontal sectioning technique, and found that 36.1% of samples had multiple canals (Perrini *et al.*, 1991).

2.1.2 Staining and clearing technique

In one study Seelig and Gillis (1973) proposed a technique and it was adapted by Vertucci (1974). They injected a dye into the root canal systems of cleared teeth followed by placing them in acrylic casting ring so that the subsequent specimens can be viewed from any direction, rather than just from the direction grounded or the radiograph obtained (Seelig and Gillis, 1973).

A study was conducted by Caliskan *et al.* (1995) to determine the root canal morphology of human permanent teeth amongst Turkish population. A total of 1400 human permanent teeth were collected from various oral surgery practices to evaluate number and type of root canal, location of apical foramen, ramification and anastomosis of canals. Extracted teeth were decalcified, cleared and injected with India ink. Root canal morphology was classified using Vertucci's classification. Authors concluded that, the variation in the root canal morphology among maxillary teeth were found in second premolar and mesiobuccal roots of first and second molars. While, in mandibular teeth, variations were found in all the teeth except second premolars (Caliskan *et al.*, 1995). In this study, authors did not record the gender and age of the patient, as in few other *in vitro* studies. Hence the effect of gender and age on the root canal morphology could not be determined.

Another *in vitro* study was conducted by Sert and Bayirli (2004) on Turkish population to evaluate the root canal configuration of maxillary and mandibular permanent teeth by gender. A total of 2800 teeth from 1400 males and 1400 females were examined. Extracted teeth were collected from Gulhane Military Medical academy, Haydarpasa Dentistry Center, Turkey. Furthermore, teeth were divided in seven groups based on tooth type (central, lateral, canine, first premolar, second premolar, first molar and second molar) and gender to evaluate the root canal morphology. Root canal pattern was determined using clearing technique followed by staining with India ink and classified using Vertucci classification. Additional forms of root canals were also evaluated. Authors gave 14 additional modification to the mainly used Vertucci classification for root canal morphology. They indicated the importance of patient gender and ethnicity in evaluation of root canal morphology (Sert and Bayirli, 2004). In this study, only 100 teeth

from each tooth type were collected, which can be considered a small sample to evaluate root canal morphology. Furthermore, authors recorded the differences in gender but did not record age of the patient. This could be because of cessation of growth hormones amongst elderly patients compared to younger.

2.1.3 Two-dimensional radiography

Cathode rays were first discovered by Wilhelm Konrad Rontgen in 1895 which contribute to the dental examination and investigation with amazing properties. The first radiography to diagnose the hard structures and determine the size, shape, locations and direction of root and root canals was taken by Otto Walkhoff in 1896 (Vertucci, 1984). Conventional radiographs help in routine endodontic treatment and in identifying root canal length. The long cone technique provides clarity of hard structures with minimal distortion; hence this technique is preferred in diagnosis and post treatment radiographs. An important alteration was done to visualize the third dimensions in dental radiographs by varying the horizontal angulation and it was introduced by Walton (Grover and Shetty, 2012).

Several studies were conducted to determine root and canal morphology in permanent maxillary and mandibular teeth using conventional radiographs in different angulations (Cunningham and Senia, 1992; Green, 1956; Khedmat *et al.*, 2010; Pineda and Kuttler, 1972; Zillich and Dowson, 1973). Goldman *et al* (1972) has verified the errors in radiographic interpretation. Conventional radiographs produce two-dimensional view of three-dimensional structures, subjected to processing errors, image distortions, anatomical limitations as it cannot cover buccolingual direction in single film (Goldman *et al.*, 1972).

2.1.4 Cone beam computed tomography

CBCT overcomes many disadvantages of conventional radiographs like image distortion, anatomic noise and density of three dimensional (3D) anatomic structures by producing two dimensional (2D) images in various planes. CBCT is a contemporary system which provides a three-dimensional image of a small area of interest with a low radiation, providing sufficient information. Hence, it is an important tool in endodontics for diagnosis, treatment planning, and to check prognosis post treatment (Durack and Patel, 2012).

A comparative study was done by Tu *et al.* (2007) to assess root canal morphology of mandibular first molar teeth in Taiwanese population using CBCT. They reported a high rate of distolingual roots (about 33%) but when compared with the conventional radiographs it was 21% (Tu *et al.*, 2007). A study compared CBCT with charged coupled device [CCD] and photostimulable phosphor plate [PSP] in relation with root canal morphology. They reported that both CCD and PSP failed to determine at least one root canal system in around four out of ten teeth (Matherne *et al.*, 2008). Failure to detect a canal will lead to incomplete root canal treatment and result in treatment failure.

CBCT provides 3D radiographic images with only one single rotation of 180 degrees, providing an accurate, defined and instant image of the field of view (FOV). In the year 2001 food and drug administration (FDA) United States approved the first CBCT machine for use in dentistry, later in 2003 three more CBCT units were approved followed by a number of CBCT units being approved by FDA. When the conventional radiographs

cannot provide the required information of root canal systems, CBCT is a useful aid in such condition as it gives a 3D image which can be seen in different plans. Hence, clinicians can examine the root canal system very precisely (Durack and Patel, 2012; Scarfe *et al.*, 2009).

CBCT scanning takes shorter time (about 10 to 20 seconds) and scanning can be done while patient is in sitting or standing position. Both hardware and software of CBCT is simpler and lower in cost, as compared to conventional CT, and the assembly is small enough to fit in a dental practice. Radiation in CBCT (18–200 μSv) is less when compared with conventional CT (400 to 1000 μSv). However, it is more than a periapical conventional radiograph (1–8 μSv).

The best suited scanner for endodontic practice is limited scan volume CBCT scanner which can provide smaller FOV scans limited to a single tooth or two teeth like a conventional intra oral periapical radiograph. CBCT reveals the actual number of root canals, accessory canals and the root canal curvature. Additionally, the actual direction of the root canal can be accurately identified (Patel *et al.*, 2010). In instances of resorption lesions and diagnosis, CBCT reconstructed images play a crucial role, especially in determination of perforation because of resorption in the canal or the adjacent tissues as shown in figure 2.1 (Durack and Patel, 2012). CBCT images are also useful in investigating uncommon anatomy or morphology like uncommon number of roots, dens in dente and dilaceration and exact location of root canals and root canal characteristics (Patel *et al.*, 2010).

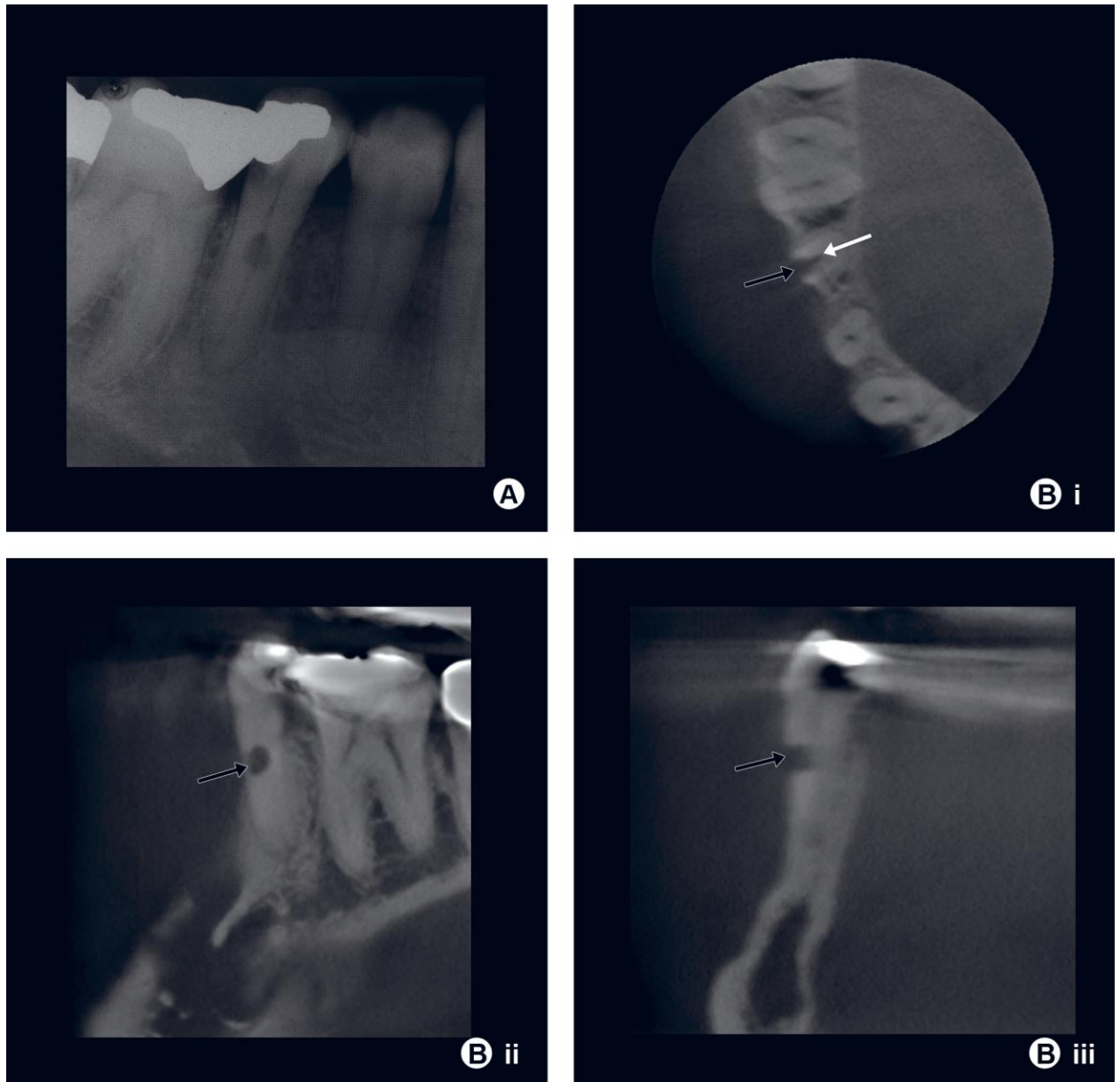


Figure 2.1: IOPA film of mandibular second premolar

A) which shows sign of root resorption. It is not clear from the radiograph if it is internal or external or has resorption perforated the wall of root canal. B) Axial (i), coronal (ii) and sagittal (iii). It is clear from the CBCT images that the resorption started on the external surface of the root shown with black arrows and has perforated the root canal wall. The root canal shows no signs of ballooning enlargement related with internal resorption shown with white arrow adapted from Durack and Patel (2012).

2.1.4.(a) Types of CBCT machines

Depending on the patient position and scan volume, CBCT machines can be divided into different types. Depending on patient positioning three types [1] sitting [2] standing and [3] supine. Depending on scan volume or the dimensions of FOV, it depends on detector shape, size and projection of beam. Shape of the FOV is usually cylindrical or spherical. Based on scan volume it can be divided as listed in table 2.1 (Scarfe *et al.*, 2009).

Table 2.1: CBCT unit design based on scan volume height.
(Scarfe et al., 2009).

Unit design	Scan volume height (cms)
Localized region	5 or less than 5.
Single arch	5 to 7.
Inter arch	7 to 10.
Maxillofacial	10 to 15.
Craniofacial	More than 15.

2.1.4.(b) Benefits and limitations of CBCT

The clinicians should know the risks and benefits of CBCT before prescribing to patients. If conventional radiographs fail to reveal the proper structures or to diagnose the complex root or canal configuration or abnormality, then a CBCT is indicated. CBCT scans should only be prescribed in cases where the potential benefits of diagnosis and treatment planning and treatment outcomes outweigh the potential risks of radiation (Protection No, 2012). Even the use of lead apron is not required in pregnant females because of negligible radiation. However, use of leaded glass, thyroid collars and colimitation is recommended to minimize radiation outside FOV (Tsapaki, 2017).

The “As Low As Reasonable Achievable” (ALARA) principle should be considered in all the cases advised for CBCT. One must be very particular with the device producing ionization radiations especially in children and adolescent patients as they are more radiosensitive (Theodorakou *et al.*, 2012). CBCT with limited FOV is usually used in endodontics and can be used in the conditions listed in table 2.2 (Patel *et al.*, 2019a; Patel *et al.*, 2014). A study demonstrated that CBCT scanning with 3D software gives more acceptable results for determination of root canal morphology and estimated working length (Patel *et al.*, 2019b). The clinicians should know the basic principles and follow them before prescribing CBCT for any patients. The basic principles are recommended by European and North American Guidelines as listed in table 2.3 (2012).

Table 2.2: Uses of CBCT in endodontics.

(Patel et al., 2019a).

1.	Periapical pathology with nonspecific signs and symptoms.
2.	To diagnose the causes of non-odontogenic pathologies.
3.	Evaluation of dento alveolar trauma, where conventional radiograph cannot reveal luxation, root fracture or the alveolar structure fracture.
4.	Determine the complex root canal systems for endodontic treatment.
5.	Determine abnormal root anatomy or anomaly
6.	Evaluate the complication of endodontic treatment planning and non-surgical endodontics.
7.	To check root resorption and confirm internal or external resorption or involvement with root canal wall

Table 2.3: Principles recommended by European and North American Guidelines.
(Protection No, 2012)

Principle 1.	CBCT should not be used for all patients routinely.
Principle 2.	Unless a history and clinical examination have been performed CBCT assessments must not be carried out.
Principle 3.	CBCT assessment must be justified for each patient.
Principle 4.	FOV should be restricted as much as possible.
Principle 5.	The lowest achievable resolution should be used without jeopardizing examination of the region of interest.

The effective radiation dose calculation in CBCT depends on the shape of the scanner, resolution and the FOV. Effective radiation dose given by the ICRP and American Academy of Oral and Maxillofacial Radiology are given in table 2.4 (Shin *et al.*, 2014).

Table 2.4: Effective radiation dose by ICRP and American Academy of Oral and Maxillofacial Radiology.
(Shin et al., 2014)

Investigation	Radiation dose (mSv)
Jaws CBCT (FOV < 10 cm)	18 to 333
Face CBCT {(OV 10 - 15 cm)	61 to 603
Face CBCT (FOV 10 - 15 cm)	52 to 1073
Panoramic	6 to 50
Cephalogram	2 to 10
Computed tomography	426 to 1160

A study was conducted by Estrela *et al.* (2015) among the Brazilian subpopulation to determine the number of roots, root canal morphology and apical foramina in permanent teeth using CBCT. A total of 1400 teeth were used to evaluate the root numbers, root canal configuration and apical foramina. Two root canals in mandibular anteriors were reported in 35% of central incisors, 42% of lateral incisors and 22% of canine from the acquired cases. The authors concluded that any tooth may considerably show morphological variations. This condition makes clinician to use a very precise investigation like CBCT to determine the root and the root canal morphology for treatment planning (Estrela *et al.*, 2015).

Martins *et al.* (2017) conducted a study in Caucasian population to examine the root canal morphology in 11892 teeth. Authors classified root canal morphology using Vertucci's classification. Results showed that mandibular anteriors had two root canals in 30% of the cases. The root canal division and merging were commonly seen in mandibular teeth. Merging of canals in maxillary teeth was more common in the middle third of the root canal and in mandibular teeth it was common in middle and the apical thirds of the root canal. The authors concluded that practitioner should know that each tooth may show several types of root canal morphology, but to larger extent the root canal morphology variations are seen in maxillary second premolars and mesiobuccal root of maxillary molars. Furthermore, the division and rejoining of main root canal may occur at any level of the root (Martins *et al.*, 2017).

2.2 Characterization and Classification of the Root and Root Canal system

The pulp chamber mainly consists of a single cavity with multiple pulp horns in the coronal part of the tooth. With age, there will be reduction in the size of the pulp chamber which is mainly because of the formation of secondary dentine, which could be physiologic or pathologic. In response to pulpal irritation, tertiary dentine or reparative dentine may be formed which is uneven in structure (Chandra and Gopikrishna, 2014). The floor of the pulp chamber has the root canal orifices which are usually below the cusp tips. Root canals keep tapering as they extend toward the root apex, so the narrowest part will be at the minor apical foramen which is 0.5 to 1.0 mm short from anatomic (radiographic) root apex (Chandra and Gopikrishna, 2014). The root canal morphology present in permanent dentition, usually the anteriors and premolars have single canal except maxillary first premolars (two roots, both with single canals). Furthermore, maxillary molars usually have three canals, mesiobuccal, distobuccal and palatal. In mandibular molars, the three canals usually present are mesiobuccal, mesiolingual and distal (Carrotte, 2004).

Clinicians and Endodontists aim to achieve the best treatment outcome in endodontically treated cases. To attain the perfect treatment, one must diagnose the condition very well. Therefore, the complete knowledge of root canal morphology with comprehensive understanding of the root canal system complexity is very important in clinical practice to reach the treatment goal. Apart from normal root canal morphology the practitioner should have sound knowledge of possible root canal morphologic variations based on gender and ethnicity as well (Monsarrat *et al.*, 2016a; Vertucci, 2005).