

**Diagnostic Performance of Android-Based  
Handheld Device Using Endeavor Mobile  
Application in Interpretation of a Traumatic Non-  
Contrasted Computed Tomography (CT) Brain**

**By**

**DR. ASROF FIRDAUS BIN AHMAD**

**DISSERTATION SUBMITTED IN PARTIAL  
FULFILLMENT OF THE REQUIREMENTS FOR  
THE DEGREE OF MASTER OF MEDICINE  
RADIOLOGY**



**SCHOOL OF MEDICAL SCIENCES,  
UNIVERSITI SAINS MALAYSIA**

**2015**

**Diagnostic Performance of Android-Based  
Handheld Device Using Endeavor Mobile  
Application in Interpretation of a Traumatic Non-  
Contrasted Computed Tomography (CT) Brain**

**BY:**

**DR. ASROF FIRDAUS BIN AHMAD**

**Dissertation Submitted in Partial  
Fulfillment of the Requirements  
for the Degree of Master of Medicine  
Radiology**

**UNIVERSITI SAINS MALAYSIA**

**2015**

**Supervisors:**

**Assoc. Prof Dr. Mohd Ezane Aziz**

To my wife, Fazira Bt Sharin,

Words cannot express my feelings, nor my thanks for all your encouragement and support. You do make a difference to my life, shining it with your radiance and warmth aura. If the world had more people like you it would be a better place.

To both my children, Afiq Fitri & Auni Farisya ,

There has never been another you. With no effort on your part you were born to be something very special and set apart. Both of you have set aflame my heart for a greater cause in humanity. Thank you for coming into my life.

To my family members,

Your belief in me and the positive reputation uphold in me, has helped to groom me to be a better person striving for greater knowledge and the betterment of human life.

To my batch mates,

Your guys were always there to help and guide me, giving encouragement to me to finish this thesis; thank you everybody.

**Diagnostic Performance of Android-Based Handheld Device Using Endeavor Mobile Application in Interpretation of a Traumatic Non-Contrasted Computed Tomography (CT) Brain**

Dr. Asrof Firdaus Bin Ahmad

M.Med. Radiology

**Department of Radiology**

**School of Medical Sciences, University Sains Malaysia**

**Health Campus, 16150 Kelantan, Malaysia**

**ABSTRACT**

**Title:** Diagnostic Performance of Android-Based Handheld Device Using Endeavor Mobile Application in Interpretation of a Traumatic Non-Contrasted Computed Tomography (CT) Brain

**Purpose:** To determine the image viewing quality of the handheld device of Android premium devices and investigate the usage of handheld device in interpretation of CT images of trauma cases.

**Materials and methods:** Using Samsung Galaxy Note 10.1, we installed the AAPM TG-18 QC test pattern and recruited 30 candidates to do a subjective review of the QC test pattern on both handheld and workstation monitors. As for the investigation of using

handheld device to interpret CT images of trauma cases, we recruited 2 observers, consisting of a radiologist and a final year resident to review 180 cases of CT brain. Their findings would then be cross-referenced to a result obtained by a consultant radiologist using workstation monitor. Kappa test were used to calculate the interobserver agreement.

**Results:** There was 100% reproducibility of the same level of luminance patches, grayscale continuation and spatial resolution in the handheld device when compared to the workstation monitor. Other components investigated produced similar results when the candidates were allowed to zoom in and change the window settings. The sensitivity of detecting lesions on the images using handheld devices ranging from 50.0% to 84.6%. The negative predictive values were generally high indicating that the handheld device has high accuracy to determine absence of certain lesion. There was substantial agreement regarding the findings of both observer compared to gold standard test on workstation monitor.

**Conclusions:** Current generation of handheld devices has had viewing quality at par with workstation monitor and it is a reliable tool in reviewing CT for trauma cases.

Associate Professor Dr. Mohd Ezane Aziz (Supervisors)

## ACKNOWLEDGEMENT

Flattery is from the teeth out. Sincere appreciation is from the heart out. My sincerest thanks and gratitude to my supervisor, Associate Professor Dr Mohd Ezane Aziz (Lecturer and Radiologist, Department of Radiology, School of Medical Sciences, Universiti Sains Malaysia, Kubang Kerian, Kelantan) for his guidance and supervision. Thank you Professor for all you have done, and for all you are. You have influenced my life in such a positive way words cannot express my appreciation. The umpteenth amount of knowledge imparted from you has helped to widen my horizon.

This study was conducted as part of the Endeavour Mobile clinical study. The project has the USM grant type MOE-PRGS No:203/PKOMP/6740007 with title “Advanced Medical Imaging Prototype for Web Clients and Its Clinical Evaluation”.

One can never pay in gratitude: one can only pay 'in kind' somewhere else in life. I would love to take this opportunity to show my gratitude for the following parties that have directly contributed to my thesis. From the bottom of my heart, thank you for all you have done:

- **Dr. Nik Munirah bt Nik Mahdi**, Head of Department, Department of Radiology at Hospital Universiti Sains Malaysia.
- **Dr. Khairil Amir Sayuti**, Radiologist at Department of Radiology at Hospital Universiti Sains Malaysia.
- **Prof Dr Ibrahim Lutfi Shuaib**, Professor, Advance Medical and Dental Institute, Universiti Sains Malaysia.

- **Prof. Dr. Mandava Rajeswari**, Professor, Computer Vision Research Group, School of Computer Sciences at Universiti Sains Malaysia.
- **Dr Muhamad Fermi Pasha**, Post Doctoral Fellow, Computer Vision Research Group, School of Computer Sciences at Universiti Sains Malaysia.
- **Dr. Lee Chee Kong**, Registra of Radiology at Department of Radiology at Hospital Universiti Sains Malaysia.
- **En Zakaria Mohamad**, Computer Technician at Department of Radiology at Hospital Universiti Sains Malaysia.
- **Dr. Sarimah Abdullah**, Unit of Biostatistics and Research Methodology, School of Medical Sciences, Universiti Sains Malaysia, Kubang Kerian, Kelantan.
- **Professor Dr. Syed Hatim Noor@Nyi Nyi Naing**, Unit of Biostatistics and Research Methodology, School of Medical Sciences, Universiti Sains Malaysia, Kubang Kerian, Kelantan.
- All lecturers/radiologists, Department of Radiology, School of Medical Sciences, Universiti Sains Malaysia, Kubang Kerian, Kelantan.
- Hospital University Sains Malaysia Radiographers.

## TABLE OF CONTENT

<b>ACKNOWLEDGEMENT .....</b>	<b>ii</b>
<b>TABLE OF CONTENT .....</b>	<b>iv</b>
<b>LIST OF FIGURES .....</b>	<b>viii</b>
<b>LIST OF TABLES .....</b>	<b>x</b>
<b>LIST OF ABBREVIATIONS, SYMBOLS AND ACRONYMS .....</b>	<b>xiii</b>
<b>ABSTRACT .....</b>	<b>xiv</b>
<b>ABSTRAK.....</b>	<b>xvi</b>
<b>CHAPTER 1 INTRODUCTION .....</b>	<b>2</b>
1.1 Overview on handheld devices in medicine.....	2
1.2 Rationale of the Study .....	5
<b>CHAPTER 2 LITERATURE REVIEW .....</b>	<b>7</b>
2.1 Previous study comparison .....	7
2.2 Samsung Galaxy Note 10.1 (2014 version).....	8
2.3 Operating System.....	11
2.4 Android Operating System Advantages.....	11
2.5 Tablet Ownership among Adults .....	12
2.6 Application for Viewing Images .....	16
2.7 Factors Affecting Image Quality .....	20
2.8 CT Brain Protocol .....	22
2.9 Anatomy of the Brain .....	23
2.10 Traumatic Brain Injury .....	26
2.11 Tablet Usage Impact on the Residents of Radiology.....	35
2.12 Image Quality .....	36
<b>CHAPTER 3 OBJECTIVE.....</b>	<b>40</b>
3.1 General Objectives .....	40
3.2 Specific Objectives .....	40
<b>CHAPTER 4 METHODOLOGY .....</b>	<b>42</b>
4.1 Study Design .....	42
4.2 Research Questions .....	42
4.3 Sampling Method.....	43



4.4	Sample Size .....	43
4.5	Inclusion criteria .....	44
4.6	Exclusion criteria .....	44
4.7	Methods.....	44
4.7.1	CT Examination Protocol .....	46
4.7.2	Transferring Images from PACS to Android.....	47
4.7.3	Image Analysis.....	47
4.7.4	Scoring System among Observers for Objective 1 .....	48
4.7.5	Scoring System among Observers For Objective 2 and 3 .....	51
4.8	Expected Outcome .....	52
	Flow Chart for Data Collection .....	53
4.9	Statistical Analysis.....	54
<b>CHAPTER 5</b>	<b>RESULTS .....</b>	<b>58</b>
5.1	Handheld Device Display Monitor Quality .....	60
5.2	Interobserver agreement in interpretation of the CT scan images using the handheld device.....	62
5.2.1	Extradural Hemorrhage.....	63
5.2.2	Subdural Hemorrhage.....	64
5.2.3	Subarachnoid Hemorrhage .....	65
5.2.4	Intraparenchymal & Contusion Hemorrhage .....	66
5.2.5	Intraventricular Hemorrhage .....	67
5.2.6	Skull Fracture.....	68
5.2.7	Secondary Findings .....	69
5.2.8	Summary of Overall Result Agreement between Findings from Observer A and B using Handheld Device compared to Gold Standard.....	70
5.3	Sensitivity, specificity, accuracy, positive and negative predictive value, postive and negative likelihood ratio of handheld device in interpretation of a traumatic non-contrasted computed tomography (CT) brain. ....	72
5.3.1	Extradural Hemorrhage.....	72
5.3.1 1	Detection of Extradural Hemorrhage by Observer A and B using Handheld Device .....	72
5.3.1 2	Diagnostic Accuracy of Handheld Device in Detection of Extradural Hemorrhage .....	73
5.3.2	Subdural Hemorrhage.....	75

5.3.2 1	Detection of Subdural Hemorrhage by Observer A and B using Handheld Device .....	75
5.3.2 2	Diagnostic Accuracy of Handheld Device in Detection of Subdural Hemorrhage .....	76
5.3.3	Subarachnoid Hemorrhage .....	78
5.3.3 1	Detection of Subarachnoid Hemorrhage by Observer A and B using Handheld Device .....	78
5.3.3 2	Diagnostic Accuracy of Handheld Device in Detection of Subarachnoid Hemorrhage.....	79
5.3.4	Intraparenchymal & Contusion Hemorrhage .....	81
5.3.4 1	Detection of Intraparenchymal & Contusion Hemorrhage by Observer A and B using Handheld Device.....	81
5.3.4 2	Diagnostic Accuracy of Handheld Device in Detection of Intraparenchymal & Contusion Hemorrhage.....	82
5.3.5	Intraventricular Hemorrhage .....	84
5.3.5 1	Detection of Intraventricular Hemorrhage by Observer A and B using Handheld Device .....	84
5.3.5 2	Diagnostic Accuracy of Handheld Device in Detection of Intraventricular Hemorrhage .....	85
5.3.6	Skull Fracture .....	87
5.3.6 1	Detection of Skull Fracture by Observer A and B using Handheld Device .....	87
5.3.6 2	Diagnostic Accuracy of Handheld Device in Detection of Skull Fracture .....	88
5.3.7	Secondary Findings .....	90
5.3.7 1	Detection of Secondary Findings by Observer A and B using Handheld Device.....	90
5.3.7 2	Diagnostic Accuracy of Handheld Device in Detection of Secondary Findings compared to Gold Standard .....	91
5.3.8	Summary of Overall Diagnostic Performance of Handheld Device .....	93
<b>CHAPTER 6 DISCUSSION.....</b>		<b>96</b>
6.1	Introduction.....	96
6.2	Handheld Device Display Monitor Quality .....	96
6.3	Interobserver Agreement and Kappa Statistics .....	98
6.4	Sensitivity, specificity, accuracy, positive and negative predictive value, postive and negative likelihood ratio of handheld device in interpretation of a traumatic non-contrasted computed tomography (CT) brain. ....	100

<b>CHAPTER 7 CONCLUSION.....</b>	<b>104</b>
<b>CHAPTER 8 LIMITATION OF THE STUDY .....</b>	<b>105</b>
<b>CHAPTER 9 RECOMMENDATION FOR FUTURE STUDY.....</b>	<b>106</b>
<b>CHAPTER 10 REFERENCES .....</b>	<b>107</b>
<b>APPENDIXES .....</b>	<b>111</b>
APPENDIX A: QUESTIONNAIRE FOR EVALUATION OF DISPLAY MONITOR QUALITY .....	112
APPENDIX B: APPROVAL LETTER FROM HUMAN RESEARCH ETHICS COMMITTEE USH (HREC) .....	113
APPENDIX C: APPROVAL LETTER FROM HUSM DIRECTOR OFFICE TO USE CT IMAGES FOR THE STUDY .....	114
APPENDIX D: GANTZ CHART .....	115
APPENDIX E: SELECTED MISSED CASE BY CASE.....	116

## LIST OF FIGURES

<b>Figure 2.1</b>	Samsung Galaxy Note 10.1 (2014 edition). ....	9
<b>Figure 2.2</b>	Comparisons of popular tablets in the current market.....	10
<b>Figure 2.3</b>	The tablet ownership percentage among United States adults (Source: <i>The Mac Observer</i> from Pew Research data) .....	13
<b>Figure 2.4</b>	Tablets market share by platform through July 2011 (Source: <i>The Mac Observer</i> from Pew Research data).....	14
<b>Figure 2.5</b>	Tablet market share by manufacturer through August 2012 (Source: <i>The Mac Observer</i> from Pew Research data) .....	14
<b>Figure 2.6</b>	Worldwide device shipment by operating system in year 2014 (Source: Gartner IT infrastructure) .....	15
<b>Figure 2.7</b>	Number of radiology-related smartphone applications by category available from the different application stores. HIS = Hospital Information System (Source: Rodrigues, Visvanathan, Murchison, and Brady (2013)).....	17
<b>Figure 2.8</b>	Summary of the available “viewing software” smartphone applications. MIP = maximum intensity projection, MPR = multiplanar reformatting, PACS = picture archiving and communication system, ROI = region of interest, SUV = specific uptake value, VRT = volume-rendering technique, W/L = window level (Source: Rodrigues, Visvanathan, Murchison, and Brady (2013)).....	18
<b>Figure 2.9</b>	ENDEAVOR 3.1.1 officially on sale in google apps store (Source: Google apps store).....	20
<b>Figure 2.10</b>	Equipments and procedures to be complied with prior approval by DICOM standards (Source: medical.nema.org).....	21
<b>Figure 2.11</b>	Comparison of CT scan protocols among different models of SIEMENS CT scanner based on AAPM recomendation. Our HUSM model is Definition AS+ 128-slice (Source: www.healthcare.siemens.com) .....	23
<b>Figure 2.12</b>	Layers of the cerebrum (Sources: www.strokescentre.org) .....	25
<b>Figure 2.13</b>	Control centers of the brain (Sources: www.southerapyperth.com) .....	25
<b>Figure 2.14</b>	Schematic diagram of types of intracranial hemorrhage. (Sources: www.abclawcentre.com).....	27
<b>Figure 2.15</b>	Axial CT image (A) showed a biconvex hyperdense lesion at left temporal (red arrow) in keeping with an acute extradural hemorrhage. There was also an intraparenchymal bleed (blue arrow) at right frontal. (B) CT on bone window showed a subjacent liner skull fracture (Source: Hospital Universiti Sains Malaysia, 2014).....	28

<b>Figure 2.16</b>	Axial CT image (A) show a crescent-shaped hyperdense lesion at right frontoparietal (red arrows) in keeping with an acute subdural hemorrhage. There was also an acute subdural hemorrhage (blue arrow) and left subgaleal scalp hematoma (asterisk). (B) CT on lower level shows an asymmetry along the right tentorium (red arrows) in keeping with the subdural hemorrhage extension (Source: Hospital Universiti Sains Malaysia, 2014).....	29
<b>Figure 2.17</b>	Axial CT image showed a linear high attenuating lesion conforming to the sulci of the right fronto-parietal (vertical arrow) in keeping with an acute subarachnoid hemorrhage. There was also bifrontal subdural chronic hematoma with acute re-bleeding at the right frontal region (horizontal arrow). Associated with left subgaleal scalp hematoma (asterisk) (Source: Mount Sinai School of Medicine, 2009).....	30
<b>Figure 2.18</b>	Axial CT showed a hyperdensity within the right lateral ventricle and occipital horn of left lateral ventricle in keeping with acute intraventricular hemorrhage (Source: Hospital Universiti Sains Malaysia, 2009).....	31
<b>Figure 2.19</b>	Axial CT showed high density within the gyral crests of the bifrontal lobes in keeping with superficial cortical contusion (red arrows). There was also an acute extradural hemorrhage at right parietal (blue arrow). (Source: Hospital Universiti Sains Malaysia, 2014).....	32
<b>Figure 2.20</b>	Axial CT (A) showed small hyperdense focus (arrow) at the grey-white matter junction of the right frontal lobe and basal ganglia (red arrow) in keeping with diffuse axonal injury (Source: Hospital Universiti Sains Malaysia, 2014).....	33
<b>Figure 2.21</b>	Axial CT showed a hyperdense lesion within the left basal ganglia in keeping with acute intraparenchymal hemorrhage (red arrow). There was an intraventricular hemorrhage extension (blue arrow). (Source: Hospital Universiti Sains Malaysia, 2014).....	34
<b>Figure 4.1</b>	Downsampled demo image of the AAPM TG-18QC test pattern.....	49
<b>Figure 5.1</b>	Age group frequency of the traumatic cases.....	59
<b>Figure 5.2</b>	Traumatic cases cause by percentage.....	59

## LIST OF TABLES

<b>Table 2.1</b>	Imaging classification of traumatic brain injury.....	27
<b>Table 4.1</b>	Cross-tabulation of test result versus gold standard .....	54
<b>Table 4.2</b>	The strength of Kappa agreement .....	56
<b>Table 5.1</b>	Interpretation of CT brain findings set as gold standard.....	60
<b>Table 5.2</b>	Summary of the visual evaluation between workstation and the handheld devices S.....	61
<b>Table 5.3</b>	The Kappa Test agreement between result interpretation by Observer A using handheld device and gold standard.....	63
<b>Table 5.4</b>	The Kappa Test agreement between result interpretation by Observer B using handheld device and gold standard.....	63
<b>Table 5.5</b>	The Kappa Test agreement between result interpretation by Observer A using handheld device and gold standard in detection of subdural hemorrhage .....	64
<b>Table 5.6</b>	The Kappa Test agreement between result interpretation by Observer B using handheld device and gold standard in detection of subdural hemorrhage .....	64
<b>Table 5.7</b>	The Kappa Test agreement between result interpretation by Observer A using handheld device and gold standard in detection of subarachnoid hemorrhage.....	65
<b>Table 5.8</b>	The Kappa Test agreement between result interpretation by Observer B using handheld device and gold standard in detection of subarachnoid hemorrhage.....	65
<b>Table 5.9</b>	The Kappa Test agreement between result interpretation by Observer A using handheld device and gold standard.....	66
<b>Table 5.10</b>	The Kappa Test agreement between result interpretation by Observer B using handheld device and gold standard.....	66
<b>Table 5.11</b>	The Kappa Test agreement between result interpretation by Observer A using handheld device and gold standard.....	67
<b>Table 5.12</b>	The Kappa Test agreement between result interpretation by Observer B using handheld device and gold standard.....	67
<b>Table 5.13</b>	The Kappa Test agreement between result interpretation by Observer A using handheld device and gold standard.....	68
<b>Table 5.14</b>	The Kappa Test agreement between result interpretation by Observer B using handheld device and gold standard.....	68
<b>Table 5.15</b>	The Kappa Test agreement between result interpretation by Observer A using handheld device and gold standard.....	69
<b>Table 5.16</b>	The Kappa Test agreement between result interpretation by Observer B using handheld device and gold standard.....	69

<b>Table 5.17</b>	Summary of Overall Result Agreement between Findings from Observer A and B using Handheld Device Compared to Gold Standard.....	71
<b>Table 5.18</b>	Cross-tabulation of result interpretation by Observer A using handheld device versus gold standard in detection of extradural hemorrhage.....	72
<b>Table 5.19</b>	Cross-tabulation of result interpretation by Observer B using handheld device versus gold standard in detection of extradural hemorrhage.....	73
<b>Table 5.20</b>	Diagnostic accuracy for detection of extradural hemorrhage using handheld device by Observer A and B .....	74
<b>Table 5.21</b>	Cross-tabulation of result interpretation by Observer A using handheld device versus gold standard in detection of subdural hemorrhage.....	75
<b>Table 5.22</b>	Cross-tabulation of result interpretation by Observer B using handheld device versus gold standard in detection of subdural hemorrhage.....	75
<b>Table 5.23</b>	Diagnostic accuracy for detection of subdural hemorrhage using handheld device by Observer A and B versus gold standard.....	77
<b>Table 5.24</b>	Cross-tabulation of result interpretation by observer A using handheld device versus gold standard in detection of subarachnoid hemorrhage .....	78
<b>Table 5.25</b>	Cross-tabulation of result interpretation by observer B using handheld device versus gold standard in detection of subarachnoid hemorrhage .....	78
<b>Table 5.26</b>	Diagnostic accuracy for detection of subarachnoid hemorrhage using handheld device by Observer A and B versus gold standard.....	80
<b>Table 5.27</b>	Cross-tabulation of result interpretation by Observer A using handheld device versus gold standard.....	81
<b>Table 5.28</b>	Cross-tabulation of result interpretation by Observer B using handheld device versus gold standard.....	81
<b>Table 5.29</b>	Diagnostic accuracy for detection of intraparenchymal & contusion hemorrhage using handheld device by Observer A and B versus gold standard .....	83
<b>Table 5.30</b>	Cross-tabulation of result interpretation by Observer A using handheld device versus gold standard.....	84
<b>Table 5.31</b>	Cross-tabulation of result interpretation by Observer B using handheld device versus gold standard.....	84
<b>Table 5.32</b>	Diagnostic accuracy for detection of intraventricular hemorrhage using handheld device by Observer A and B versus gold standard.....	86

<b>Table 5.33</b>	Cross-tabulation of result interpretation by Observer A using handheld device versus gold standard.....	87
<b>Table 5.34</b>	Cross-tabulation of result interpretation by Observer B using handheld device versus gold standard.....	87
<b>Table 5.35</b>	Diagnostic accuracy for detection of skull fracture using handheld device by Observer A and B versus gold standard.....	89
<b>Table 5.36</b>	Cross-tabulation of result interpretation by Observer A using handheld device versus gold standard.....	90
<b>Table 5.37</b>	Cross-tabulation of result interpretation by Observer B using handheld device versus gold standard.....	90
<b>Table 5.38</b>	Diagnostic accuracy for detection of secondary findings using handheld device by Observer A and B versus gold standard.....	92
<b>Table 5.39</b>	Summary of overall diagnostic accuracy for detection of major findings in traumatic non-contrasted computed tomography (CT) brain using handheld device by Observer A and B versus gold standard .....	94



## LIST OF ABBREVIATIONS, SYMBOLS AND ACRONYMS

ART	Algebraic reconstruction technique
CSF	Cerebrospinal fluid
CT	Computed tomography
DICOM	Digital Imaging and Communications in Medicine
DAI	Diffuse axonal injury
EAM	External auditory meatus
ENDEAVOR	Extensible Medical Image Analysis, Visualization, and Annotation Platform
FDA	Food and Drug Administration
FBP	Filtered back reconstruction
HIE	Hypoxic-ischemic encephalopathy
HU	Hounsfield Unit
PACS	Picture archiving and communication system
PDA	Personal digital assistant
SIR	Statistical iterative reconstruction
STP	Standard pressure and temperature
WW	Window width
WL	Window level

## **ABSTRACT**

**Title:** Diagnostic Performance of Android-Based Handheld Device Using Endeavor Mobile Application in Interpretation of a Traumatic Non-Contrasted Computed Tomography (CT) Brain

**Purpose:** To determine the image viewing quality of the handheld device of Android premium devices and investigate the usage of handheld device in interpretation of CT images of trauma cases.

**Materials and methods:** Using Samsung Galaxy Note 10.1, we installed the AAPM TG-18 QC test pattern and recruited 30 candidates to do a subjective review of the QC test pattern on both handheld and workstation monitors. As for the investigation of using handheld device to interpret CT images of trauma cases, we recruited 2 observers, consisting of a radiologist and a final year resident to review 180 cases of CT brain. Their findings would then be cross-referenced to a result obtained by a consultant radiologist using workstation monitor. Kappa test were used to calculate the interobserver agreement.

**Results:** There was 100% reproducibility of the same level of luminance patches, grayscale continuation and spatial resolution in the handheld device when compared to the workstation monitor. Other components investigated produced similar results when the candidates were allowed to zoom in and change the window settings. The sensitivity of detecting lesions on the images using handheld devices ranging from 50.0% to 84.6%. The negative predictive values were generally high indicating that the handheld device has high

accuracy to determine absence of certain lesion. There was substantial agreement regarding the findings of both observer compared to gold standard test on workstation monitor.

**Conclusions:** Current generation of handheld devices has had viewing quality at par with workstation monitor and it is a reliable tool in reviewing CT for trauma cases.

## **ABSTRAK**

**Tajuk:** Prestasi Diagnostik Peranti pegangan tangan Android Berasaskan Penggunaan Aplikasi Endeavor Mudah Alih dalam Tafsiran Tomografi Berkomputer ( CT ) Otak Kes Trauma Tanpa Menggunakan Media Kontras.

**Tujuan:** Untuk menentukan kualiti tontonan imej peranti pegang tangan Android premium dan mengkaji kesan penggunaan peranti pegang tangan dalam mentafsirkan imej CT kes trauma.

**Bahan dan kaedah:** Menggunakan Samsung Galaxy Nota 10.1, kami telah memasang corak ujian AAPM TG - 18 QC dan mengambil 30 calon untuk melakukan kajian subjektif corak ujian QC pada kedua-dua monitor pegang tangan dan stesen kerja. Bagi penyiasatan menggunakan peranti pegang tangan mentafsir imej CT kes trauma, kami merekrut 2 pemerhati, terdiri daripada pakar radiologi dan pemastautin tahun akhir untuk mengkaji sebanyak 180 kes CT otak. Penemuan mereka telah dirujuk-silang dengan penemuan oleh pakar radiologi kanan yang menggunakan monitor stesen kerja. Ujian Kappa juga digunakan untuk mengira persetujuan antara pemerhati-pemerhati tersebut.

**Keputusan:** Terdapat 100 % kebolehulangan yang sama tahap patch luminance, kesinambungan skala kelabu dan resolusi ruang dalam peranti pegang tangan berbanding monitor stesen kerja. Komponen-komponen siasatan menghasilkan keputusan yang sama apabila calon-calon dibenarkan untuk mengezum masuk dan menukar tetapan tetingkap. Sensitiviti dalam

mengesan lesi pada imej-imej dengan menggunakan peranti pegang tangan berada dalam julat 50.0% sehingga 84.6%. Nilai ramalan negatif biasanya tinggi menunjukkan bahawa peranti pegang tangan mempunyai ketepatan yang tinggi untuk menentukan ketiadaan lesi tertentu. Terdapat persetujuan kappa yang besar mengenai penemuan kedua-dua pemerhati berbanding ujian emas piawai pada monitor stesen kerja.

**Konklusi:** Generasi semasa peranti pegang tangan mempunyai kualiti setanding dengan stesen kerja memantau dan ia adalah alatan yang boleh dipercayai untuk membaca CT bagi kes trauma.

# **Chapter One**

## **Introduction**

## **CHAPTER 1**

### **INTRODUCTION**

#### **1.1 Overview on handheld devices in medicine.**

Handheld computers, such as personal digital assistant (PDA), smartphones, and tablets have become a popular devices among the physician in recent years. Recent studies found that more than 80% of physician had and used handheld devices in their daily practice (Horowitz, 2011; Zieger, 2007). Recent compilation of handheld device in emergency radiology by American College of Radiology highlights the usage of handheld devices monitor versus secondary-class monitor showed no statistical significant difference when the interpreters were given sufficient clinical information (American-College-of-Radiology/-American-Roentgen-Ray-Society, 2010).

In addition to informative tools, physicians are also using handheld devices largely to perform tasks such as email, research, and taking surveys (Dolan, 2011). The portability and flexibility offered by these handheld devices has opened many attractive ideas in the field of medicine, including in radiology field. It allows more than image viewing portability by providing clinician with the ability to perform aforementioned task.

The problems and issues of advocating handheld devices in medical application includes screen size, resolution of display, contrast ratio, connectivity, data transfer rate, patient's data security and confidentiality, as well as costs should be considered when introducing a mobile handheld device used for image viewing (R. Toomey, 2010). The current greatest concern is

whether the handheld devices could possibly display radiologic images at diagnostic quality.

Most researchers study the radiologists' performance with handheld devices against workstation monitors. Among the earlier studies, study on diagnostic efficacy of handheld devices for emergency radiologic consultation, using a PDA and an Apple iPod touch concluded that handheld devices showed promise in the field of emergency tele-consultation for detection of basic orthopedic injuries and intracranial hemorrhages (R. J. Toomey et al., 2010). Recent study in 2013, using Apple iPad 1 in the emergency setting demonstrated that a mobile device with appropriate web-based picture archiving and communication (PACS) was effective in detection of intracranial hemorrhage on head CT (Sridhar G Panughpath, Savith Kumar, & Arjun Kalyanpur, 2013). Multiple abstract presented at the Radiological Society of North America (RSNA) annual conference in 2011 also showed that the diagnostic accuracy of radiologist using tablet PCs was no way inferior to the use of desktop workstations.

Following the release of the iPad in 2010 by Apple Inc., much of the researchers' attention has been concentrated on the iPad, as because of it high monitor spatial and contrast resolution, robust battery life and is extremely portable. The display of medical images on an iPad is superior to that of an off-the-shelf workstation displays but below that of the medical grade monitors (Panughpath & Kalyanpur, 2012). The success of iOS devices in the past few years with the brand spearheading the market during the introduction of iPad made it the most popular device for the academicians, physician and trainees.

Our study was based on the study done by Mc Laughlin et al. (2012), in



which the study entitled “The emergency CT brain: preliminary interpretation with a tablet device: image quality and diagnostic performance of the Apple iPad”. The authors found that there was satisfactory identification of acute findings on emergency CT brain examination (Mc Laughlin et al., 2012). The entire study is based on Apple iPad 1.

There are other similar studies that test the diagnostic performance of handheld devices. The results are almost unanimously in agreement that handheld devices have consistently performed well enough to be considered at least promising for use under certain medical imaging circumstances. However, there are significant limitations when it comes to determining whether or not the handheld devices are suitable for radiological reporting or viewing only. This is primarily due to two factors: the expanding range of handheld devices available in the market and massive variety in clinical image and pathology types

No previous study to test the diagnostic performance of Android-based handheld devices in radiology. Recently, our USM Computer Research Vision group has developed an Android-based DICOM image viewer called "ENDEAVOR-MOBILE" application ([www.endeavourmd.com](http://www.endeavourmd.com)). This study was conducted as part of the evaluation of the Endeavour Mobile software in clinical use. The purpose of the study is to determine the diagnostic performance of an Android-base handheld device and Endeavour Mobile application in preliminary interpretation of traumatic CT brain cases.

## **1.2 Rationale of the Study**

CT scan of the brain for traumatic patients has frequently been requested by the emergency physician and performed during off-working hours where the access to radiologist is limited. The remote viewing and preliminary interpretations are crucial in management of emergency head injury. With the use of handheld devices and viewing application will facilitate tele-consultation between radiologist and managing team. Therefore, the evaluation of diagnostic performance the device and software need to be tested before it is accepted for the future clinical use.

# **CHAPTER TWO**

## **LITERATURE REVIEW**

## **CHAPTER 2**

### **LITERATURE REVIEW**

#### **2.1 Previous study comparison**

There were multiple studies comparing radiologist diagnostic accuracy between handheld devices and with workstation monitors. Among the prominent ones were R. J. Toomey et al. (2010), studying the diagnostic efficacy of handheld devices for emergency radiologic consultation, using a PDA and Sridhar G Panugopath et al. (2013), using Apple iPad 1 to study computerized tomography evaluation of intracranial hemorrhages. The authors concluded that handheld devices showed promise in the field of emergency tele-consultation for detection of basic orthopedic injuries and intracranial hemorrhages. Another study done by R. J. Toomey et al. (2010) show that in the emergency setting, a mobile device with appropriate web-based picture archiving and communication (PACS) was effective in detection of intracranial hemorrhage present on head CT.

Bhatia et al. (2013) in his study of the display resolution of the Apple iPad tried to determine if specific CT and MR sequences can be interpreted accurately on mobile device/PACS software platforms when compared to a traditional stationary high-resolution monitor/PACS radiological workstation. The data and statistical analysis demonstrated that portable mobile devices such as the Apple iPad could display adequate resolution of CT and MRI sequences to accurately diagnose acute central nervous system injuries and other non-acute pathology.

At the Radiological Society of North America (RSNA) annual conference 2011, a series of abstracts were presented in an entire session on medical informatics dedicated to Mobile Computing Devices, highlighting the current importance of this topic in medical imaging (Faggioni L, 2011; Fernando Garcia Garcia et al., 2011; Roni Shreter et al., 2011; Sindhu John et al., 2011; Supriya Gupta, Sean Doyle, Samridhi Gupta, et al., 2011; Supriya Gupta, Sean Doyle, Thomas J. Schultz, et al., 2011). The message conveyed clearly in the course of the session was that the diagnostic accuracy of radiologists using tablet PCs was in no way inferior to the use of desktop workstations. This demonstrated that the current development in term of the display quality of handheld devices has reached the standard of a desktop.

## **2.2 Samsung Galaxy Note 10.1 (2014 version)**

The Samsung Galaxy Note 10.1 (2014 edition) is a 10.1-inch Android-based tablet computer produce and marketed by Samsung Electronics. It belonged to the new generation of Samsung Galaxy Note premium tablet series, which also included an 8-inch model and 12-inch model. It was announced on 4th September 2013, and launched worldwide in October 2013. It is the successor to the original Samsung Galaxy Note 10.1.

The Samsung Galaxy Note 10.1 ran a display of 10.1" 2560 x 1600 (WQXGA) thin-film transistor (TFT) ([www.samsung.com](http://www.samsung.com)). It has dimension of 243.1mm x 171.4mm x 7.9mm and weighing 540 grams. The dimension, display and weight of this model are considered to be optimally adjusted that carrying it around feels comfortable even for a long time. It has a good battery

lifespan of 8220 mAh with an estimated runtime of maximum run time of the Note 10.1, with the display on, is 24 hours and 18 minutes (Samsung, 2013).

On average, it measured a brightness of 385.3 cd/m<sup>2</sup>. The maximum was to be found in the center of the panel: 414 cd/m<sup>2</sup>. The brightness was quite similar to that of the Google Nexus 10 (average brightness: 389.2 cd/m<sup>2</sup>). The difference in illumination was also marginal: our test model offers 88% whereas the Nexus 10 offers 87%. These were both acceptable values but they are not setting any new records. Due to the relatively high black value of our test model of 0.84 cd/m<sup>2</sup>, the contrast is 493:1. With the level of contrast, resolution and brightness offered, we estimated this model has more than enough to review CT brain images done in the emergency setting (John, Poh, Lim, & Chan, 2012).



**Figure 2.1** Samsung Galaxy Note 10.1 (2014 edition).

	<b>Samsung Galaxy Note 10.1 (2014)</b>	<b>Samsung Galaxy Note 10.1 (2012)</b>	<b>Google Nexus 10 (2012)</b>	<b>Apple iPad (fourth generation)</b>
Weight in pounds	1.18	1.32	1.33	1.44
Width in inches (landscape)	9.62	10.3	10.4	7.3
Height in inches	6.75	7.1	6.9	9.5
Depth in inches	0.31	0.35	0.35	0.37
Side bezel width in inches (landscape)	0.5	0.9	0.9	0.8

**Figure 2.2** Comparisons of popular tablets in the current market

## **2.3 Operating System**

Tablets, like conventional PCs, run on multiple operating systems. Current four main operating systems were: The iOS, Android, Blackberry OS, and Windows Phone. At the end of Q1 2013, GlobalWebIndex noted that in 2 years time, tablet usage increased by 282 percent, with 156 million Android tablets users and 122 million iPad users making up 75 percent. By the 2013 year-end, Gartner found that 121 million Android tablets, 70 million iOS tablets, and 4 million Windows tablets had been sold to end-user. This proves that Android was a more popular handheld device (Tanous, 2012).

The major players in the tablet market are Android versus Apple. The difference between these two operating system is that Android, which was Linux-based and partly open source, was more personal computer-like than iOS, in that its interface and basic features were generally more customizable from top to bottom. However, iOS uniform design elements were sometimes seen as being more user-friendly (Diffen, 2013).

## **2.4 Android Operating System Advantages**

The single greatest advantage to owning an Android mobile device was its customization. The nature of the Android's open source model was what gives third party app developers the ability to create a wide range of add-on functionalities that extend beyond the OS's intrinsic capabilities (Font, 2014). It also included the ability to side-load or download applications from sources other than the official Google Play market, like the Amazon Appstore, or even direct from app developer websites. Ultimately, this made for a greater number of applications that were available for Android devices.

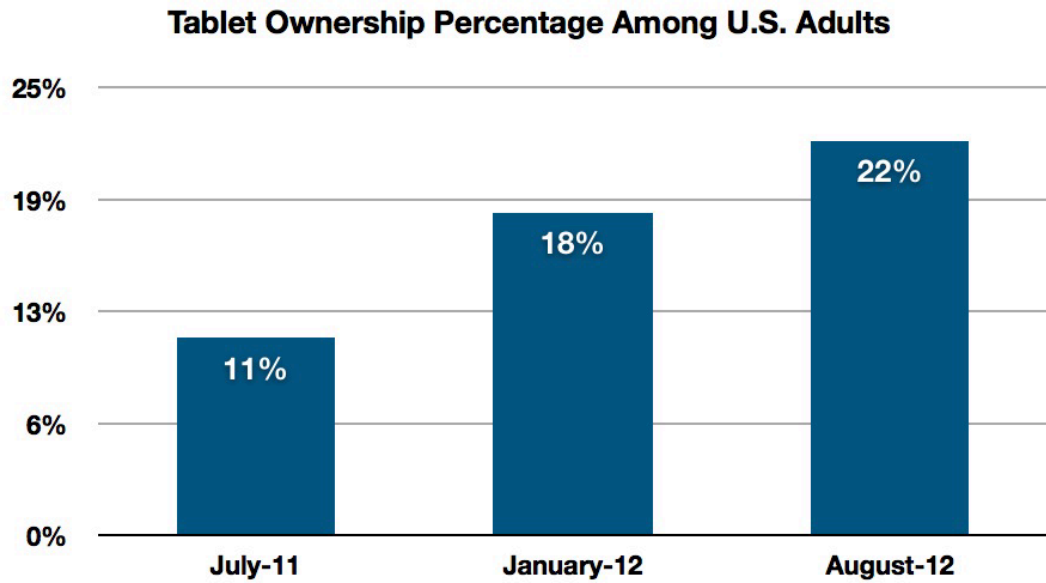


By design, the Android operating system has a file management system similar to PCs and Macs. While owning a smartphone with a highly customizable interface may make Android the obvious choice for gadgeteer, it did have its fair share of drawbacks. Freedom to customize can imbue the device's interface with something of a shattered uniformity that would not appeal to everyone and could be difficult for some users to keep up with.

Because Android was used by a variety of manufacturers like Samsung, HTC and Sony, it became the most widely used operating system (OS) in the world, powering more than a billion of mobile devices. But this did not necessarily mean it was the best. It also did not make it the worst. It just means it was the most often used. And thus this will be the target of our study.

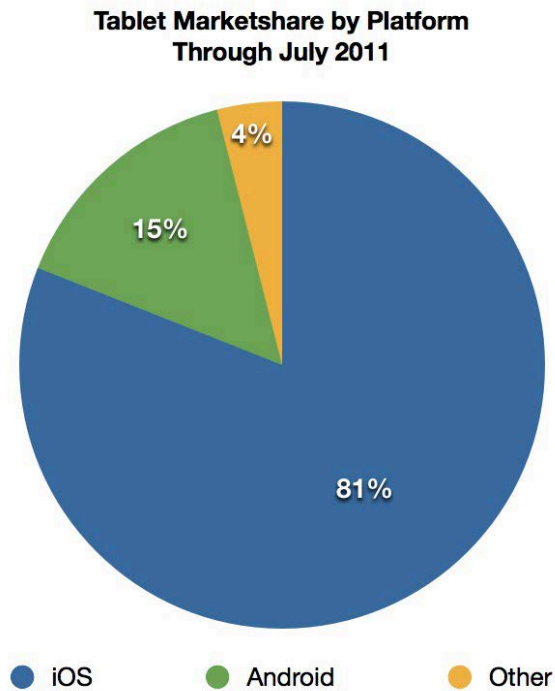
## **2.5 Tablet Ownership among Adults**

Tablets ownership has increased over the year as studied by (Tanous, 2012). It is estimated that the ownership is 22% in United State among the adults by August 2012 and the numbers were climbing. With the large amount of people having the tablets, our study hoped to prove that the tablets are optimal for viewing CT images. The success of the study will pave the way for medical imaging advancement, as many clinicians would find that they could obtain a mobile CT viewing machine with a reasonable price.

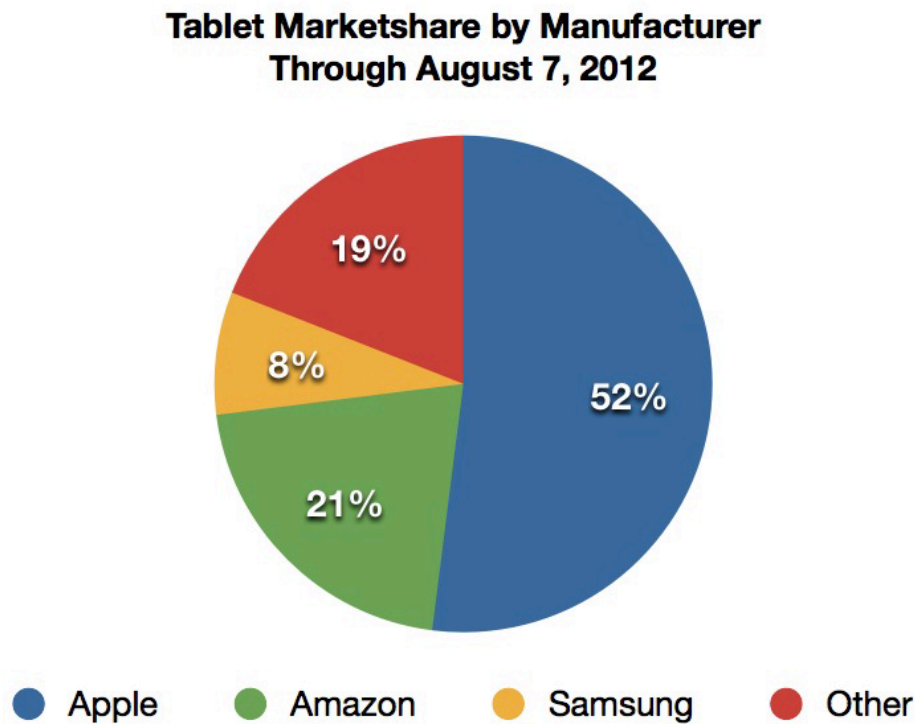


**Figure 2.3** The tablet ownership percentage among United States adults  
(Source: *The Mac Observer* from Pew Research data)

We have chosen Androids operating system as the operating system of choice as it has a commanding lead over all other smart phone operating systems. Android won 81% of smart phone market in 2013. In terms of tablets share of market, the Androids were showing rapid increment with the Androids taking lead in 2014 with 42% of the devices shipped worldwide (Latino-Post, 2013).

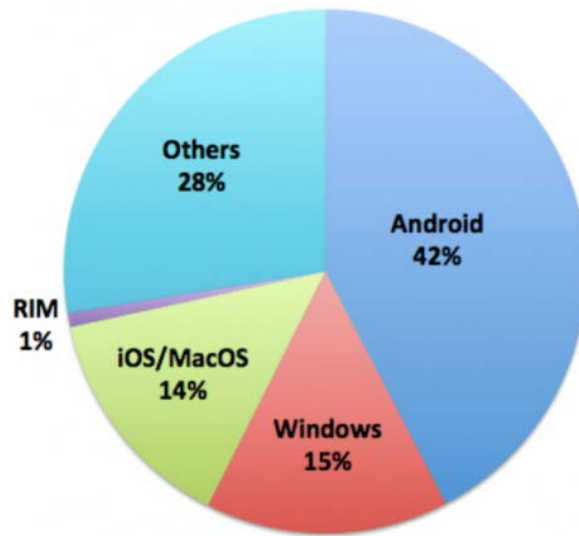


**Figure 2.4** Tablets market share by platform through July 2011 (Source: *The Mac Observer* from Pew Research data)



**Figure 2.5** Tablet market share by manufacturer through August 2012 (Source: *The Mac Observer* from Pew Research data)

Worldwide device shipment by OS 2014 (Gartner)



**Figure 2.6** Worldwide device shipment by operating system in year 2014  
(Source: Gartner IT infrastructure)

A study into most popular mobile devices would unleash a tidal of potentials in the medical field especially in radiology. Although not intended to replace the current workstations for primary diagnosis, it may provide enough information especially in emergency radiological studies and for remote consultation. Increasing the availability of attending CT interpretation in academic centres was a current focus of emergency medical practice, where time was of the essence and triage decisions often depend on CT results. Remote image interpretation remained a primary means of afterhours consultation and interpretation. This has proven in a study of 149 patients by Fernando Garcia Garcia et al. (2011). Supriya Gupta, Sean Doyle, Thomas J. Schultz, et al. (2011) also demonstrates that comparison using handheld device and PACS workstation in terms of pneumothorax produce equal sensitivity results in ICU patients.

## 2.6 Application for Viewing Images

To view a radiological study images on the tablet, an image viewing application that is able to read the DICOM images was needed. A number of DICOM viewers were available from major PACS vendors, but U.S Food and Drug Administration (FDA) have cleared a few of them for diagnostic use with medical images. The first of which was MIM Software's Mobile MIM in 2011 (Pasha et al., 2012).

A study conducted by Rodrigues, Visvanathan, Murchison, and Brady (2013), have shown that there were 321 applications for mobile device, which were subsequently divided into 5 categories as shown in **Figure 2.7**. One hundred fifty-eight were "teaching" and 96 "reference". Three of the 29 DICOM viewing applications had FDA approval for primary diagnosis, while 62 % stated they should not be used for primary diagnosis; 24 % of applications stated named medical professional involvement, 12 % had unnamed medical involvement and 4 % acknowledged guidelines or papers; 42 % did not disclose authorship. A summary of the available viewing software was also given in the study (**Figure 2.8**).

Application store	Teaching	Reference	Viewing software	Patient education	HIS	Other	Total
Apple	91	47	18	1	2	13	172
Google Play	52	35	5	1	3	12	108
Blackberry	3	1	0	0	0	2	6
Nokia	0	0	0	0	0	1	1
Windows	0	1	0	0	0	0	1
Samsung	0	0	0	0	0	0	0
Apple/Google Play	6	7	6	0	0	2	21
Apple/Blackberry/Google Play	6	3	0	0	0	1	10
Blackberry/Google Play	0	2	0	0	0	0	2
Total	158	96	29	2	5	31	321

**Figure 2.7** Number of radiology-related smartphone applications by category available from the different application stores. HIS = Hospital Information System (Source: Rodrigues, Visvanathan, Murchison, and Brady (2013))

Application name	Application store	Developer	Price*	FDA approved	Advertised viewing features	PACS	Advertised limitations	Tablet application available
Centricity Radiology Mobile Access	Apple/ Google Play	GE Healthcare	Free	No	Zoom, pan, scroll, W/L, 2D, 3D, MIP, MPR	GE Centricity PACS	Not for diagnostic use	Yes
DicomDroid	Google Play	Mediko srl	€20.62	No	Not stated	Any PACS	None stated	Yes
DocBookMD	Google Play	DocBookMD	Free	No	Not stated	Any PACS via messaging application	None stated	Yes
Doshi Diag	Apple	My Personal Health Record Express	Free	No	Zoom, scroll, cine loop	Doshi Diagnostics PACS	Not for diagnostic use	No
eFilm Mobile	Apple	Merge Healthcare	Free	No	Zoom, pan, W/L	eFilm PACS	Not for diagnostic use	Yes
ENDEAVOR	Google Play	Computer Vision Research Group	Free	No	Zoom, pan, scroll, W/L, annotate	Any PACS	None stated	Yes
Fujifilm Synapse Mobility	Apple/ Google Play	Fujifilm Medical Systems USA	Free	Yes (for iPhone/ iPad)	Zoom, W/L, 2D, 3D, MIP, MPR	Fujifilm systems PACS	For diagnostic use on iPhone/iPad	Yes
iClarity Lite: Advanced Medical Imaging Viewer and Image Management Tool	Apple	iCRco Inc.	Free	No	Zoom, pan, scroll, W/L, measurement, cine loop	Any PACS	Not for diagnostic use	Yes
iClarity: Advanced Medical Imaging Viewer and Image Management Tool	Apple	iCRco Inc.	€3.54	No	Zoom, pan, scroll, W/L, measure, cine loop	Any PACS	Not for diagnostic use	Yes
Independent	Apple	My Personal Health Record Express	Free	No	Zoom, scroll, cine loop	Independent Imaging's PACS	Not for diagnostic use	Yes
INFINITT Mobile Viewer	Apple/ Google Play	INFINITT Healthcare	Free	No	Zoom, pan, W/L, cine, measure, ROI	INFINITT PACS	Not for diagnostic use	Yes
inteleGRID	Apple	Intelemage	Free	No	Zoom, pan, scroll, W/L	Any PACS	None stated	Yes
IOP Mobile	Apple	ZED Technologies	Free	No	Not stated	Olympic Park PACS	None stated	Yes
iPaxera	Apple	Paxeramed Corp	€3.54	No	Zoom, pan, rotate, W/L, measure	Any PACS	Not for diagnostic use	Yes
MITK Pocket	Apple	Medical Embedded Systems	Free	No	Zoom, MPR, W/L, measure, annotation	Any PACS	None stated	Yes
Mobile MIM	Apple	MIM Software	Free	Yes	2D, 3D, MIP, measure, annotate, SUV	Any PACS	Only to be used when no access to workstations. Not for mammography	Yes
MphRx	Apple	My Personal Health	Free	No	Zoom, scroll, cine loop	Any PACS via MphRx cloud system	Not for diagnostic use	No
MRDS	Google Play	Inrete SRL	Free	No	Not stated	Any PACS	None stated	Yes
OsiriX HD	Apple	Pixmeo SARL	€24.88	No	Zoom, pan, rotate, W/L, cine, measure, ROI	Any PACS	Not for diagnostic use	Yes
ResolutionMD Mobile	Apple/ Google Play	Calgary Scientific	Free	Yes (for iPhone/ iPad)	Zoom, pan, W/L, 2D, 3D, MIP, MPR, measure, cine	ResolutionMD PACS	For diagnostic use on iPhone/iPad. Not for mammography	Yes

**Figure 2.8** Summary of the available “viewing software” smartphone applications. MIP = maximum intensity projection, MPR = multiplanar reformatting, PACS = picture archiving and communication system, ROI = region of interest, SUV = specific uptake value, VRT = volume-rendering technique, W/L = window level (Source: Rodrigues, Visvanathan, Murchison, and Brady (2013))

As a part of the Endeavour Mobile clinical study, we planned to use the Endeavor Mobile application, an Android-based application build by the Computer Vision Research Group of Universiti Sains Malaysia (Universiti-Sains-Malaysia, 2010). Endeavor Mobile stood for Extensible Medical Image Analysis, Visualization, and Annotation Platform, developed by a team of medical specialists, imaging researchers, and software engineers. It was a Java-based software and fully supports the DICOM image format, therefore allows users to load, browse, view and analyze medical images. It was a comprehensive application which has similar function as a standard workstations.

The latest version currently was ENDEAVOR Mobile 3.1.1, featured a friendly user interface and was packed with a range of advanced mobile medical imaging features. It enabled users to retrieve, store and view medical images (CT, PET, MR, X-ray, etc.) on the go via their Android devices. It was basically one of the most advanced DICOM viewers available in the market currently.

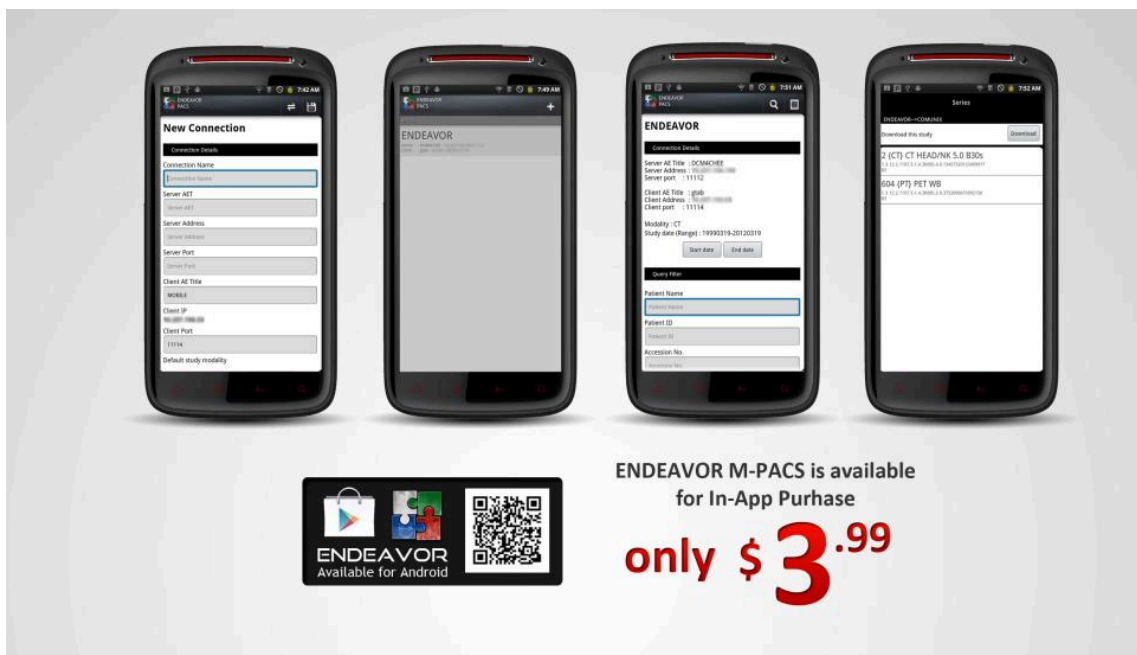ENDEAVOR leverages on the Eclipse™ plug-in architecture that enabled advanced image analysis, segmentation, and visualization algorithms to be added in the form of plug-ins. It was developed with a primary focus for the use in hospitals, clinics and research and educational institutions. Initially it was created to be used in the personal computer and laptops. Subsequently, the developers were able to transfer this app to the mobile Android platform.

Mobile users of ENDEAVOR application has the privilege to access to PACS (Medical Imaging Servers) at any time and from anyplace using an internet connection via WiFi or 3G. Medical practitioners and radiologists



enjoyed the privilege to search and download required medical images immediately into their Android based tablets and smartphones.

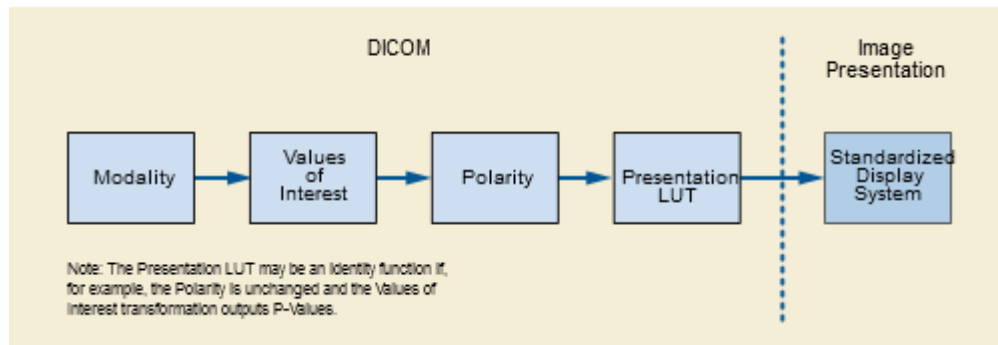
Using our academic institution developed software Endeavor Mobile, we hoped to achieve the best imaging setup for the Android tablets. We hoped to explore the potential of this application in conjunction to our study.



**Figure 2.9** ENDEAVOR 3.1.1 officially on sale in google apps store (Source: Google apps store)

## 2.7 Factors Affecting Image Quality

To understand the suitability of a handheld device display, we have to look back at the DICOM display standards and its working schematic diagram. Schematic ideas of the quality of procedures and equipments that will ultimately decide the image quality were shown in **Figure 2.10**.



**Figure 2.10** Equipments and procedures to be complied with prior approval by DICOM standards (Source: medical.nema.org)

In this study, the modality of interest was CT brain on its ability to detect various types of bleed and cerebral injury. The primary concern of the thesis will rely heavily on the standardized display system of a handheld device.

This field of study has attracted the attention of the research community in recent years. Some studies on the display characteristic of the handheld devices, such as a study done by Asumi Yamazaki et al in 2013 stated that handheld device displays can have good image quality characteristics compared to medical workstations display in terms of spatial resolution, noise and reflectance (Yamazaki, Liu, Cheng, & Badano, 2013).

A note worthy point was that human eyes also play significant interaction with the display quality of a device. Human eye contrast sensitivity was distinctly non-linear with the Luminance Range of the Grayscale Standard Display Function ([www.medical.nema.org](http://www.medical.nema.org)). Basically, human eyes were relatively less sensitive to the dark areas of an image than to the bright areas of an image. This variation in sensitivity made it much easier to see small relative changes in luminance in the bright areas of the image than in the dark areas of the image.

## **2.8 CT Brain Protocol**

The American Association of Physicists in Medicine (AAPM) ([www.aapm.org](http://www.aapm.org)) recommended that for all head studies, it was very important for image quality to position the patient in the center of the scan field (AAPM, 2012). The lateral laser beam was used to make sure that the patient was positioned in the center.

Patient lying in supine position, arms resting along the body, the head secured in the head holder and the lower legs supported. In order to optimize image quality versus radiation dose, scans were provided within a maximum scan field of 300 mm with respect to the isocenter. No recon job with a field of view exceeding those limits will be possible. Therefore, patient positioning has to be performed accurately to ensure a centered location of the skull.

In HUSM CT scan machine, the gantry tilt was only available for sequence scanning, not for spiral scanning. Gantry tilt was also not available for dual source scanners. A topogram was done in lateral position with 120 kV and 50 mA with the scanning in craniocaudal direction.

<b>SIEMENS</b>	<b>Sensation 64</b>	<b>Definition (dual source, 64 slices)</b>	<b>Definition AS (128 slices)</b>	<b>Definition Flash (dual source, 128 slices)</b>
Software version	VB30	VA34	VA27	VA34
Scan mode	Spiral	Spiral	Spiral	Spiral
kV	120	120	120	120
Quality reference mAs*	380	390	410	390
Rotation time (s)	1.0	1.0	1.0	1.0
Detector Configuration (Acquisition/ Collimation) (mm)	64 x 0.6	64 x 0.6	128 x 0.6	128 x 0.6
Pitch	0.85	0.55	0.55	0.55
Dose modulation	CARE Dose	CARE Dose	CARE Dose	CARE Dose
CTDI-vol (mGy)	59.7	59.3	58.9	59.6
<b>Reconstruction 1</b>				
Recon Start	Top of Frontal Sinus	Top of Frontal Sinus	Top of Frontal Sinus	Top of Frontal Sinus
Recon End	Vertex	Vertex	Vertex	Vertex
Kernel	H31s	H31s	H31s	H31s
Slice (mm)	5.0	5.0	5.0	5.0
Position increment (mm)	5.0	5.0	5.0	5.0

**Figure 2.11** Comparison of CT scan protocols among different models of SIEMENS CT scanner based on AAPM recommendation. Our HUSM model is Definition AS+ 128-slice (Source: [www.healthcare.siemens.com](http://www.healthcare.siemens.com))

## 2.9 Anatomy of the Brain

The brain was one of the largest and most complex organs in the human body. It was made up of more than 100 billion nerves that communicate in trillions of connection called synapses. The brain was made up of many specialized areas like the cortex, brain stem, basal ganglia, and cerebellum. A layer of tissue called meninges surrounded the brain. It consisted of 3 layers from the outer most to inner; dura mater, arachnoid mater, and pia mater.

The cortex was divided into several lobes; frontal, parietal, temporal and occipital lobes. The entire cerebrum was composed of two layers. The 20-millimeter thick outermost layer, called the cerebral cortex (or gray matter), contains the centers of cognition and personality and the coordination of complicated movements. As shall be seen, the gray matter was also organized

for different functions. The white matter was a network of fibres that enabled regions of the brain to communicate with each other.

The cerebellum, the second largest area, was responsible for maintaining balance and further control of movement and coordination. The brain stem was the final pathway between cerebral structures and the spinal cord. It was responsible for a variety of automatic functions, such as control of respiration, heart rate, and blood pressure, wakefulness, arousal and attention (Saul, 1998).