

**STUDY ON OUTCOME OF GASTROCNEMIUS
RECESSION SURGERY IN DIABETIC EQUINUS
CONTRACTURE**

By

DR NARINDER SINGH GILL

**THESIS SUBMITTED IN PARTIAL FULFILLMENT OF THE
REQUIREMENTS FOR THE DEGREE**

of

MASTERS OF MEDICINE

(ORTHOPAEDIC SURGERY)



2014

ACKNOWLEDGEMENT

I am thankful to God, whose guidance and glory point me to the rightful path. He led me to always do well in my career and I am always grateful for that.

I am forever indebted to my parents Mr. Joginder Singh and Madam Belbir Kaur whom no replacement can substitute their kindness and care, their enthusiasm and prayers, their patience and love in perpetuating and upholding virtues especially to me.

My heartfelt gratitude to my beloved wife, Dr Kathy Tan Gill whose endurance and patience provided me the inner strength and motivation to always look forward in spite any challenges faced.

My pleasant appreciation to the mentor, supervisor and guide, Dr Emil Fazliq and Dr Mohana Rao, whose wisdom, knowledge and understanding are always beyond my grasp, yet they are ever ready to share and impart their insights and good judgments.

I would also like to thank to our Head of Department Assoc. Prof Imran for providing the help and guidance in doing this thesis.

Lastly, my sincere gratitude to my supervisors and specialists in Hospital Pulau Pinang as well as my fellow colleagues and all the patients who willingly participated in this study.

TABLE OF CONTENTS

| | |
|------------------------------|------|
| ACKNOWLEDGEMENT | ii |
| TABLE OF CONTENTS | iii |
| LIST OF FIGURES | iv |
| LIST OF PLATES | v |
| LIST OF TABLES | vi |
| ABSTRACT | vii |
| ABSTRAK | viii |
| 1. INTRODUCTION | 1 |
| 2. LITRATURE REVIEWS | 4 |
| 3. MATERIALS AND METHODS | 27 |
| 4. RESULTS AND DATA ANALYSIS | 34 |
| 5. DISCUSSION | 48 |
| 6. CONCLUSION | 56 |
| 7. STUDY LIMITATIONS | 57 |
| 8. REFERENCES | 58 |
| APPENDICES | 61 |

LIST OF FIGURES

- 1. Figure 1: The organization of Achilles tendon structure from collagen fibrils**
- 2. Figure 2: Flow chart for this study**
- 3. Figure 3: Frequency of patients based on age groups**
- 4. Figure 4: Pie chart showing sex distribution of this study**
- 5. Figure 5: Frequency of patients based on ethnicity**
- 6. Figure 6: Frequency of patients based on duration of diabetes mellitus**
- 7. Figure 7: Showing the frequency of degree of improvement of ankle dorsiflexion**

LIST OF PLATES

- 1. Plate 1: Posterior view of the gastrocnemius muscle comprising of its lateral and medial head.**
- 2. Plate 2: Soleus muscle seen here after the gastrocnemius muscle is detached from its origin**
- 3. Plate 3: The technique of measuring ankle range of motion using a goniometer.**
- 4. Plate 4: Evaluation of the ankle joint dorsiflexion with the knee in full extension**
- 5. Plate 5. Evaluation of the ankle joint dorsiflexion with the knee in full extension**
- 6. Plate 6. (A) A mini–open gastrocnemius recession performed using a pediatric speculum. (B) The use of an open gastrocnemius recession for the treatment of equinus.**
- 7. Plate7: Showing preoperative marking for the Modified Strayer Technique**
- 8. Plate 8: Patient is put in prone position for the operative procedure**
- 9. Plate 9: Post-operative improvement in dorsiflexion is noted and measured**

LIST OF TABLES

- 1. Table 1: Pre and post-operative ankle dorsiflexion results**
- 2. Table 2: Normality of both pre-operative and post-operative ankle dorsiflexion**
- 3. Table 3: Paired t test between pre-operative and post-operative ankle dorsiflexion**
- 4. Table 4: Presents the results of the multiple regression of the model.**
- 5. Table 5: MANOVA test for ethnicity**
- 6. Table 6: MANOVA test for sex**
- 7. Table 7: Pearson Correlation Table**

ABSTRACT

TITLE: STUDY ON OUTCOME OF GASTROCNEMIUS RECESSIION SURGERY IN DIABETIC EQUINUS CONTRACTURE

BACKGROUND: Diabetic equinus secondary to gastrocnemius contracture is a known predominant risk factor in diabetic foot ulceration characterized by reduction of ankle dorsiflexion. Recessiion surgery involves release of the gastrocnemius muscle at its aponeurosis and is one of the treatments of choice in improvement of diabetic equinus contracture.

OBJECTIVE: To measure degree of improvement of ankle dorsiflexion and length gained at gastrocnemius aponeurosis following gastrocnemius recessiion surgery in diabetic equinus contracture. To assess correlation between the lengths gained at gastrocnemius aponeurosis with degrees of improvement in ankle dorsiflexion following surgery.

METHODOLOGY: Total of 76 patients was recruited in the Orthopaedic clinics and wards at Penang General Hospital. Presence of gastrocnemius equinus was established with a positive Silfverskiold test. Gastrocnemius recessiion surgery using the Modified Strayer Technique was done following failed conservative therapy. Pre and post-operative ankle dorsiflexion was measured. Length gained at gastrocnemius aponeurosis was measured at 6 weeks post-operative using Ultrasound done in maximal ankle dorsiflexion. Results were analyzed using SPSS version 20.0

RESULTS: The severity of equinus contracture did not correlate to chronicity of diabetes mellitus. There was improvement of ankle dorsiflexion seen at 6 weeks post-operatively. It ranged from 6 to 16 degrees and was coupled with statistical significant length gained at

gastrocnemius aponeurosis that ranged from a mean of 0.8cm to 3.8cm. Mean improvement of ankle dorsiflexion was 11.05 degrees. Mean improvement of length gain at gastrocnemius aponeurosis was 1.54cm.

CONCLUSION: Gastrocnemius recession surgery appropriately addresses diabetic equinus secondary to gastrocnemius contractures by improving ankle dorsiflexion and is evidenced by a significant increase in length at the aponeurosis.

ABSTRAK

TAJUK : KAJIAN TENTANG PEMBEDAHAN PEMANJANGAN OTOT GASTROCNEMIUS UNTUK PENYAKIT KONTRAKSI EKUINUS DI KALANGAN PESAKIT DIABETES

LATAR BELAKANG: Penyakit kontraksi ekuinus adalah faktor risiko utama dikenali pada kaki pesakit diabetes yang dicirikan oleh pengurangan dorsifleksi sendi buku lali. Pembedahan melibatkan pemanjangan otot gastrocnemius pada aponeurosis merupakan salah satu rawatan pilihan dalam pengurangan kontraksi ekuinus di kalangan pesakit diabetes

OBJEKTIF: Untuk mengukur tahap penambahbaikan dorsifleksi pergelangan kaki dan panjang yang diperolehi pada aponeurosis gastrocnemius berikutan pembedahan untuk kontraksi equinus diabetes. Menilai hubungan antara panjang yang diperolehi pada aponeurosis otot gastrocnemius dengan darjah penambahbaikan kepada sendi buku lali dorsifleksi berikutan pembedahan.

KAEDAH: Sejumlah 76 pesakit yang telah dirawat di wad dan klinik Otopedik Hospital Pulau Pinang telah dikenal pasti melalui pemeriksaan Silfverskiold. Pembedahan otot gastrocnemius yang menggunakan teknik Strayer dilakukan berikutan kegagalan terapi yang konservatif. Dorsifleksi sebelum dan selepas pembedahan telah diukur. Panjang yang diperolehi pada gastrocnemius aponeurosis adalah diukur pada 6 minggu selepas pembedahan menggunakan Ultrasound dilakukan ketika sendi buku lali pada maksima dorsifleksi. Keputusan dianalisis menggunakan SPSS versi 20.0

Keputusan: Kadar keterukan kontraksi sendi buku lali tidak berkait dengan tempoh pesakit menghidap penyakit diabetes. Terbukti ada peningkatan dorsifleksi sendi buku lali yang berjulat

dari 6-16 derajat yang ditambah pula dengan pemanjangan yang diperoleh pada gastrocnemius aponeurosis dari 0.8cm 3.8cm yang signifikan dari segi statistik.

Kesimpulan: Pembedahan pemotongan otot gastrocnemius dapat memperbaiki dorsifleksi buku lali dan ini dibuktikan oleh peningkatan ketara dalam panjang pada aponeurosis itu.

1. INTRODUCTION

The global prevalence of diabetes mellitus has doubled from 100 million to 200 million patients for the past decade (King H et al 2010). The diabetic epidemic affects up to 16 to 18 % of the Malaysian population and out of this 25% of patients suffer from diabetic foot complications during their lifetime (Mustaffa BE 2004).

The hallmark of pathology in diabetes mellitus is longstanding hyperglycemia, which has been linked to increased protein glycation and concomitant generation of free radicals (Dickinson, Carrington et al. 2002). The excess free radicals have been postulated to create oxidative stress leading to increased low-density lipoprotein oxidation, glycation of collagen in extracellular matrix, decreased nerve conduction velocity and decreased endoneural blood flow, thus predisposing the patient to neuropathy, atherosclerosis and increased tissue stiffness. This pathology manifests clinically in the musculoskeletal system as muscle weakness, loss of sensation, loss of range of motion and increased joint stiffness. The triumvirate of neuropathy, stiffness and repetitive loading complete a casual chain that may eventually culminate in plantar ulceration (Stokes, Faris et al.1975; Cavanagh, Simoneau et al. 1993; Birke, Patout et al. 2000; McPoil, Yamada et al.).

The loss of flexibility in the Achilles tendon has been an underappreciated cause for plantar foot ulceration in diabetics. Traditionally, lengthening of the gastrocnemius aponeurosis has been used to treat spastic conditions and the procedure has been studied extensively in the pediatric orthopedic literature. Because of the loss of Achilles tendon flexibility, the foot gradually loses

its ability to dorsiflex during gait and placing abnormal forces on the midfoot and these pressures in the neuropathic patient can lead to ulceration. This forms part of wide spectrum known limited joint mobility syndrome (LJMS). Diabetic ankle equinus is part of this spectrum. This equinus contracture is a predominant cause of diabetic foot ulceration. The incidence of developing this equinus contracture is almost 3 fold as compared to normal population with 10.3% of diabetics having equinus contracture, an estimate of 15 per 10000(Robert Frykberg et al 2012).

The surgical treatment to equinus is well documented in the literature and mainly focuses on two different procedures, the tendo-Achilles lengthening (TAL) or gastrocnemius recession. The TAL approach most surgeons commonly utilize is the Hoke triple hemisection. This procedure is not without potential complications such as under-lengthening or, much worse, over-lengthening.

The gastrocnemius recession surgery is well documented in the literature. It has shown to increase ankle dorsiflexion to 18 degrees (Sharrard et al 2001). This study compared gastrocnemius recession to TAL for release of equinus contracture in cerebral palsy.

Gastrocnemius recession provided added advantages such as lower rate of recurrence, no bulbous scarring and lower risk of Achilles tendon rupture.

Study on the role of gastrocnemius recession surgery in diabetic equinus contracture is lacking.

The normal norm of poor wound healing in diabetic patients has made surgical procedures like this to shy away from the hands of surgeons worried with the guarded prognosis and outcome.

Therefore the present study is done with the aim to investigate correlation between gastrocnemius recession surgeries with the improvement of the ankle equinus and also to

evaluate to quantitative length gained at the gastrocnemius aponeurosis measured via ultrasonography.

2. LITRATURE REVIEWS

2.1 The Achilles Tendon

2.1.1 Gross Anatomy

The Achilles tendon is the conjoined tendon of the two heads of the gastrocnemius and the soleus muscle. Together these structures are often referred to as the “gastroc-soleus complex.” It is the largest and strongest tendon in the human body and subject to tensile forces of up to 12.5 times body weight (9 kilonewton [kN]) during sprinting and six to eight times body weight during athletic activity such as jumping or cycling.

The gastrocnemius muscle crosses the knee, ankle, and subtalar joint; hence, it is maximally stretched with the knee fully extended and the ankle dorsiflexed while the heel is inverted.

Consisting mainly of fast twitch muscle fibers, the gastrocnemius muscle flexes the knee, plantar flexes the ankle, and inverts the subtalar joint. It is the most superficial muscle in the calf and is responsible for its contour. The two heads of the gastrocnemius muscle are firmly attached to the posterior aspect of the femur, just proximal to the femoral condyles, by strong, flat tendons that expand into a short aponeurosis on the posterior surface of the muscle bellies. Both heads also attach to the posterior aspect of the knee joint capsule onto the oblique popliteal ligament. The medial, larger head takes its origin slightly superior to the lateral head and extends more distal in the calf. Deep to the medial head is usually a bursa that often communicates with the knee joint. In 10% to 30% of the population, there is a sesamoid bone (fabella) in the proximal tendon of the lateral head of the gastrocnemius that often directly articulates with the lateral femoral condyle.

The muscle fibers from each head run obliquely and attach at an angle in the middle of the calf into a midline raphe that further distal broadens into an aponeurosis on the anterior surface of the muscle. This aponeurosis gradually narrows and unites with the tendon of the soleus to form the Achilles tendon. The gastrocnemius is innervated by the first and second sacral roots through the tibial nerve.

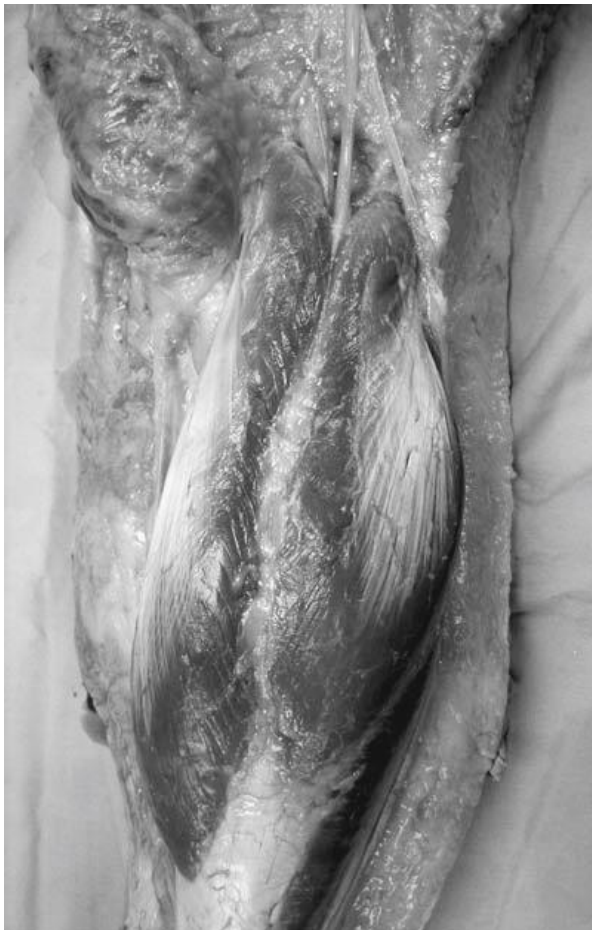

Plate 1: Posterior view of the gastrocnemius muscle comprising of its lateral and medial head. (Adopted from Surgical Reconstruction of Foot and Ankle, Thomas Zgonis)

The soleus is a postural muscle consisting mainly of slow-twitch muscle fibers. It helps to keep the body upright in stance and prevents the body from falling forward during gait, as it contracts

when the center of gravity passes in front of the knee joint. It is the strongest muscle in the lower leg and the prime plantar flexor of the ankle joint. The soleus has its origin on the posterior surface of the fibula head and the proximal 25% of the posterior surface of the fibula as well as the middle third of the posteromedial border of the tibia. Some fibers arise from the fibrous arch between the tibial and fibular origins of the muscle. The soleus is a pennate muscle. It is wider than the gastrocnemius and consists of an anterior and a posterior aponeurosis with the bulk of the muscle fibers in between. The muscle architecture is nonuniform with variable fiber lengths between 16 and 45 mm. The muscle fibers extend more distally than those of the gastrocnemius and insert into the posterior aponeurosis, which lies directly anterior to the aponeurosis of the gastrocnemius. The two aponeurotic leafs of the soleus lie parallel for a variable distance before they join in the distal lower leg prior to uniting with the tendon of the gastrocnemius to form the Achilles tendon.

The contribution of fibers of the gastrocnemius and soleus to the Achilles tendon is variable. In most individuals, the soleus contributes more fibers than the gastrocnemius (Cummins et al 2011). At the gastroc-soleus junction, the Achilles tendon is broad and flat. As it travels distally in the leg, it becomes progressively ovoid in cross section, to a level 4 cm proximal to its insertion, where it can become relatively flatter again. During their descent, the fibers of the Achilles tendon internally rotate to a variable degree (approximately 90 degrees) in a spiral manner, so that the initially posterior fibers of the soleus insert mainly on the medial aspect of the Achilles tendon footprint, whereas those of the gastrocnemius (initially anterior) insert laterally. The extent of fiber rotation is determined by the position of fusion between the

two muscles, with a more distal fusion resulting in more rotation. This rotation makes elongation and elastic recoil within the tendon possible and allows the release of stored energy during the appropriate phase of gait. This stored energy allows the generation of higher shortening velocities and greater instantaneous muscle power than could be achieved by contraction of the gastrocnemius and soleus muscles alone. Fiber rotation reaches a maximum 2 to 5 cm proximal to the tendon insertion and creates high stresses in this area of the tendon, which may explain the poor vascularity and susceptibility to degeneration and injury in this region.



Plate 2: Soleus muscle seen here after the gastrocnemius muscle is detached from its origin(Adopted from Surgical Reconstruction of Foot and Ankle, Thomas Zgonis)

2.1.2 Microstructure

The diameter of collagen fibrils in the Achilles tendon varies from 30 nm to 150 nm. The basic unit of a tendon, the collagen fiber, is created by the binding of multiple collagen fibrils. Each collagen fiber is surrounded by a fine sheath of connective tissue, the endotenon, which allows the fiber groups to glide and provides access channels for blood vessels, nerves, and lymphatics to the deep portions of the tendon. Moreover, the endotenon binds fibers together to form primary fiber bundles (subfascicles), which then group to form secondary fiber bundles or fascicles. A group of secondary bundles then forms the tertiary bundle, with an average diameter of 1000 to 3000 μm through incorporation in a proteoglycan-rich extracellular matrix.

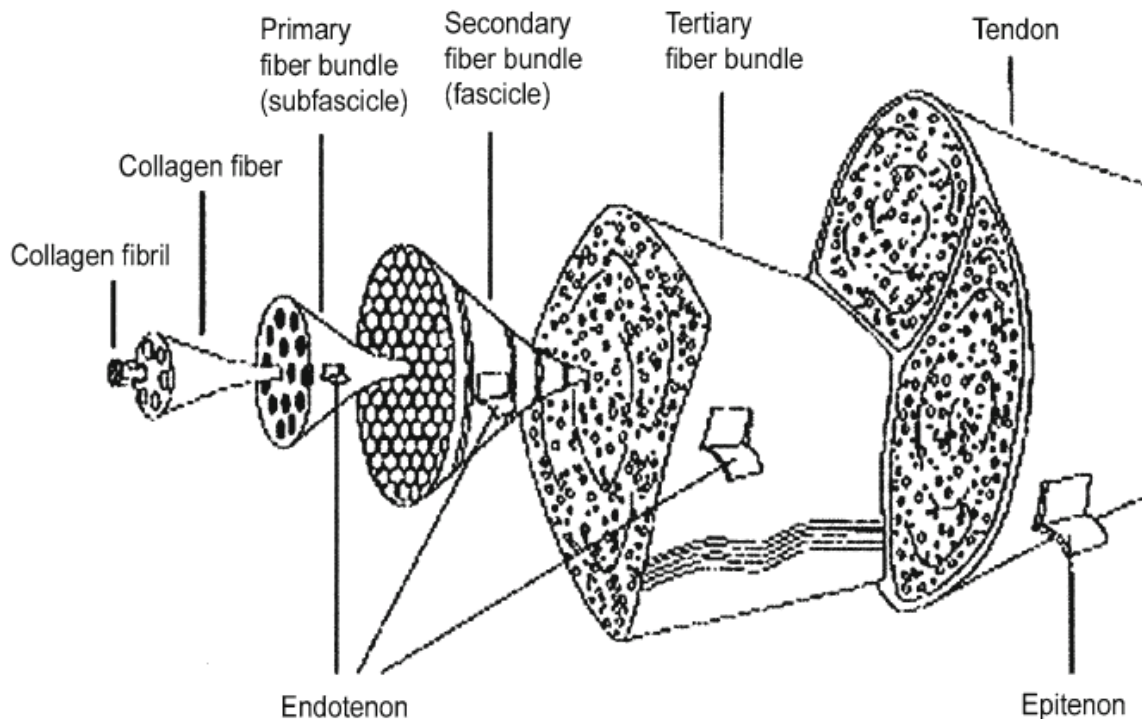


Figure 1: The organization of Achilles tendon structure from collagen fibrils (Adopted from The Tendon Achilles, R Frykberg 2012)

2.1.3 Effect of Diabetes on the Achilles Tendon

In 1997, Grant and colleagues examined the effects of diabetes on the Achilles tendon. They took Achilles tendon samples from 12 patients with diabetes and five non-diabetic patients with foot pathology undergoing foot surgery. Researchers subsequently examined these specimens under an electron microscope.

The findings showed the patients with diabetes had increased packing density of collagen fibrils, decreases in fibrillar diameter and abnormal fibril morphology. The researchers theorized that the cause of these findings is non-enzymatic glycation over many years. This glycation process produced free radicals that caused the morphological change that resulted in shortening of the tendon. In the non-diabetic patients, the fine structure of the Achilles tendon remained normal. These changes in the patients with diabetes lead to extreme shortening of the gastro-soleal complex.

These findings were further concurred by a recent study where the gastro-soleas complex was noted to be shorter in diabetics (Lavery, Amstrong , Boulton 2002). They noted that this shortening resulted in development of an equinus contracture. Their findings showed the equinus group had peak plantar pressures in the forefoot that were three times higher in the forefoot in comparison to the non-equinus group.

2.2 Diabetic Equinus Contracture

2.2.1 Ankle Equinus

The inability to achieve normal ankle dorsiflexion is known as equinus. The definition of equinus ranges from -10 degrees to + 22 degrees in the literature with +10 degrees as a consensus of 13 different studies. In 1975, Sgarlato first described the definition as +10 degrees with the subtalar joint in neutral position and the midtarsal joint locked. In 2002, DiGiovanni and co-workers examined ankle joint dorsiflexion in symptomatic patients and a control group, and the reliability of testing. The ankle joint dorsiflexion with the knee extended averaged 4.5 degrees in the symptomatic group and 13.1 degrees in the control group.

The percentage of symptomatic patients with less than 5 degrees dorsiflexion was 65 percent and was 24 percent in the control group. The percentage of symptomatic patients with less than 10 degrees dorsiflexion was 88 percent and 44 percent in the control group respectively. In regard to patients with less than 5 degrees of dorsiflexion, the study authors confirmed the correct diagnosis with an equinometer in 76 percent of the symptomatic group and 94 percent of the control group. For those with less than 10 degrees of dorsiflexion, researchers confirmed the correct diagnosis with the equinometer in 88 percent of the symptomatic group and 79 percent of the control group respectively.

Normal range of motion in the ankle is measured by placing a person supine with their knees extended (straight) and force is applied to the forefoot, moving the toes and forefoot towards the knee. This motion at the ankle is called dorsiflexion. To measure the range of motion, an imaginary line is drawn down the lateral (outside) side of the leg and foot. Range of motion is

considered normal when the patient to be able to reach a 90 degree angle between the two lines plus an additional 10 degrees.

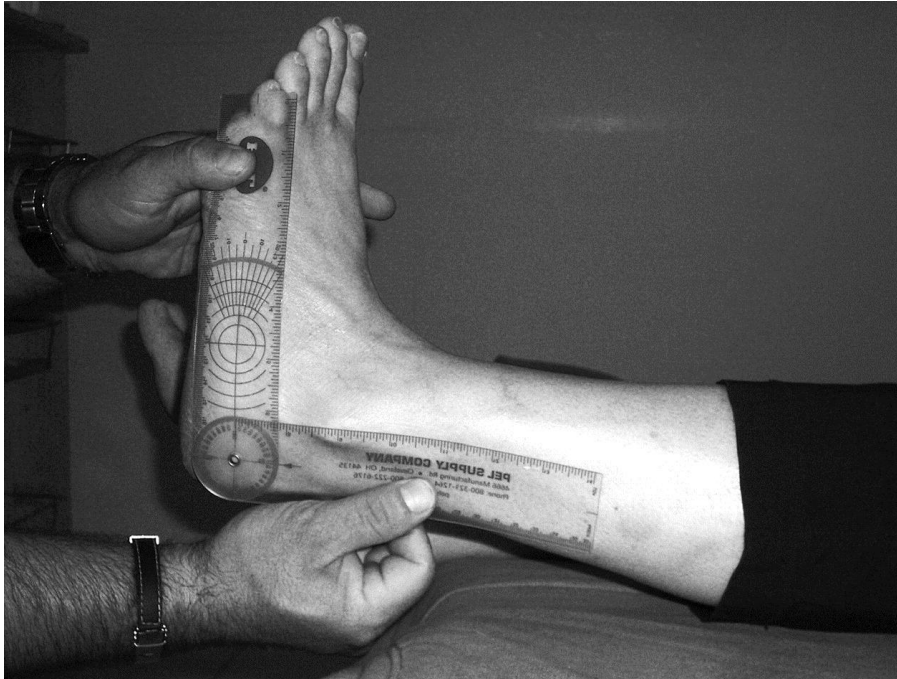

Plate 3: The technique of measuring ankle range of motion using a goniometer. (Adopted from Surgical Reconstruction of Foot and Ankle, Thomas Zgonis)

Therefore, it becomes clear with the results of this study that isolated gastrocnemius contracture (IGC) is an equinus in which there is normal ankle dorsiflexion with the knee flexed however there is less than a 5° (DiGiovanni, 2002) or 10° (DiDomenico, 2005) of dorsiflexion with the knee fully extended. The inability to achieve normal dorsiflexion during the stance phase of gait can result in early heel rise and may be associated with elevated fore-foot pressure (Hill, 1995); which may provide insight into why decreased ankle dorsiflexion range of motion is associated with numerous foot pathologies (DiGiovanni et al, 2002).

2.2.2 Types of Ankle Equinus

There are two primary types of equinus—muscular and osseous, with subgroups of each kind. In the muscular group there can be either spastic or non-spastic equinus. Either of these subgroups of spastic or nonspastic equinus can further be broken down into gastrocnemius or gastrosoleus equinus. The osseous forms of equinus include: anterior tibiotalar exostosis (best seen on a lateral view on X-ray), distal tibiofibular osseous bridging from prior trauma, pseudoequinus and combined equinus. Pseudoequinus occurs in the cavus foot structure where ankle joint dorsiflexion occurs to dorsiflex the forefoot, which is plantar flexed to the rearfoot. The ankle dorsiflexion used to do this then limits the amount available for normal ambulation, therefore the term pseudoequinus. The combined equinus is just a combination of one type of muscular and osseous equinus.

2.2.3 Clinical Evaluation of Ankle Equinus

Evaluation of equinus clinically is one of the primary stumbling blocks between professions that inhibit effective communication. The Silfverskiöld test is what is used to determine the type of equinus. In this examination, the subtalar is placed in neutral position and the midtarsal joint is locked by supination of the forefoot. The ankle is dorsiflexed maximally with the knee in full extension and then checked with the knee in flexion. If the ankle joint dorsiflexes greater than 90° with both the knee extended and flexed, there is no equinus. If the ankle joint dorsiflexes greater than 90° with the knee flexed by less than 90° with the knee extended, the result is gastrocnemius equinus. If the ankle dorsiflexion is less than 90° with both the knee

flexed and extended, then it can either be gastroc-soleus equinus or osseous equinus. This is determined by the quality of the end range-of-motion and with a charger dorsiflexion stress lateral ankle x-ray. A soft end range of-motion is more likely a gastrocsoleus equinus, especially if no anterior ankle impingement is noted on the x-ray.

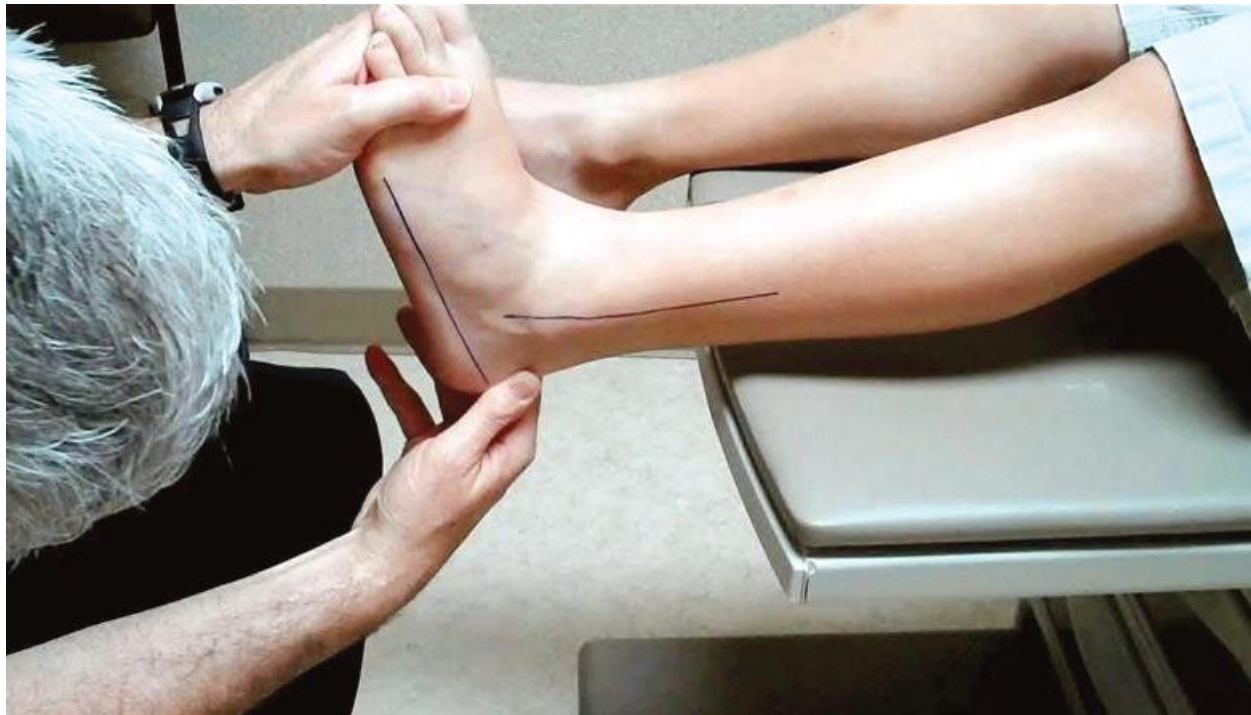

Plate 4: Evaluation of the ankle joint dorsiflexion with the knee in full extension (Adopted from McGlamry's Comprehensive Textbook of Foot and Ankle Surgery)

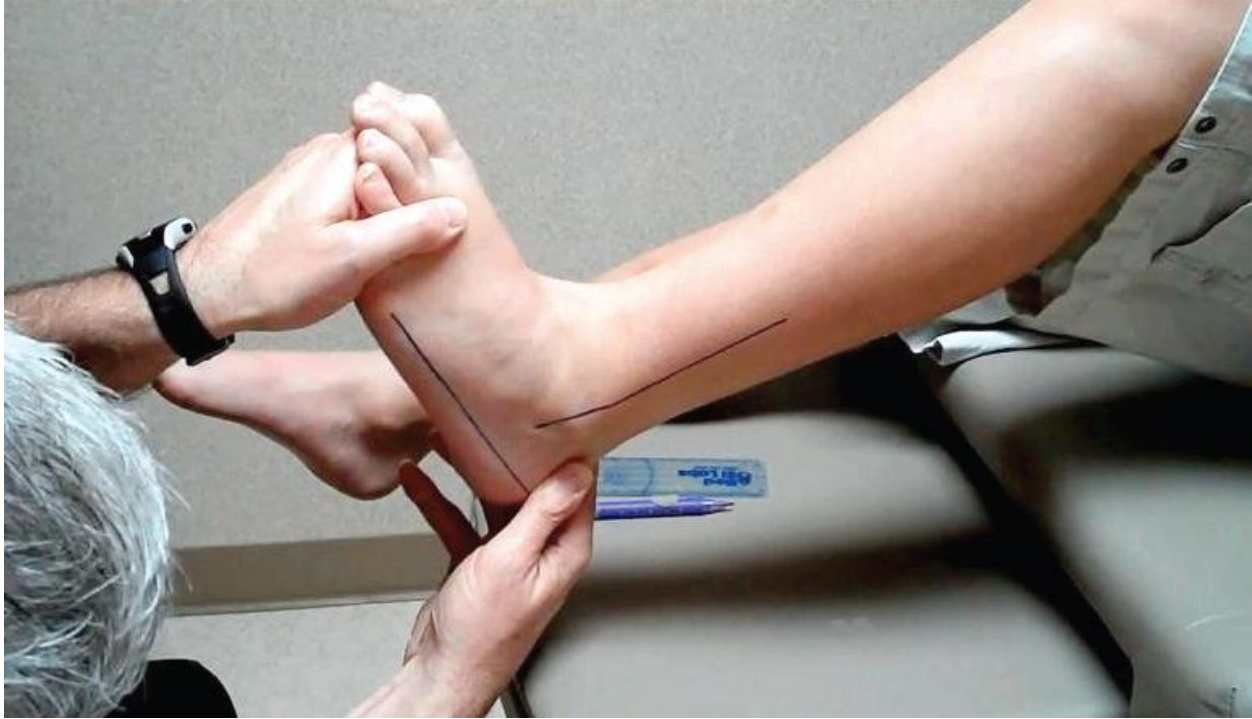

Plate 5: Evaluation of the ankle joint dorsiflexion with the knee flexed (Adopted from McGlamry's Comprehensive Textbook of Foot and Ankle Surgery)

2.2.4 Pathomechanics of Ankle Equinus

The center of pressure is about 6 cm anterior to the ankle, roughly over the dorsal 2nd metatarsal-cuneiform joint. This would make us fall forward in normal standing, but that reaction is negated by the pull of the plantarflexors. The triceps surae has been documented to be the primary plantarflexor of the ankle joint and therefore offsets the anteriorly displaced center of pressure. It has further been demonstrated with equinus that the center of pressure moves about 3 cm distally and 3 mm laterally to the ankle joint. With equinus deformity the center of pressure moves distal and lateral further away from the subtalar joint axis as shown on the right drawing.

The important concept lies in the relation of the subtalar axis to the center of pressure and the subtalar axis to the insertion of the Achilles tendon. The Achilles tendon inserts medially to the subtalar axis and its distance from the axis is about the same as the laterally placed center of pressure to the subtalar axis in a foot with a normal subtalar axis and no equinus. The medial position of the Achilles creates a supinatory moment, while the lateral center of pressure due to ground reactive forces (GRF) creates a pronatory moment. These two cancel each other out, providing a rectus foot structure. When equinus is present, the distal and lateral positioning of the center of pressure in relation to the subtalar axis creates an increased pronatory effect on the foot due to GRF, which is not offset by the supinatory effect of the Achilles tendon. When the subtalar joint axis is more medially deviated, such as in a pronated foot, this further distances the center of pressure from the subtalar axis, causing even more pronatory deformity due to GRF. The opposite occurs in the supinated foot, where the subtalar joint axis is more laterally deviated to the point where even the center of pressure is on the subtalar axis, medial to the subtalar axis or just lateral to the subtalar axis. This puts both the Achilles and center of pressure in supinatory moments (or at least is a lesser pronatory moment than the supinatory moment of the Achilles tendon) due to GRF—therefore making a cavus foot worse over a period of time due to increased rearfoot varus, peroneal pathology, and subtalar instability.

Johnson and Christensen examined the effects of equinus on first ray pathomechanics using cadaver weight-bearing models in their landmark series on first ray pathomechanics. Sensors were applied to each of the individual bones making up the medial column of the foot. Loading of the Achilles tendon was applied and then three-dimensional data were recorded for each segment of the medial column. The results showed plantarflexion of the talus and navicular, and

dorsiflexion of the medial cuneiform and 1st metatarsal occurring through the naviculacuneiform joint. This occurs due to dampening of the effect of the peroneal longus tendon eversion of the medial cuneiform that leads to locking of the midtarsal joint. This lack of midtarsal joint locking leads to the above described medial column instability. This study showed that the effect of equinus is not a stretching of the plantar ligaments over a period of time that leads to first ray instability but, in fact, is a dampening of the peroneus longus function that leads to first ray hypermobility.

Sgarlato described three types of compensation for equinus. The uncompensated equinus deformity manifests itself as a toe walker due to lack of ankle joint dorsiflexion and/or MTJ pronation to get the heel down to the ground. This accounts for about only 1% of equinus cases. In the partially compensated equinus deformity, the heel is on the ground but the tibia does not achieve 10 degrees of flexion to the ground. This results in an early heel-off gait pattern. When the equinus deformity is fully compensated, the result is the severely pronated, hypermobile foot with heel contact to ground and the tibia achieving more than 10 degrees of flexion to the ground. Heel-off in the fully compensated equinus deformity is normal.

2.2.5 Ankle Equinus and the Diabetic Foot

Frykberg and colleagues found that persons with diabetes have a higher prevalence of ankle equinus as compared to non-diabetic persons (37.2% vs 15.3%). The researchers also uncovered a significant association between equinus and ulceration. The reported overall prevalence of equinus in the diabetic population is 10.3%, however, recently Frykberg and colleagues reported

a prevalence of 37.2% in persons with diabetes. Using electron microscopy, Grant and colleagues found structural changes in the Achilles tendons of patients with diabetes, characterized by increased density of collagen fibrils, decreased fibrillar diameter, abnormal fibril morphology, and frequent foci of collagenous fiber disorganization. These fine morphologic changes may be the result of nonenzymatic glycosylation, which, as a result, stiffens the Achilles tendon. As the Achilles loses its flexibility, the foot loses its ability to adequately dorsiflex during gait, creating a longer lever arm and placing abnormal forces on the midfoot. Decreased ankle dorsiflexion results in shifts in distribution of plantar pressures with peak pressures increased under the forefoot. Patients with equinus have significantly higher peak plantar pressures than those without the deformity and are at nearly 3 times greater risk for presenting with increased plantar pressures. Simulated Achilles tendon contracture increases the severity of arch depression and forefoot abduction. Caselli and colleagues showed an increase in forefoot-to-rearfoot pressure with increasing degrees of neuropathy. This finding lends further evidence for the concept that equinus is a progressive deformity and becomes more severe in the later stages of peripheral neuropathy, thereby playing an important role in the cause of diabetic foot ulceration. LEMS involves more than just an equinus deformity. Orendruff and colleagues showed that the relationship between equinus and peak forefoot pressure was significant but, by itself, has only a limited role in causing high forefoot pressure. The soft tissue imbalance that occurs in LEMS is also a major factor in increasing plantar pressures.

Abboud and colleagues found abnormalities in the tibialis anterior muscle function during the gait cycle in subjects with diabetic peripheral neuropathy. This condition resulted in a prolonged

flattening of the foot and a significant increase in plantar pressures. Therefore, understanding the relationship and balancing of the dorsiflexory and plantarflexory muscle groups is important when addressing increased plantar pressure. Attention must also be given to the balance of forces in the foot after certain partial foot amputations. An Achilles tendon lengthening or a gastrocnemius recession should be performed in conjunction with partial foot amputations at, or proximal to, a transmetatarsal amputation.

2.3 Treatment for Diabetic Equinus Contracture

The advent of modern technologies and deep research has led to many surgical options to treatment of diabetic equinus contracture ranging from open procedures to minimally invasive endoscopic surgeries. Despite all these options the role of conservative management still has its importance. It should be the first line before contemplating surgery.

2.3.1 Non-Operative Treatment

Historically contact cast which has been mainstay in Charcot foot treatment had the potential to stretch the triceps surae. But this led to many complications like compliance and foul smelling discharges made contact cast not very favorable. The births of dynamic splints have improved the equinus contractures in diabetic patients. Angel Lopez and colleagues studied the role of dynamic splints in diabetic equinus contracture. They concluded the use of the dynamic splints bilateral, dynamic tension has proven effective in this study achieving a mean 9° increase in maximal, active range of motion in one month. This treatment method of dynamic splinting as a home therapy should be considered before surgery is implemented to reduce ankle equinus

contracture. In addition, awareness by the physician of these potential damaging equinus factors would suggest early and immediate use of the device for prophylaxis. The normal prescription of this system is six months. A future experiment measuring changes from six month duration in a randomized, controlled trial would prove the efficacy of this modality.

2.3.2 Operative Treatment

When considering surgical correction of equinus, several factors must be considered during procedure selection. Distinguishing which portion of the triceps surae complex is contracted may assist in determining which procedure will be most effective. Traditionally, the Silfverskiold test (the amount of dorsiflexion is evaluated with the knee straight and bent) has been used as a major decision maker in surgical planning, but this assumption may be flawed. Schweinberger and Roukis suggested that there is no clinically significant difference between an isolated gastrocnemius equinus and a gastrocnemius-soleus equinus because the timing of passive ankle joint dorsiflexion in the gait cycle only occurs with the knee in an extended position until the heel comes off the ground during toe-off. Aronow and colleagues performed a mechanical loading study using 10 fresh frozen cadaveric legs that were loaded with 35.8 kg (79 lb) of plantar force through the isolated gastrocnemius, isolated soleus, or combined gastrocnemius-soleus muscles and found similar redistribution of plantar force from the rearfoot to the midfoot and forefoot in each of the 3 muscle sets tested.

Kay and colleagues performed a retrospective review of 54 ambulatory children with fixed ankle equinus treated with either TAL or gastrocnemius recession. Their study garnered information for procedure selection to help improve future outcomes. The gait laboratory was used to identify

patients who would benefit from a procedure to correct ankle equinus; however, procedure selection was not made from this information. Procedure selection was based on static examination of dorsiflexion at the ankle with the knee flexed. The gastrocnemius recession was performed in patients who could dorsiflex to neutral and beyond, whereas the TAL was reserved for patients who were unable to achieve dorsiflexion to neutral. Using this test to determine procedure selection produced an end result with no significant difference in postoperative dorsiflexion, whereas after surgery there was significance.

The surgeon must assess ankle equinus when addressing complex foot and ankle deformities. Addressing the equinus deformity is often necessary when performing a midfoot arthrodesis to align the foot and may serve to unload stress on the midfoot. For hindfoot and ankle fusion procedures, it is imperative to check ankle range of motion and consider lengthening because a lengthening may be required to reposition the hindfoot anatomically. Several factors should be considered when selecting the proper surgical procedure. Three surgical options exist, including gastrocnemius recession, TAL, and Achilles tenotomy. Each option carries its own risks and benefits, and performing the appropriate procedure enhances the outcome.

Gastrocnemius Recession

Vulpus and Stoffel introduced the gastrocnemius recession in 1913, transecting the gastrocnemius aponeurosis with a chevron cut and incising the deep fibers of the soleus. Several surgical variations have been described since. Silfveskiold released the gastrocnemius from its origin on the femoral condyles and repositioned the muscle below the knee. Strayer performed a transverse sectioning of the gastrocnemius aponeurosis where it attached to the underlying soleus aponeurosis. Baker modified the Vulpus procedure and described a tongue-and-groove

recession. Lamm and colleagues describe a technique similar to Vulpius, but modified the technique by making a single transverse cut, rather than a single cut or multiple chevron cuts. Endoscopic procedures have emerged as an alternative to the open technique. Surgeons have also targeted the gastrocnemius aponeurosis of the muscular bound portion. Baumann described multiple transections for cases of cerebral palsy (CP). Blitz and Rush performed a single transection of this muscular bound aponeurosis through a small medial incision, and titled the procedure the gastrocnemius intramuscular aponeurotic recession (GIAR). Based on cadaver study, Blitz and Eliot further modified the aponeurotic transection to mirror the angle of the underlying gastrocnemius musculature. Hamilton and colleagues were the first to report the use of a gastrocnemius recession for the management of diabetic foot ulcer. The procedure was used in combination with more traditional procedures, such as a peroneus longus to brevis transfer, and resection of the second to fifth metatarsal heads.

This comprehensive approach led to a 100% healing rate of plantar foot ulceration. Dayer and Assal reported a 96% healing rate with the use of a Strayer gastrocnemius recession, performed in conjunction with a Jones tenosuspension, a flexor hallucis longus transfer from the distal phalanx to the proximal phalanx, and a peroneus longus to brevis transfer. Recently, Greenhagen and colleagues were the first to report the use of an isolated gastrocnemius recession to address neuropathic forefoot ulceration. The gastrocnemius recession is indicated for mild to moderate ankle equinus and has several advantages compared with the more commonly performed TAL. First, by lengthening only the gastrocnemius and leaving the soleus intact, the procedure offers a more controlled lengthening, thereby decreasing the risk of over lengthening and rupture of the Achilles tendon. Second, the gastrocnemius recession maintains plantar flexory strength by

preserving the underlying soleus muscle and preserves the integrity of the Achilles tendon near its insertion onto the calcaneus. This procedure spares a potentially pathologic tendon, because there may be a preexisting Achilles tendinopathy present. The consequence of further weakening a diseased tendon could exacerbate the degradation and lead to rupture. Third, the surgical site for the gastrocnemius recession surgical site has the advantage of increased vascularity to both the tendon and the skin compared with that of the TAL. Naito and Ogata showed that 65% of the blood supply to the tendon arises from the musculotendinous junction and the osteotendinous insertional zone. The risk of inadequate or compromised vascular supply increases with distance farther distal from the surgical site on the lower extremity. In cases of CP, the gastrocnemius recession has been shown to improve calf spasticity, whereas TAL has not. Also of interest in patients with CP, although both TAL and gastrocnemius recession increase push-off power after surgery, only the gastrocnemius recession group has been shown to be significant. The advantage of the gastrocnemius recession (controlled, limited lengthening) is also potentially a disadvantage.

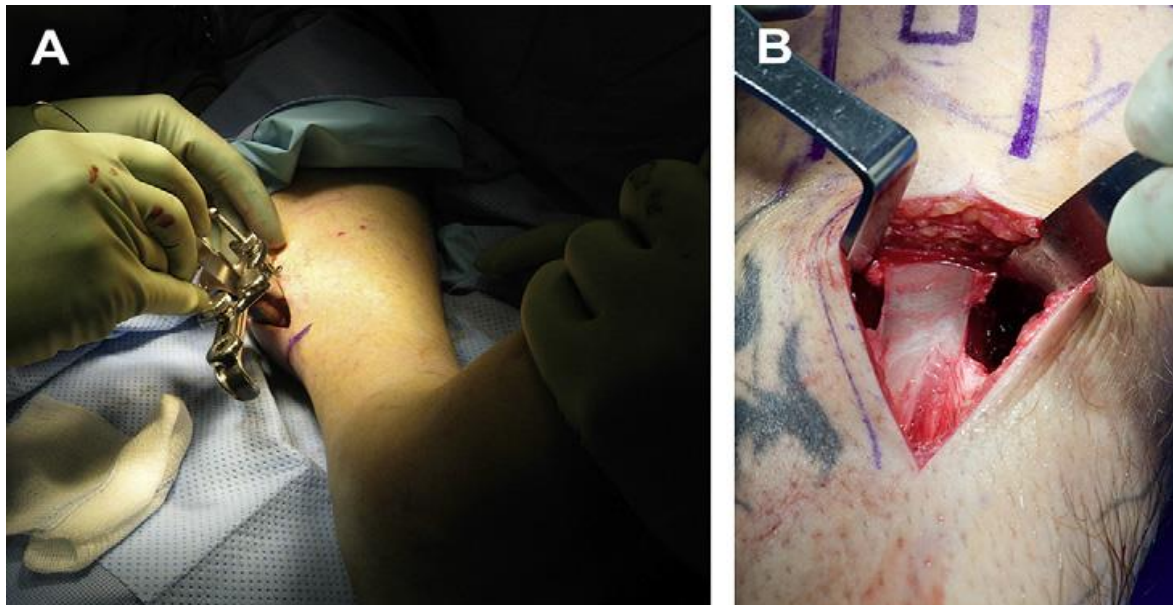


Plate 6. (A) A mini–open gastrocnemius recession performed using a pediatric speculum.

(B) The use of an open gastrocnemius recession for the treatment of equinus. (Adopted from Gastrocnemius Recession vs Tendon Achilles Lengthening R. Greenhagen 2013)

Consequently, the achieved lengthening may be inadequate to restore ankle motion to the proper level. In addition, the recurrence rate of equinus is 3 times that of the TAL, and the gastrocnemius recession carries a 16% recurrence rate of late plantar forefoot re-ulceration, which may require a repeat procedure. Rush and colleagues evaluated the morbidity associated with the open gastrocnemius recession and found an overall complication rate of 6% after performing 150 procedures. Complications included scar tissue formation, nerve-related disorders including complex regional pain syndrome, and wound dehiscence with and without cellulitis. They noted that failure to repair the paratenon at closure resulted in a poorer outcome for scarring and induration after surgery, and therefore recommended a layered closure with the procedure. Their reported incidence of nerve-related problems in performing open procedures was favorable compared with those found in performing the procedure endoscopically (7%).

Tendon Achilles Lengthening

This option is indicated when there is a combined gastrocnemius-soleus complex contracture resulting in moderate to severe equinus deformity. The lengthening may be performed through an open incision, but is often performed through percutaneous incisions to minimize wound complications.

This technique is advantageous in patients who have peripheral arterial disease. Yosipovitch and Sheskin were the first to report the use of Achilles tendon lengthening to decrease forefoot pressure as a treatment of forefoot ulcerations in leprosy. Armstrong and colleagues studied forefoot pressures via electronic force plate before and after TAL. Mean forefoot pressure decreased from 86 N/cm² to 63 N/cm². Furthermore, mean dorsiflexion of the ankle joint increased from 0 to 9 degrees at 8 weeks after surgery. Salsich and colleagues also found that the TAL resulted in an increase in ankle dorsiflexion. More importantly, they showed a temporary reduction in concentric plantar flexor peak torque and passive torque at 0 degrees of dorsiflexion. Therefore, TAL addresses the muscle imbalance between the active dorsiflexory and plantarflexory muscle groups.

Mueller and colleagues conducted a randomized control trial comparing the combined treatment of total contact cast (TCC) and percutaneous TAL with a TCC alone. Initial healing rates were similar in both groups (88% in the group receiving the TCC alone, and 100% in the TAL and TCC group). However, significant difference was noted when comparing the ulcer recurrence rates after 2 years (81% ulcer recurrence rate in the group treated with a TCC alone compared with 38% in those treated with TCC and TAL). This study shows the importance of addressing the underlying equinus deformity to augment healing and to reduce the risk of ulcer recurrence.

Risks are associated with the TAL, such as overlengthening, tendon rupture, and loss of plantar flexory muscle strength. The amount of lengthening is not easily controlled and overlengthening can result in a calcaneal gait and, in patients with an insensate heel, this can result in ulceration. The resultant heel ulceration is difficult to heal and may require a sophisticated flap to achieve closure; if not responsive, this may result in a below-knee amputation. Mohsen Allam found