SOFT TISSUE ANALYSIS OF MALAY ORTHODONTIC PATIENTS

DR. YAHYA HAMDAN YAHYA ALFARRA

UNIVERSITI SAINS MALAYSIA

2017

Soft Tissue Analysis of Malay Orthodontic Patients

By

Dr. Yahya H. Y. Alfarra

Supervisor: Dr. Khoirulzariah Ismail

Co-Supervisor: Dr. Anis Farhan Kamaruddin

A thesis Submitted In Partial Fulfilments Of The

Requirement For The Degree of

Master Of Science (Oral Science)

UNIVERSITI SAINS MALAYSIA
August 2017

بسم الله الرحمن الرحيم

" رَبِّ أَوْزِعْنِي أَنْ أَشْكُرَ نِعْمَتَكَ الَّتِي أَنْعَمْتَ عَلَيَّ وَعَلَى وَالِدَيَّ وَأَنْ أَعْمَلَ صَالِحًا تَرْضَاهُ وَأَدْخِلْنِي بِرَحْمَتِكَ فِي عِبَادِكَ الصَّالِحِينَ"

صدق الله العظيم

(سورة النمل الآية 19)

ACKNOWLEDGEMENTS

Bismillahirrahmannirrahim.

In the name of Allah, The Most Merciful, The Most Compassionate. Peace be upon my beloved Prophet Muhammad saw. May the blessings of Allah always be with him, family and friends.

Alhamdulilah walaillahaillah walahuaakbar. With His blessing I managed to conduct and finished my study with completion of research dissertation. This study is carried out as a partial fulfilment for the degree of Master of Science in Oral Science, Advanced Medical and Dental Institute, University Sains Malaysia (USM).

First and foremost, I want to acknowledge for those individuals who have contributed in many ways throughout my journey in the entire study and producing this valuable dissertation.

I want to express my upmost and deepest gratitude to following kind-hearted individuals.

- Dr. Khoirulzariah Ismail as supervisor and orthodontist who helped tremendously with constant guidance and encouragement. Thank you for your knowledge, great help, extreme patience, valuable guidance, and immeasurable support, will always be sincerely remembered.
- Dr. Anis Farhan Kamaruddin as co-supervisor and orthodontist, who helped me with endless guidance, valuable advice, devoted effort, and unique cooperation, will always be deeply remembered.

- Dr. Husniyati Bt Roslan and Dr. Siti Noor Fazliah Binti Mohd Noor, lecturer, Advanced Medical and Dental Institute, USM who provided good guidance.
- Mr. Nizuwan Bin Azman, Advanced Medical and Dental Institute, USM who provided consultation on statistic for interpretation part of the study.
- Dr. Rohayu Hami, lecturer, Advanced Medical and Dental Institute, USM who provided consultation on statistic for interpretation part of the study.
- Advanced Medical and Dental Institute, USM, for the financial support as grant for conducting this study.
- Human Research Ethics Committee (HREC), USM for giving me approval for conducting this study.
- AMDI Orthodontic Dental Clinic, USM for giving an amazing cooperation for data collection in this study.
- Mrs. Wan Linda Suryanti Bt Wan Abdullah Sani AMDI Librarian, USM for giving an amazing cooperation for data collection in this study.
- Special thanks to all lecturers and staff in AMDI, USM who involved in all lectures and practical throughout of the whole semesters from beginning until the end of this study.
- Last but not least, all my colleagues who keep on reminding me and unconditional support to complete this study.
- Lastly, my sincere thanks to my family for their moral support in pursuit of my goals; my father Hamdan Alfarra for his support and patience; My mother Walaa Alfarra who is far away from me but always near in my heart through her moral support and my sisters for their continuous support.

TABLES OF CONTENTS

CHAPTER 3 - MATERIALS AND METHODS

LIST OF TABLES

LIST OF FIGURES

LIST OF ABBREVIATIONS

AMDI	Advanced Medical and Dental Institute
Cm	Columella point
3D	Three Dimensional
FH	Frankfort Horizontal
G	Glabella
Gn'	Soft tissue Gnathion
HP	Horizontal Plane
HREC	Human Research Ethics Centre
+1L	Labial outline of upper incisor
Li	Labrale inferius
Ls	Labrale superius
Me	Menton
N	Nasion
N'	Soft tissue Nasion
Or	Orbitale
Pn	Pronasale
Pog	Pogonion

Pog'	Soft tissue Pogonion
Po	Porion
PS	Power and Sample Size program
S	Sella turcica
SD	Standard Deviation
Si	Mentolabial sulcus
Sn	Subnasale
SPSS	Statistical Package for the Social Sciences
Stms	Stomion superius
Stm	Stomion inferius
VTO	Visualized Treatment Objective

LIST OF APPENDICES

ABSTRAK

Pengetahuan corak normal dentofasial dan tisu lembut yang melapisi cenderung untuk meningkatkan kejayaan rawatan dan mewujudkan keharmonian muka yang optimum. Penilaian analisis tisu lembut adalah penting dalam merancang rawatan ortodontik individu kerana tisu lembut adalah faktor utama dalam menentukan profil akhir muka pesakit. Analisis rangka sahaja dianggap sebagai penunjuk yang kurang sesuai bagi perancangan rawatan ortodontik. Suatu perancangan rawatan yang lengkap untuk pesakit yang memerlukan rawatan ortodontik harus merangkumi kedua-dua analisis sefalometrik tisu keras dan tisu lembut analisis sefalometrik. Analisis tisu lembut Holdaway telah disesuaikan dalam kebanyakan kajian sefalometrik untuk memahami ciri-ciri tisu lembut dalam populasi atau etnik yang berlainan. Pewujudan analisis Holdaway dalam kalangan pesakit Melayu akan lebih membantu pemahaman kita terhadap profil tisu lembut pesakit Melayu. Satu kajian tinjauan rekod retrospektif telah dijalankan menggunakan 62 sefalogram lateral pesakit dewasa wanita Melayu berumur 18 hingga 40 tahun yang menghadiri Klinik Pakar Ortodontik, Institut Perubatan dan Pergigian, Universiti Sains Malaysia untuk menentukan signifikasi sefalometrik tisu lembut dalam merancang rawatan ortodontik menggunakan analisis Holdaway. Analisis ukuran-ukuran tisu lembut menggunakan analisis Holdaway telah dijalankan menggunakan perisian surihan sefalometrik. Sebelas parameter tisu lembut Holdaway telah dinilai dan dibandingkan dengan norma parameter tisu lembut Holdaway dan perbezaan-perbezaan tisu lembut telah dinilai berdasarkan ukuran corak rangka pesakit.

Hasilnya mencadangkan bahawa, ukuran tisu lembut untuk wanita Melayu tidak sama dengan norma Holdaway kecuali untuk sudut muka tisu lembut dan kelengkungan bibir atas dan hidung, sementara ukuran lain lebih besar daripada purata Holdaway.

Sampel wanita Melayu mempunyai profil tisu muka yang lebih cembung, dan juga sulkus superior dan inferior yang lebih dalam, dan tisu lembut dagu yang lebih tebal daripada nilai-nilai purata Holdaway. Kajian lanjut dengan saiz sampel yang lebih besar bagi penduduk yang sama perlu dijalankan.

ABSTRACT

Knowledge of the normal dentofacial pattern and its overlaying soft tissue tend to improve treatment success and establish optimal facial harmony. The assessment of soft tissue analysis is essential in planning individual orthodontic treatment, because the soft tissues are a major factor in determining a patient's final facial profile. Skeletal analysis alone is considered a poor indicator of orthodontic treatment planning. A complete treatment planning for patients who require orthodontic should include both hard and soft tissue cephalometric analysis. Holdaway soft tissue analysis has been adapted in most cephalometric studies to understand soft tissue characteristic in different population or ethnicities. The establishment of Holdaway analysis among Malay patient would further aid our understanding on Malay patient's soft tissue profile. A retrospective record review study was conducted using 62 Malay female adult patients aged 18 to 40 who attended Orthodontic Specialist Clinic, Advanced Medical and Dental Institute, Universiti Sains Malaysia to determine soft tissue cephalometric significance in orthodontic treatment planning using Holdaway analysis. Analysis of soft tissue measurements using Holdaway analysis were carried out using a special computer software program. Eleven Holdaway soft tissue characteristics were determined, in order to evaluate the differences in the soft tissue values of Malay female adult patients comparing to Holdaway soft tissue parameters norms and to assess the soft tissues differences based on patient's skeletal pattern measurement.

The results suggested that, the soft tissue measurements for females Malay were not similar to the Holdaway norms except for the soft tissue facial angle

and upper lip curvature and nose prominence, while the other measurements were larger than the Holdaway averages. The Malay female sample had more convexity soft tissue facial profile, as well as deeper superior and inferior sulci, and thicker soft tissue chins than the Holdaway values. Further studies with larger sample size for same population should be conducted.

CHAPTER 1

INTRODUCTION

1. Background of the study

In orthodontics, much attention has been devoted to facial esthetics, balance and harmony. It is presumed that a well-proportioned and balanced soft tissue contours denotes a well-defined underlying dental and skeletal structures (Jacobson, 1995).

Knowledge of the facial skeleton and its overlaying soft tissue in determining facial harmony is essential. It was assumed that the soft tissue profile configuration was primarily related to the underlying skeletal configuration. Several investigators have noted that soft tissue behaves independently from the underlying skeleton because the soft tissue covering the teeth and the skeletal face is highly variable in its thickness (Turley, 2015). Many researchers have appeared that soft tissues are a major factor in determining a patient's final facial profile. The successful treatment planning for patients who require orthodontic should involve both hard and soft tissue cephalometric analysis.

The importance of soft tissue and facial esthetics relations in orthodontic treatment was emphasized by Angle as early as 1907. He pointed out that the soft tissues were an important factor in facial harmony.

Study conducted by Holdaway (1983) found that the treatment goals were much improved when soft tissue features were considered during treatment planning. Furthermore, the soft tissue profile analysis plays an important role in evaluating the external facial appearance and can reflect the outcome that perceived by an observer.

Several researchers set out to quantitatively assess which soft tissue relationships might contribute to or detract from facial harmony and esthetics and to explain how this information could be used in orthodontic treatment planning (Merrifield, 1966).

Legan & Burstone (1980) and Holdaway (1984) helped in developing soft-tissue analysis that gained wide acceptance in clinical and research work in both orthodontics and orthognathic surgery.

Knowledge of the normal dentofacial pattern and its overlying soft tissue aids in the improvement of treatment success and to establish optimal facial harmony. A complete treatment planning for patients who need orthodontic should include both soft and hard tissue cephalometric analysis. This has led to the introduction of importance of soft tissue analysis in orthodontic treatment.

2. Problem statement

Holdaway soft tissue analysis has been adapted in most cephalometric studies to understand soft tissue characteristic in different population or ethnicities. However, there is no established Holdaway analysis amongst Malay patients that can be used to understand the Malay patient's soft tissue profile.

3. Objective

3.1 General objective

To evaluate soft tissue characteristic from lateral cephalogram of Malay patients using Holdaway soft tissue analysis.

3.2 Specific objectives.

1. To qualitatively describe the soft tissue features of Malay patients from lateral cephalogram using Holdaway analysis.
2. To compare the relationship between the soft tissue findings and the patients' respective skeletal patterns.

4. Null hypothesis

1. There is no difference in soft tissue features of Malay patients from lateral cephaolgram.
2. There is no association between the soft tissue findings and the patients' skeletal patterns.

5. Research questions

1. Is there a difference in soft tissue features of Malay patients from lateral cephaolgram?
2. Is there an association between the soft tissue findings and the patients' skeletal patterns?

CHAPTER 2

LITERATURE REVIEW

1. Introduction

Soft tissue analysis plays a very important role in orthodontics where it aids in the diagnosis, treatment planning and facilitates communication between specialists. Even with the latest 3D technology, lateral cephaolgram is still integral tool that provides a fundamental data for the comprehensive of craniofacial complex. In the early years, cephalometric were often use to understand patient's underlying dentoskeletal pattern. Soft tissue analysis was later introduced as clinicians began to understand the complex relationship between the underlying the soft tissue and skeletal pattern (Turley, 2015).

There are various types of soft tissue cephalometric analyses that are often use by clinicians, soft tissue analyses of Burrstone, Steiner, Merrifield, Ricketts and Holdaway. Therefore, the Holdaway analysis is the most common used in soft tissue evaluation. Holdaway Analysis is a type of soft tissue analysis that has been introduced by Holdaway (1983) and is commonly use to aid clinician interpret the soft tissue findings in lateral cephaolgram. Holdaway soft tissue analysis has been adapted in most cephalometric studies to understand soft tissue characteristic in different population or ethnicities. The establishment of Holdaway analysis among Malay patient would further aid our understanding on Malay patient's soft tissue profile.

1.1 Steiner’s soft tissue analysis

The soft tissue analysis is basically a graphic record of the visual observation made in the patient clinical assessment. The analysis of the soft tissue involves an appraisal of the soft tissue adaptation to the bony profile with attention to the shape, size, and posture of the lips. The thickness of the soft tissue over the symphysis mentalis and the nasal structure as it associates to the lower face is also analyzed. Merrifield, Ricketts, Haldaway, and Steiner develop standards and lines of reference for facial profile harmony. Although there is no uniform concept of what constitutes an ideal profile, the reference Steiner's S-line for evaluating the facial profile harmony is commonly used during orthodontics diagnosis. Based on Steiner, the Steiner's S-line is defined as, a line extending from the couture of soft tissue chin to the middle of an S formed by the inferior border of the nose when the lip in well-balanced faces (Figure 1.1, a). The lips that are positioned beyond the S-line show a tendency to be protrusive (Figure 1.1, b), whereas the lips that are located behind this line tend to be retrusive (Figure 1.1, c).

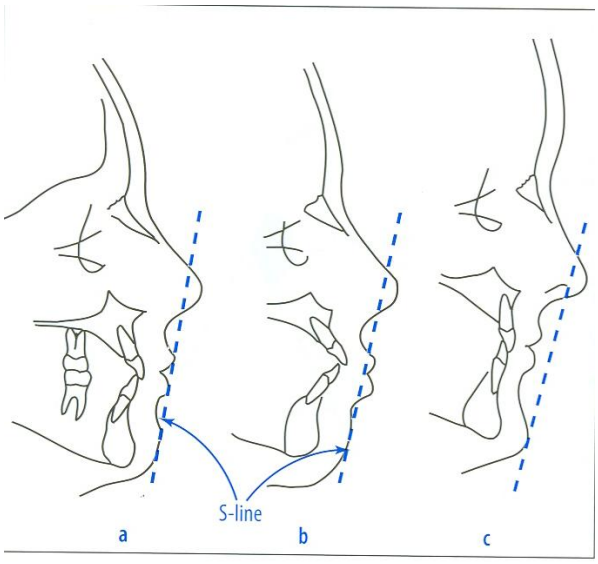

Figure 1.1: Steiner's S-line. (a) Lips in balance at rest; (b) Lips too protrusive ; (c) Lips or lower facial profile too retrusive (Jacobson, 1995)

1.2 Ricketts analysis

Ricketts produced his analysis with the intent of reviewing the purpose and usefulness of the cephalometric survey and to stress the use of this technique in treatment planning and estimating growth.

The purpose of analysis is objective and encompasses the 4 C's of cephalometrics:

1- To characterize or describe the existing conditions.
2- To compare one individual with another or the same individual with himself at a later time.
3- To classify certain descriptions into various categories.
4- To communicate all these aspects to the clinician, to a fellow research worker, or to a parent.

Ricketts's E-line is drawn from pronasale (Pn) to pogonion Pog' (Figure 1.2, a and Figure 1.2, b). The upper lip lies about 4 mm behind E-line, but the lower lip lies about 2mm behind it to consider as the normal (Jacobson, 1995).

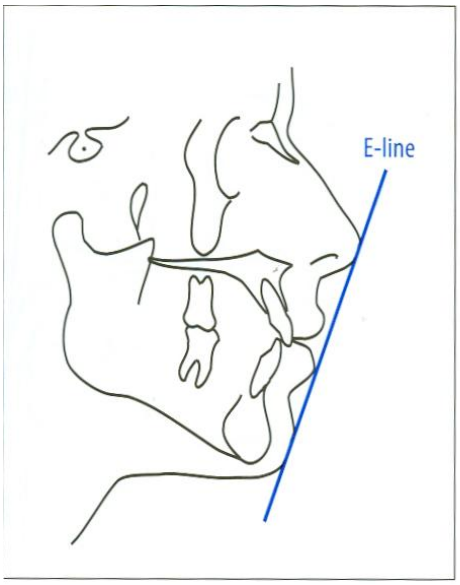

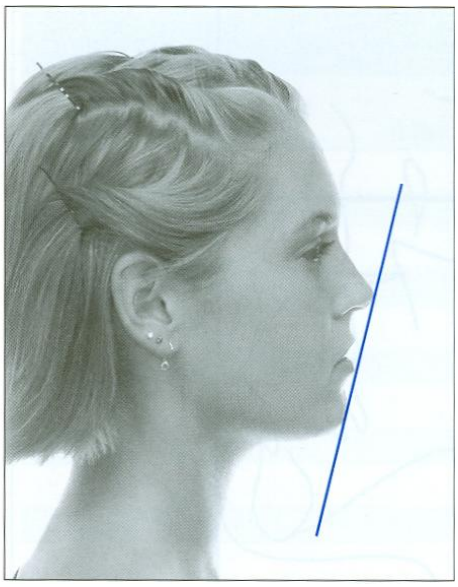

Figure 2.1.2 (a) Figure 2.1.2 (b)

Figure 1.2 a: E-lines of Ricketts (esthetic plane). It is drawn from Pn to Pog'. The upper lip is about 4 mm behind this reference line; lower lip lies about 2 mm behind it. Figure 1.2 b: E-line drawn on patient photograph (Jacobson, 1995)

1.3 Burrstone analysis

Jacobson (1995) described the following landmarks and parameters used in Burstone soft tissue analysis:

- Soft tissue nasion (N') – The greatest concavity point in the midline between the nose and the forehead.
- Glabella (G) – The point of the most prominent area of the forehead in the midsagittal plane.

- Subnasale (Sn) – The point where the nasal septum and the upper lip meet in the midsagittal plane.
- Columella point (Cm) – The point of the most anterior area on the columella of the nose.
- Stomion inferius (Stm) – The point of the upper most area on the vermilion border of the lower lip.
- Labrale superius (Ls) – The point indicating the vermilion border of the upper lip in the midsagittal plane.
- Stomion superius (Stms) – The point of the lower most area on the vermilion border of the upper lip.
- Mentolabial sulcus (Si) – The most posterior point between the lower lip and soft tissue chin.
- Labrale inferius (Li) – The point indicating the vermilion border of the lower lip in the midsagittal plane.
- Soft tissue gnathion (Gn') – The midpoint between soft tissue menton and soft tissue pogonion.
- Soft tissue pogonion (Pog') – The most anterior point on the soft tissue chin profile.
- Cervical point (C) – The midpoint between the neck and submental area.
- Soft tissue menton (Me') – The lowest point on the soft tissue chin contour.

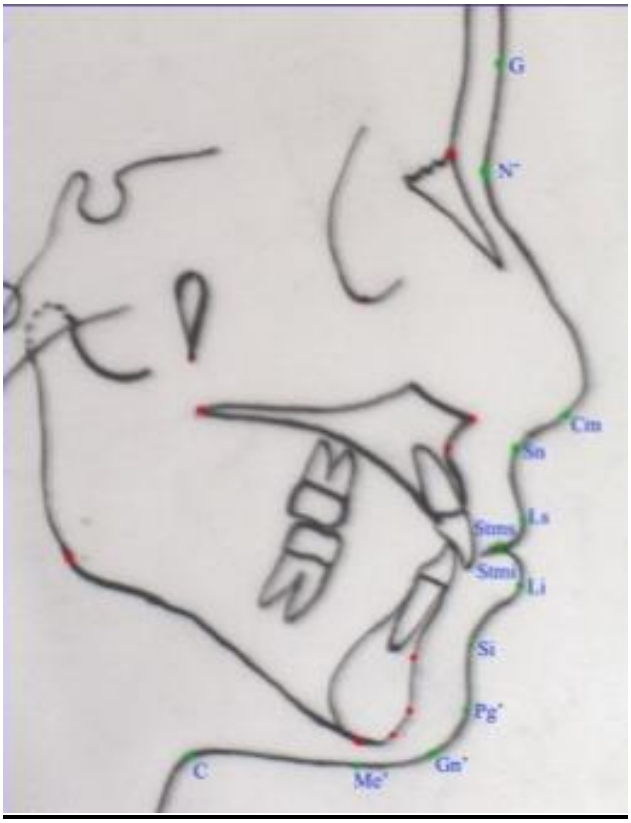

Figure 1.3: Burrstone soft tissue landmarks (profile view) (Frank et al., 1976)

There are 13 parameters that are included in Burstone soft tissue analysis to evaluate facial form, lip position and lip form. Six parameters are used to determine the facial form and seven parameters are used to describe the lip position and form.

1.3.1: Facial form

- Facial Convexity Angle (G-Sn- Pog') - This angle is constructed by intersecting G-Sn line and Sn- Pog' line (Figure 1.3.1.a). The standard value of this angle is 12˚ ± 4˚. Any increase or decrease in this value indicates convex or concave profile respectively.
- Maxillary prognathism (G-Sn) - Distance between subnasale (Sn) and a line perpendicular to Horizontal Plane (HP) passing through glabella (G)

gives maxillary prognathism (Figure 1.3.1.a). The standard value is 6 ± 3 mm. A negative number suggests retrognathism while a large positive value suggests prognathism.

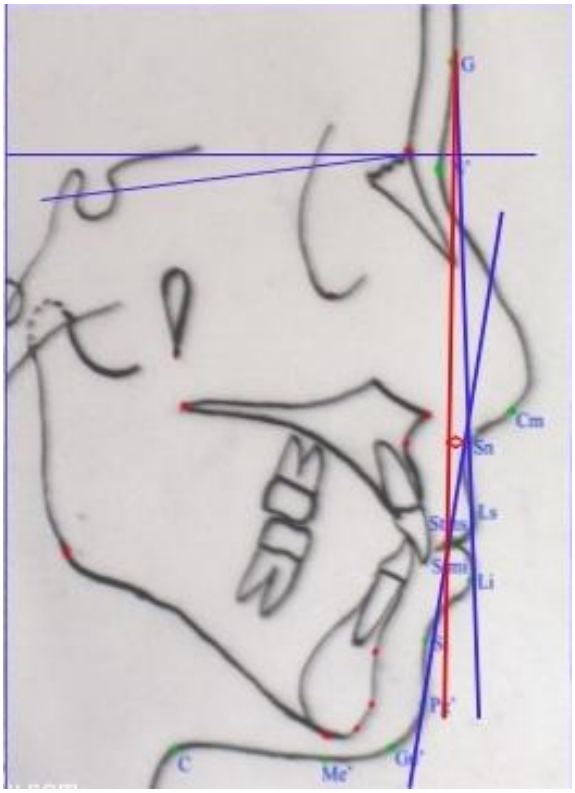

Figure 1.3.1.a: Facial convexity angle and maxillary prognathism (Frank et al., 1976)

- Mandibular prognathism (G- Pog') - Distance between pogonion (Pog') and a line perpendicular to HP passing through G gives mandibular prognathism (Figure 1.3.1.b). The standard value is 0 ± 4 mm. A negative number suggests retrognathism while a large positive value suggests Prognathism.

Figure 1.3.1.b: Mandibular prognathism (Frank et al., 1976)

- Vertical height ratio (G-Sn/Sn-Me) - It is the ratio between Sn-Me' (lower facial third) and G-Sn (middle facial third) measured perpendicular to HP (Figure 1.3.1.c). The standard value 1:1. Increased ratio suggests increased middle third height and vice versa.
- Lower face throat angle (Sn-Gn-C) - It is the angle constructed by intersection of Gn'-C and Sn-Gn' (Figure 1.3.1.c). The standard value is 100° ± 7°. This angle affects treatment planning to correct anteroposterior facial dysplasia.

Figure 1.3.1.c: Vertical height ratio and lower face throat angle (Frank et al., 1976)

- Lower vertical height depth ratio (Sn-Gn/C-Gn) – This ratio is obtained by dividing Sn-Gn' distance with C-Gn' distance (Figure 1.3.1.d). The standard value is 1.2: 1. A much larger than 1 value indicates that patient has a relatively short neck.

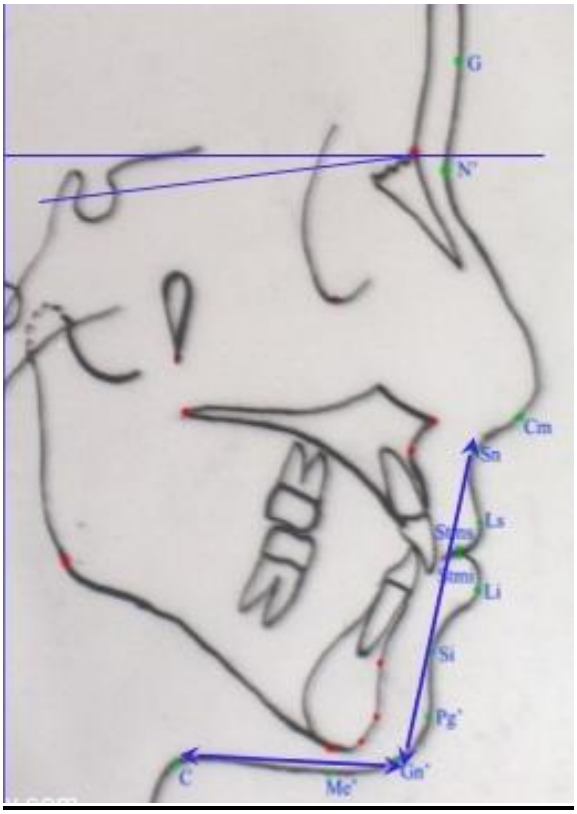

Figure 1.3.1.d: Lower vertical height depth ratio (Frank et al., 1976)

1.3.2: Lip position and form

- Nasolabial angle (Cm-Sn-Ls) - It is the angle constructed by intersection of Sn-Ls and Cm-Sn line (Figure 1.3.2.a). The standard value 102° ± 8°. Value that is lower than the average suggests proclination of upper incisors or anterior maxillary base protrusion or both and is termed as acute angle, whereas values that are higher than average suggests retroclination of upper incisors or maxillary base retrusion or both thus is termed as obtuse angle.

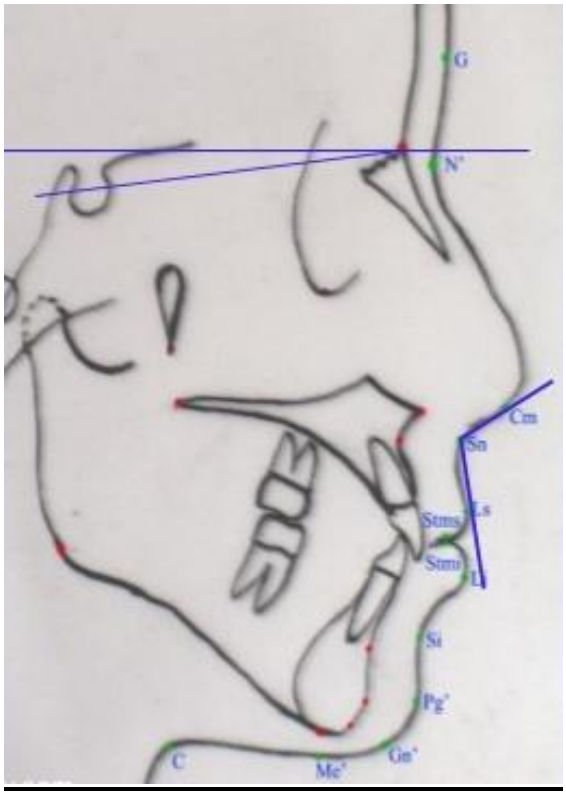

Figure 1.3.2.a: Nasolabial angle (Frank et al., 1976)

- Upper lip protrusion (Ls to Sn- Pog') - It is perpendicular distance between Ls to Sn- Pog' line (Figure 1.3.2.b). The standard value is 3 ± 1 mm.
- Lower lip protrusion (Li to Sn- Pog') - It is perpendicular distance between Li to Sn- Pog' line (Figure 1.3.2.b). The standard value is 2 ± 1 mm

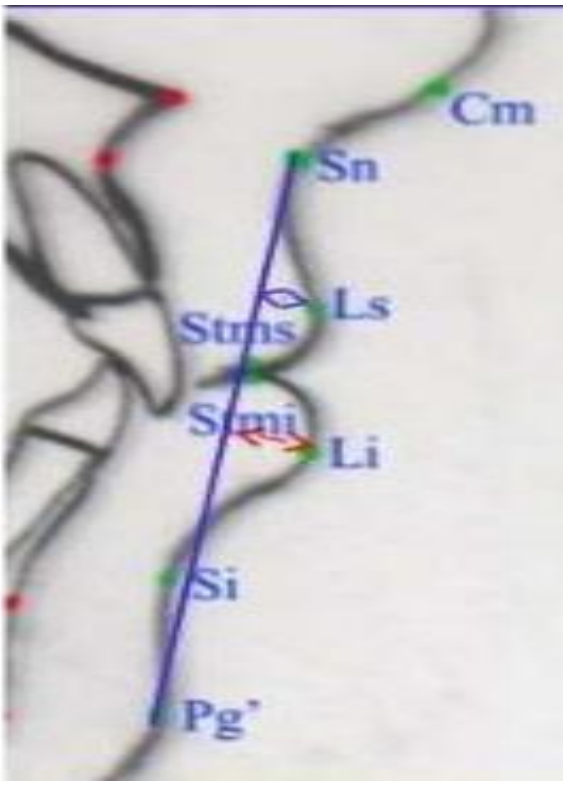

Figure 1.3.2.b: Upper lip protrusion and lower lip protrusion (Frank et al., 1976)

- Mentolabial sulcus depth (Si to Sn- Pog' - It is perpendicular distance between deepest point on the mentolabial sulcus to Li- Pog' line (Figure 1.3.2.c). The standard value 4 ±2 mm. The depth of the sulcus is effected by various factors which are flared lower incisors, flaccid lower lip tone, extruded upper incisors causing rolling of lower lip, and prominence of chin.

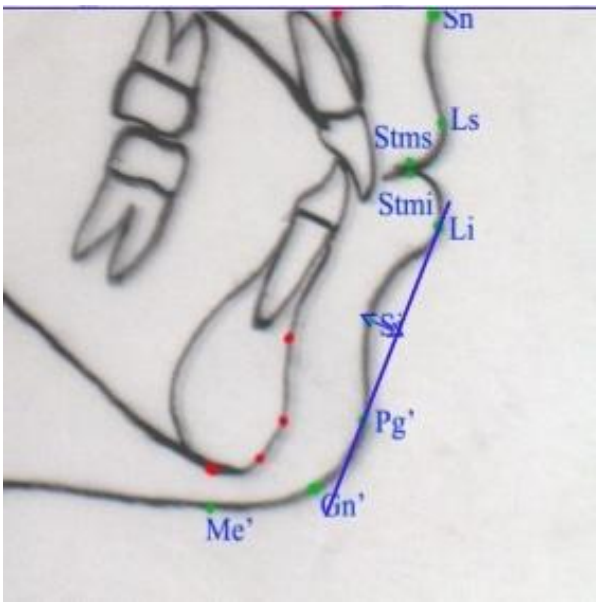

Figure 1.3.2.c: Mentolabial sulcus depth (Frank et al., 1976)

- Vertical lip chin ratio (Sn-Stm/Sti-Me) - It is ratio between Sn-Stms and Stmi-Me' (Figure 1.3.2.d). The standard value is 0.5 or 1: 2. Whenever the value decreases vertical reduction genioplasty should be considered.

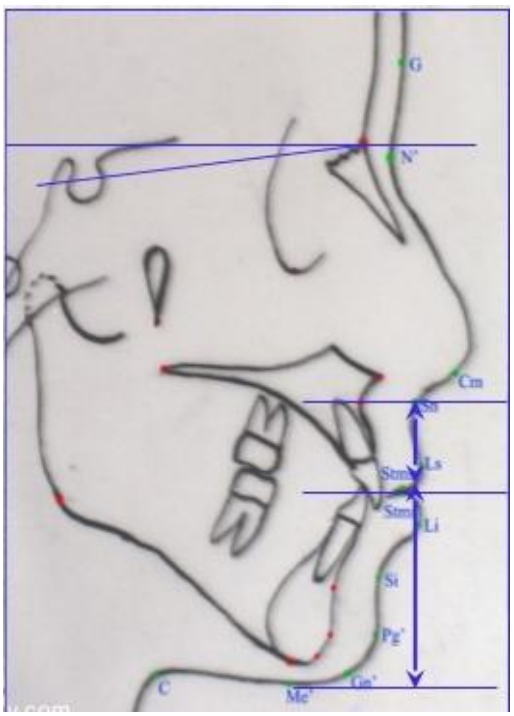

Figure 1.3.2.d: Vertical lip Chin ratio (Frank et al., 1976)

- Maxillary incisor exposure (Stm U1) - It is obtained by measuring the distance between tip of upper central incisor and Stms (Figure 1.3.2.e). The standard value is 2 ± 2 mm. Increased the exposure of incisor may be due to short upper lip or vertical maxillary excess. Declined the exposure of incisor may be due to vertical maxillary deficiency or larger upper lip.

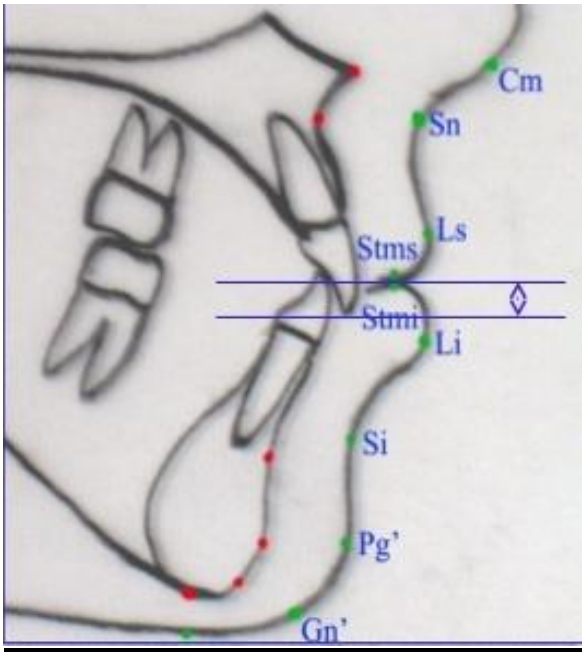

Figure 1.3.2.e: Maxillary incisor exposure (Frank et al., 1976)

- Inter labial gap - It is the distance between Stms and Stmi (Figure 1.3.2.f). The standard value 2 ± 2 mm. Patients with increased vertical maxilla show a tendency to have incompetent lips and large interlabial gap. Patients with decreased vertical maxilla show a tendency to have lips redundancy without interlabial gap.

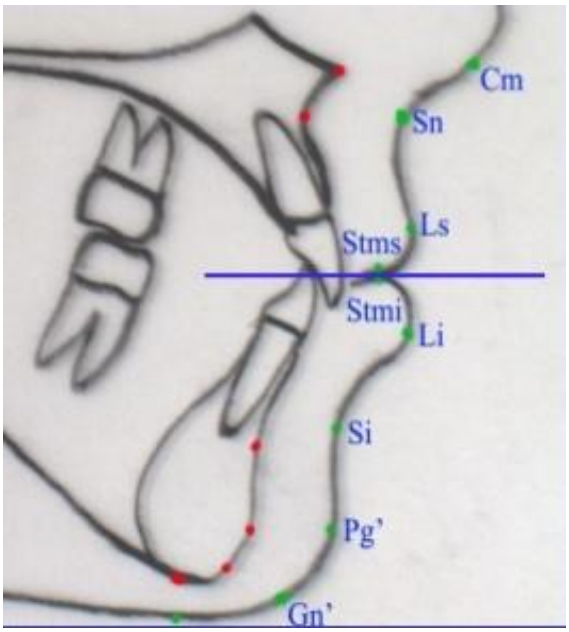

Figure 1.3.2.f: Inter labial gap (Frank et al., 1976)

1.4 Merrifield analysis

Merrifield's Z-angle shows the amount of lip protrusion which is formed by intersecting the Frankfort plane and the profile line which is a line drawing tangent to the most prominent lip and to the soft tissue pogonion point (Fig 1.4). It averages 80˚ ± 9˚. Ideally the lower lip should be tangent or slightly behind this profile line, whereas the upper lip should be tangent to it (Jacobson, 1995).

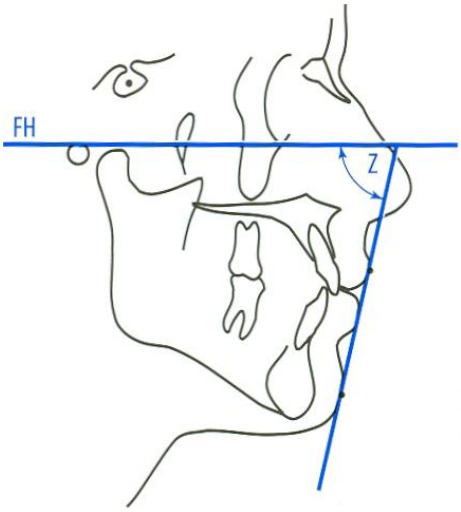

Figure 1.4: Merrifield's Z-angle is formed by the intersection of FH and a line connecting Pog' and the most protrusive lip point (may be upper or lower lip) (Average value, 80˚ ± 9˚) (Jacobson, 1995)

1.5 Holdaway analysis

Holdaway analysis is a type of soft tissue analysis that has been introduced by Holdaway (1983) and is commonly use to aid clinician interpret the soft tissue findings in lateral cephaolgram. It has eleven main variables (soft tissue facial angle, upper lip curvature, skeletal profile convexity, H angle, nose prominence, upper sulcus depth, upper lip thickness, upper lip strain, lower lip to H-line, lower sulcus depth, and soft tissue chin thickness) that are used to describe qualitatively the soft tissue characteristic of a patient's facial profile.

Study conducted by Holdaway (1983) found that the treatment goals were much improved when soft tissue features were considered during treatment planning. Furthermore, the soft tissue profile analysis plays an important role in evaluating the external facial appearance and can reflect the outcome that perceived by an observer.

The following landmarks were identified on each lateral cephalogram according to Jacobson (1995) and Athanasios (1995).

The following parameters were evaluated:

1.5.1: Angular measurement

1.5.1.a: Soft tissue facial angle (Figure 1.5.1.a): Angel constructed by intersecting a line extended from N' to pog' with FH. Ideally, this angle should be 90˚ to 92˚. A greater angle suggests a mandible that is too protrusive; an angle that is less than 90˚ suggests a recessive lower jaw.

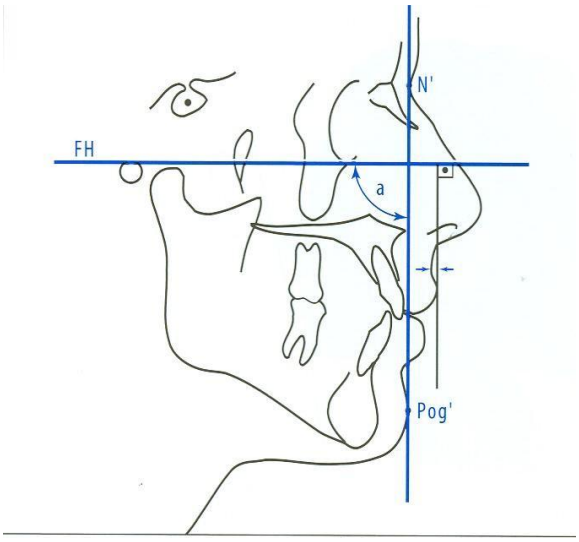

Figure 1.5.1.a: Facial angle and upper lip curvature. The facial angle (a) is formed by the intersection of FH and a line connecting N' and Pog'. Ideal values are 90˚ to 92˚. Upper lip curvature is defined as the depth of the sulcus from a line drawn perpendicular to FH and tangent to Ls (ideal value, 2.5 mm) (Jacobson, 1995)

1.5.1.b: H angle (Figure 1.5.1.b): The H-line is tangent to Me' and Ls. The H angle established between the soft tissue N'-Pog' line and H-line. This angle gives an idea about the upper lip prominence or the soft tissue chin