

## A PRELIMINARY STUDY OF *Blastocystis* sp. ISOLATED FROM CHICKEN IN PERAK AND SELANGOR, MALAYSIA

FARAH HAZIQAH M.T.<sup>1\*</sup>, CHANDRAWATHANI P.<sup>2</sup>, MOHD ZAIN S.N.<sup>1</sup>, SURESH KUMAR G.<sup>3</sup>, HEMALATHA C.<sup>3</sup> AND PREMAALATHA B.<sup>2</sup>

1 Institute of Biological Sciences, Faculty of Sciences, University of Malaya, 50603 Kuala Lumpur, Malaysia

2 Veterinary Research Institutes, 59, Jalan Sultan Azlan Shah, 31400 Ipoh, Perak, Malaysia

3 Department of Parasitology, Faculty of Medicine, University of Malaya, 50603 Kuala Lumpur, Malaysia

\* Corresponding author e-mail: izziqah@gmail.com

**ABSTRACT.** *Blastocystis* is considered to be a zoonoses and it is believed that animals such as chicken constitute large reservoirs for human infection via the faecal-oral route. Therefore, *Blastocystis* infection was surveyed in free-range chicken and cage-reared chicken comprising broiler birds for consumption as well as jungle fowls and silkie chicken kept for recreation. Fresh faecal samples collected were examined by wet smear preparation and were cultured in Jones medium supplemented with 10% horse serum. Out of 107 chickens, it was found that most of the free-range chicken was positive for *Blastocystis* sp. with a high prevalence rate of 80%–100% in village chicken, jungle fowl and white silkie chicken. However, the cage-reared chicken, consisting of broiler chicken had no infection. The vacuolar form was the most common *Blastocystis* cell form found in cultures, similar to *B. hominis*. These cells were usually spherical and vary greatly in size, ranging from 10 µm to 30 µm in diameter. Owing to the free ranging and scavenging habits, the likelihood of acquiring the infection from

the environment contaminated with the faecal material of animals with *Blastocystis* is high in free-range chicken as compared to caged chicken.

*Keywords:* *Blastocystis* sp., zoonotic, chicken, morphology, *in vitro* culture

### INTRODUCTION

*Blastocystis* is a genus of single celled protozoan parasites, living in the gastrointestinal tracts of humans and many animals (Stenzel *et al.*, 1993; Stenzel and Boreham, 1996; Abe *et al.*, 2002). *B. hominis* defines the parasite isolated from humans while *Blastocystis* sp. represents those isolated from other animal hosts. According to Tan (2008), there are four commonly described forms which are vacuolar, granular, amoeboid, and cyst forms. Faecal-oral transmission is the most accepted pathway and transmission involves only the cyst form of the parasite.

A number of studies on *Blastocystis* have been carried out in Malaysia. However, most of the previous studies concentrated

on *Blastocystis* sp. in humans. According to Lee *et al.* (1999), *Blastocystis* sp. infections appear to be common in birds. Based on previous studies, it was found that domestic fowls and ostriches showed 100% infection (Yamada *et al.*, 1987a), domestic hen 80%–100% infection (Belova and Kostenko, 1990) whereas domestic ducks 80% infection (Pakandl and Pecka, 1992). However, there are very limited studies on *Blastocystis* from poultry in Malaysia. Thus, a survey of *Blastocystis* infection in various caged and non-caged birds and poultry was conducted by the Veterinary Research Institute, in order to elucidate the status of this infection. This information is important to poultry farmers and veterinary health workers as *Blastocystis* infection is zoonotic and proper handling and care is vital when working with these animals.

## MATERIALS AND METHODS

### Sample

Several species of domestic and wild chicken were surveyed for the presence of *Blastocystis* sp. from February to May, 2013. A total of 107 chickens, consisting of free-ranging chicken (village chicken, jungle fowl, broiler chicken and white silkie chicken) and cage-reared chicken (broiler chicken) were sampled from various wet markets, farms as well as from village households in Perak and Selangor by adopting a convenience sampling method. Fresh faecal samples were collected from

the hen house or cages and stored in stool collection containers.

### *In vitro* cultivation

A pea size amount of each faecal sample was inoculated into a sterile screw-top containing 3 ml of Jones medium supplemented with 10% heat-activated horse serum (Jones, 1946; Suresh and Smith, 2004). Each sample was incubated at 37 °C for 48 to 72 hours. The sediments of cultures were observed by light microscopy. If the organisms were not observed in cultures at day 5, the samples were considered negative. The positive faecal smears were fixed with methanol and stained with Giemsa to observe the detailed morphology of the protozoan. The forms of *Blastocystis* sp. observed by microscopy after staining were analysed according to the shape and size of the microorganism.

## RESULTS

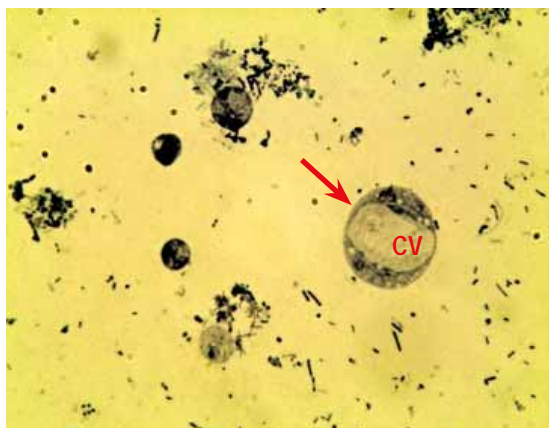
Results indicate that there was an occurrence of natural infection of *Blastocystis* sp. in the poultry sampled.

It was found that 27 out of 107 (25.2%) chicken faecal samples were positive for *Blastocystis* sp. A high prevalence of 33.3%–100% was observed in various species of free-range chicken whereas cage-reared chicken showed no infection (Table 1).

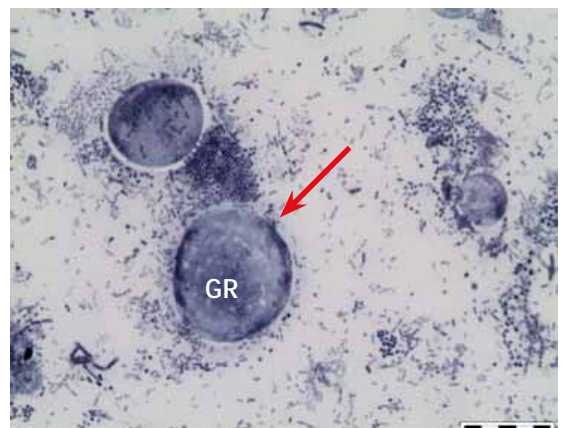Morphological examination of *Blastocystis* cell forms found in chicken

**Table 1:** Prevalence of *Blastocystis* sp. in domestic and wild chicken.

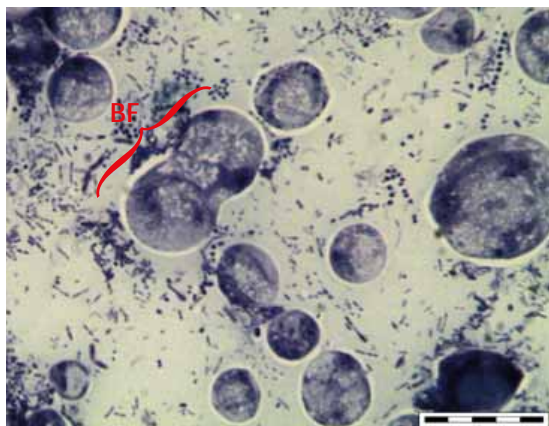
Study animals	No. of faecal samples	No. of chicken infected (%)
<b>Cage-reared chickens</b>		
Broiler chicken	32	0
<b>Free-range chickens</b>		
Jungle fowl	1	1 (100)
Village chicken	72	24 (33.3)
White silkie chicken	2	2 (100)
<b>Total</b>	<b>107</b>	<b>27 (25.2)</b>



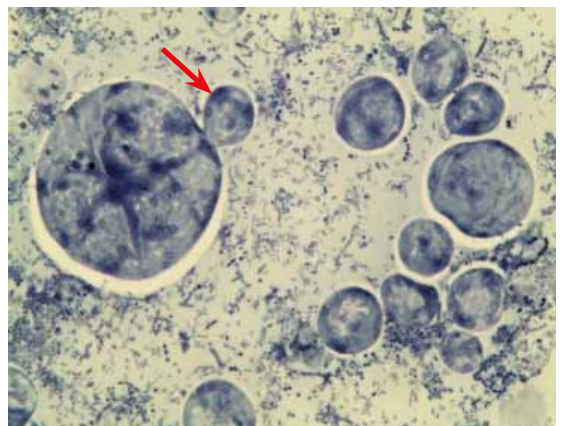
(a) Vacuolated forms (arrow) from culture.



(b) Granular form (arrow), showing clumps of granules in the central vacuoles.



(c) A typical binary fission of vacuolar form.



(d) Cell undergoing budding (arrow).

**Figure 1.** Light micrographs showing *Blastocystis* sp. in chicken. *Abbreviations:* CV, central vacuole; GR, granules; BF, binary fission.

was similar to *B. hominis*. Two forms of *Blastocystis* sp. were observed from culture; vacuolar (Figure 1a) and granular (Figure 1b). The most common form observed was vacuolar, rounded and containing a central body resembling a large vacuole that occupies approximately 90% of the cell, with a thin layer of peripheral cytoplasm. The measurements of the vacuolar forms of *Blastocystis* sp. were quite varied, with a minimum measurement of 10  $\mu\text{m}$  and a maximum of 30  $\mu\text{m}$  in diameter. In this study, two types of reproduction of the *Blastocystis* sp. could be observed; binary fission (Figure 1c) and budding (Figure 1d). The most common reproductive form was binary division, which is characterised by the partition of the cytoplasm of the mother cell and results in two daughter cells with an equal size and shape.

## DISCUSSION AND CONCLUSION

This study shows that *Blastocystis* sp. appeared to be widespread in free-range chicken rather than in caged chicken. Owing to the free ranging and scavenging habits, the likelihood of acquiring the infection from environment contaminated with the faecal material of animals with *Blastocystis* is high in free-range chicken in comparison to caged chicken. Therefore, good hygiene and sanitary conditions were possible inhibitors of environmental contamination and of the faecal-oral transmission of *Blastocystis* infection among chicken (Lee and Stenzel, 1999).

*Blastocystis* is a polymorphic organism. In this study, the vacuolar form was the predominant cell type seen in axenized *in vitro* cultures as similarly reported by Tan (2004). Meanwhile, the morphometric data were consistent with those described by Lee and Stenzel (1999) and Bergamo do Bomfim and Machado do Couto (2013) which were obtained from domestic chicken.

A number of studies on *Blastocystis* sp. have been carried out in Malaysia. Suresh *et al.* (1996) studied *Blastocystis* sp. in laboratory animals, sheep, rabbits, monkeys, dogs and cats which only involve a small number of samples whereas Tan *et al.* (2013) studied on *Blastocystis* sp. in caprine. However, *Blastocystis* sp. of poultry has not yet been reported in Malaysia. To date, this study is the only report on *Blastocystis* sp. of chicken in Peninsular Malaysia.

This information is vital to free range poultry farmers and veterinary health care workers so as to enable proper care and protection is practised when handling the animals and samples. The zoonotic implications of this disease make it important for further research to elucidate the transmission cycle from animals to humans.

## REFERENCES

1. Abe, N., Nagoshi, M., Takami, K., Sawano, Y., Yoshikawa, H., (2002). A survey of *Blastocystis* sp. in livestock, pets, and zoo animals in Japan. *Veterinary Parasitology* **106**: 203-212.
2. Belova, L. M., Kostenko, L. A. (1990). *Blastocystis galli* sp. n. (Protista: Rhizopoda) from the intestine of domestic hens. *Parazitologiya* **24**: 164-168.
3. Bergamo do Bomfim, T. C. and Machado do Couto, M. C. (2013). Morphological diagnosis and occurrence of *Blastocystis* spp. obtained from the stool samples of domestic bird species commercialized in municipal markets. *Journal of Parasitology and Vector Biology* **5** (3): 20-26.
4. Jones, W. R. (1946). The experimental infection of rats with *Entamoeba histolytica*. *Annals of Tropical Medicine and Parasitology* **40**: 130-140.
5. Lee, M. G. and Stenzel, D. J. (1999). A survey of *Blastocystis* in domestic chickens. *Parasitology Research* **85**: 109-117.
6. Stenzel, D. J. and Boreham, P. F. L. (1996). *Blastocystis hominis* revisited. *Clinical Microbiology Reviews* **9**: 563-584.
7. Stenzel, D. J., Cassidy, M. F., and Boreham, P. F. L. (1993). Morphology of *Blastocystis* sp. isolated from circus animals. *International Journal for Parasitology* **23** (5): 685-687.
8. Suresh, K., Khairul Anuar, A., Init, I. and Saminathan, R. (1996). Prevalence of *Blastocystis hominis* in laboratory-bred animals. *Tropical Biomedicine* **13**: 89-91.
9. Suresh, K. and Smith, H. (2004). Comparison of methods for detecting *Blastocystis hominis*. *European Journal of Clinical Microbiology and Infection Diseases* **23**: 509-511.
10. Pakandl, M. and Pecka, Z. (1992). A domestic duck as a new host for *Blastocystis* sp. *Folia Parasitologica* **39** (1): 59-60.
11. Tan, K. (2008). New Insights on Classification, Identification, and Clinical Relevance of *Blastocystis* spp. *Clinical Microbiology Reviews* **21** (4): 639-665.
12. Tan, C. H., Tan, P. C., Sharma R., Sugnaseelan, S. and Suresh, K. (2013). Genetic diversity of caprine *Blastocystis* from Peninsular Malaysia. *Parasitology Research* **112**: 85-89.
13. Tan, K.S.W. (2004). *Blastocystis* in humans and animals: new insights using modern methodologies. *Veterinary Parasitology* **126**: 121-144.
14. Yamada, M., Yoshikawa, H., Tegoshi, T., Matsumoto, Y., Yoshikawa, T., Shiota, T., and Yoshida, Y. (1987a). Light microscopical study of *Blastocystis* spp. in monkeys and fowls. *Parasitology Research* **73**: 527-531.

---

**ACKNOWLEDGEMENT.** The authors would like to thank University of Malaya for advice on this study. A special thank to all Parasitology and Haematology staff in VRI for their helpful guidance and also undergraduate students for their help in collecting samples for this study.