

**TOPICAL LATANOPROST (PGF₂ α analogue)
FOR THE PREVENTION OF IMMEDIATE
INCREASE IN INTRAOCULAR PRESSURE
AFTER CATARACT EXTRACTION**

DR. NIK AZLAN NIK ZAID
MD (USM)

DISSERTATION SUBMITTED IN PARTIAL FULFILMENT
OF THE REQUIREMENT FOR THE DEGREE OF
MASTER OF MEDICINE
(OPHTHALMOLOGY)


SCHOOL OF MEDICAL SCIENCES
UNIVERSITI SAINS MALAYSIA
MAY 2001

DISCLAIMER

This dissertation is my own work. The sources of all the references used are listed.

The latanoprost eye drops was supplied by Pharmacia & Upjohn, Malaysia. I have no commercial or proprietary interest in latanoprost eye drops.

Signed,

A handwritten signature in black ink, appearing to be 'Azlan Nik Zaid', written over a large, faint 'X' mark.

(DR. NIK AZLAN NIK ZAID)

ACKNOWLEDGEMENT

Bismillahirrahmanirrahim.

In the name of Allah who is the most loving and merciful. I pray for thankfulness for the strength he gave to complete this dissertation.

I wish express my sincere gratitude to my supervisor, Dr. Raja Azmi Bin Mohd Noor, lecturer in Department of Ophthalmology, School of Medical Sciences, Universiti Sains Malaysia for his invaluable guidance and advise and encouragement during the preparation of this dissertation.

I am grateful to Dr. Abdul Mutalib Othman, lecturer and Head of Department of Ophthalmology, Dr. Elias Hussein, Dr. Mohtar Ibrahim and Dr. Wan Hazabbah Wan Hitam, and all my friends for invaluable help in the collection of cases for this dissertation and continuous guidance throughout my training periods.

My special thanks to Dr. Zahiruddin for his assistance in the statistical data analysis of the data collected.

Last but not least, my sincere thanks to my family for their support, time and understanding that have made this effort possible.

Thank you.

TABLE OF CONTENTS

I	Title	i
II	Disclaimer	ii
III	Acknowledgements	iii
IV	Table of contents	iv
V	List of tables	vii
VI	List of figures	viii
VII	Abstrak	ix
VIII	Abstract	xi

Text

1.	Introduction	1
	1.1 <i>Aims of study</i>	3
2.	Background information	4
	2.1 <i>History</i>	4
	2.1.1 The effect of cataract extraction on IOP	
	2.1.2 Complications of post-operative ocular hypertension	
	2.1.3 Agents used in the prevention of post-operative ocular hypertension	
	2.2 <i>Latanoprost</i>	13
	2.2.1 Chemical structure of latanoprost	

2.2.2	Pharmacological properties	
2.2.3	Pharmacokinetic properties	
2.2.4	Side effects	
3.	Material and Methods	17
3.1	<i>Study design</i>	17
3.2	<i>Sampling</i>	17
3.2.1	Sample size	
3.3	<i>Patient selection</i>	18
3.4	<i>Criteria for exclusion</i>	19
3.5	<i>Criteria for dis-continuing from the study</i>	19
3.6	<i>Minimizing error</i>	20
3.7	<i>Pre-operative evaluation</i>	21
3.7.1	History	
3.7.2	Ocular examination	
3.7.3	General examination	
3.7.4	Laboratory investigations	
3.7.5	Demographic data and consent	
3.8	<i>Pre-operative mydriasis and medication</i>	23
3.9	<i>Anaesthesia</i>	23
3.10	<i>Pre-operative intraocular pressure reduction</i>	24
3.11	<i>Surgical technique</i>	24
3.12	<i>Post-operative follow-up</i>	26

4.	Results	29
5.	Discussion	38
6.	Conclusion	45
7.	References	46
8.	Appendix	49

LIST OF TABLES

	Title	Page
Table I	Demographic data and mean axial length.	28
Table II	Mean amount of healon used and mean duration of surgical procedure	31
Table III	Mean \pm SD intraocular pressure (mmHg) over time	32
Table IV	Level of IOP in latanoprost group pre and post-operation	36
Table V	Level of IOP in control group pre and post-operation	37
Table VI	IOP (mmHg) in the latanoprost group before and after the operation	51
Table VII	IOP (mmHg) in control group before and after the operation	52

LIST OF FIGURES

	Title	Page
Figure 1	Viscoelastic substance (Healon GV) used in this study	26
Figure 2	Intraocular lens used in this study	26
Figure 3	Latanoprost 0.005% and optizoline used in this study	27
Figure 4	Age distribution between the groups	29
Figure 5	Comparison of means IOP between the groups at corresponding times	33
Figure 6	Comparison of means IOP at different time between the two groups	34

ABSTRAK

Kami telah menjalankan satu kajian ke atas kesan analog Prostaglandin PGF 2α terhadap tekanan intraokular mata pesakit yang menjalani pembedahan katarak. Sebanyak 72 mata pesakit yang menjalani pembedahan katarak menggunakan teknik endocapsular beserta implantasi kanta intra-okular menggunakan bahan viskoelastik, telah dibahagikan kepada dua kumpulan secara rawak. Sebanyak 36 mata pesakit di dalam kumpulan latanoprost menerima ubat titis latanoprost 0.005% sebaik selesai pembedahan sementara 36 mata pesakit di dalam kumpulan kontrol menerima ubat titis tetrahydrozoline hydrochloride (optizolin). Aspek-aspek lain rawatan dan pembedahan bagi kedua-dua kumpulan adalah sama. Tekanan intraokular telah diukur sebelum pembedahan (pra-pembedahan) dan 3, 6, 9 dan 24 jam selepas pembedahan.

Purata tekanan intraokular pra-pembedahan bagi kumpulan latanoprost adalah 12.31 ± 2.11 mmHg dan bagi kumpulan kontrol adalah 12.72 ± 2.49 mmHg. Selepas pembedahan, tekanan intraokular sentiasa melebihi paras pra-pembedahan bagi kedua-dua kumpulan. Paras purata tekanan intraokular meningkat 6 jam pertama selepas pembedahan (dari 17.75 kepada 21.80 mmHg) dan kemudian menurun dengan paras terendah pada 24 jam selepas pembedahan. Corak perubahan tekanan yang sama ditunjukkan oleh kumpulan latanoprost (dari 15.94 kepada 19.11mmHg dalam masa 6 jam pertama), tetapi paras tekanan intraokular bagi kumpulan latanoprost sentiasa lebih rendah dari kumpulan kontrol. Perbezaan purata tekanan intraokular diantara dua kumpulan ini bagaimanapun didapati tidak mempunyai perbezaan yang signifikan ($P > 0.05$).

Kesimpulannya, pengambilan ubat titis latanoprost 0.005% sebaik selesai pembedahan katarak tidak menghasilkan penurunan tekanan intraokular yang signifikan jika dibandingkan dengan kumpulan kontrol dalam masa 24 jam pertama selepas pembedahan.

ABSTRACT

The effect of prostaglandin analogue PGF₂α was tested in immediate post-operative cataract extraction eyes. Seventy-two eyes undergoing endocapsular cataract extraction with capsular bag intraocular lens implantation using viscoelastic substance were randomly assigned into two groups. Thirty-six eyes in latanoprost group received 0.005% latanoprost eye drop at the end of the operative procedure while another thirty-six eyes in control group received a topical drop of placebo (tetrahydrozoline hydrochloride) similarly. In all other respects the eyes were treated identically. Intraocular pressure (IOP) was measured pre-operatively and at 3, 6, 9 and 24 hours post-operatively.

Pre-operatively the mean intraocular pressure was 12.31 ± 2.11 mmHg in the latanoprost group and 12.72 ± 2.49 mmHg in the control group. The mean IOP post-operatively was persistently higher than the pre-operative levels in both groups. An initial rise in mean IOP was noted at 6 hours post-operatively (from 17.75 to 21.80 mmHg). Subsequently, the mean IOP drops with the lowest post-operative IOP was noted at 24 hours post-operatively. Similar pattern of IOP changes were also seen in latanoprost group, however the mean IOP levels were always lower than IOP level in control group (from 15.94 to 19.11 mmHg). The highest mean post-operative IOP was 21.80 ± 7.32 mmHg. recorded in the control group at 6 hours post-operatively. The differences in the mean pressures in the two groups at corresponding times were not statistically significant ($P > 0.05$).

In conclusion, a single dose of 0.005% latanoprost given at the end of surgery did not produce a significant IOP-lowering effect when compared with a control group in the first 24 hour period post-operatively.

1. INTRODUCTION

INTRODUCTION

The acute rise in intraocular pressure (IOP) during the first twenty-four hours after cataract extraction has been documented for over 30 years (Gormaz, 1962, Rich et. al, 1974). Most eyes are tolerable to this transient raise in IOP without any clinically significant functional change or long term deleterious effect. However, the risk of permanently blinding ocular complication, particularly anterior ischaemic optic neuropathy do exist (Beri et. al, 1987, Hayreh, 1980). It becomes more critical to individuals with pre-existing vascular insufficiency (Hayreh, 1980).

Awareness of such complications has led to the prophylactic use of various pharmacological agents, including timolol, acetazolamide and intracameral acetylcholine. Timolol or carbonic anhydrase inhibitors were usually used post-operatively to control the IOP. Although effective, inhibition of aqueous production may disrupts the normal circulation of ions, glucose, enzymes, and metabolites necessary for proper homeostasis of the corneal endothelium and trabecular meshwork (Sears, 1981, Becker, 1995). Beside that, their side effects frequently constraint its routine use. An ideal drug to be used to prevent IOP spike should have minimal ocular and systemic adverse effects, with rapid onset of action for protection in the immediate post-operative period and prolong action to cover 24 hour postoperative ocular hypertensive period.

The rise in IOP during the postoperative period may be caused by obstruction of the trabecular outflow by inflammatory material or retained viscoelastic material. The latter has been shown to remain trapped in the trabecular meshwork even after its aspiration from the anterior chamber following intraocular lens implantation. It is not known whether obstruction of the trabecular pathway immediately after surgery also extends to the uveoscleral pathway. It is also not known whether by pharmacologically enhancing uveoscleral outflow would significantly and safely decrease the postoperative IOP.

A new group of ocular hypotensive agent, the prostaglandin F_{2α} (PGF 2α) analogue (latanoprost), marketed as Xalatan as the trade name, has been extensively studied on human volunteers, ocular hypertensives and primary open angle glaucoma (POAG) patients. We performed a controlled double blind clinical trial, to determine the effect of Latanoprost on intraocular pressure after cataract extraction. Latanoprost was specifically chosen because of its different mechanism in action compared to the timolol and carbonic anhydrase inhibitors, by increasing the uveoscleral outflow. The recommended therapy of one drop per day will avoid disturbing patient post-operatively for at least 24 hours.

1.1 AIM OF STUDY

To determine the effect of latanoprost 0.005% (prostaglandin F_{2α} analogue) on intraocular pressure during the first 24 hours post-operative period after cataract extraction.

2. BACKGROUND INFORMATION

BACKGROUND INFORMATION.

2.1 HISTORY

2.1.1 The effect of cataract extraction on the intraocular pressure

Cataract extraction has been documented to change the intraocular pressure (IOP) post-operatively since mid fifties, before the widespread use of modern microsurgical techniques. Earlier studies by Hilding (1955) reported a reduction in IOP after intracapsular cataract extraction. The IOP measurements were made only after 12th post-operative days, and he presumed that the IOP were zero or close to it in the immediate post-operative period. The cause of the hypotony was postulated to be due to trauma on ciliary body, filtration angle, or iris, individually or in combination, following surgical manipulation. The traction and tearing of the zonule cause oedema or hemorrhage or both of the ciliary body, disturbing the electrical potentials between the stroma and the epithelium, producing a reduction in aqueous production. The general congestion might enhance the rate of outflow. Those with collapse anterior chamber post-operatively were assumed to have wound leak.

The first reported ocular hypertension following cataract extraction was made by Gormaz in 1962. He noted a rise in IOP one-day after intracapsular cataract extraction without the use of alpha-chemotrypsin. His finding was supported by Kirsch in 1964,

which described an accentuation of this pressure rise associated with the use of alpha-chemotrypsin during intracapsular cataract extraction.

In mid sixties, operating microscope became popular among the ophthalmic surgeons. Delicate surgical instruments, fine needles and sutures materials came in together with the development of microsurgical techniques. About the same time, modern microsurgical extracapsular cataract extraction then was introduced. Following this, there was revived interest in the posterior chamber lens implantation.

With development of microsurgical technique, the multiple suturing method now becomes one of the factors for the cause of IOP alteration postoperatively. Rich (1968) demonstrated an accentuation of postoperative pressure rise 24 hours after intracapsular cataract extraction, with the use of multiple suture technique. He suggested that this resulted from a reduction in wound leakage. There were however questions raised as to the IOP rise was due to surgical interference with the trabecular` meshwork and the outflow channels. To answer those questions, Rich (1969) in his furthering studies demonstrated that there was a significant rise of IOP even when the section was purely corneal, with no surgical trauma to the trabecular meshwork. He suggested that a likely cause of the hypertension was the breakdown of the blood aqueous barrier during the immediate postoperative phase. The changes in the secondary aqueous for the purpose of healing contained higher protein, fibrin and cells, and were thicker in consistency, making it difficult to drain out of a watertight wound even through undamaged channels.

Rich and co-worker first described the kinetics of the early postoperative IOP surge in 1974. They found out that IOP reached an average peak of 39.3 mm Hg at a mean time of 6.8 hours after surgery. The IOP then decreased to an average of 23.1 mm Hg. after 24 hours post-operation. Similar result has been obtained from the latest study in 1988 by Gross et. al. They noted an acute increase in IOP started as early as 3 hours postoperatively and the pressure then decreased to preoperative level after 24 hours postoperation. Mean intraocular pressure after two to three hours postoperatively was 8.9 mm Hg. greater than the preoperative levels.

The exact mechanism of this rise in IOP is still unknown. Galin and co-workers in 1978 found a greater increase in IOP in the first 24 hours to those who underwent intracapsular cataract extraction with intraocular lens implant than the comparable control without implant. Those with extracapsular cataract extraction and lens implant had even higher rise of IOP in the first 24 hours (Galín, Lin and Obstbaum, 1978) The manipulative, mechanical and even chemical causes of inflammation were higher with more complicated procedures. It was concluded that all things being equal, any increase in inflammation led to an increase in IOP through increased outflow resistance. Gross et. al. (1988) suggested the increase in IOP may caused either from mechanical obstruction of the trabecular meshwork by zonular fragments, debris, or deformation of the angle structures beside the inflammation itself (Gross et. al, 1988).

However, with introduction of viscoelastic substances in the late seventies, Binkhorst (1980) was first to note that the post-operative rise in IOP might be accentuated by the

using of sodium hyaluronate into the anterior chamber. He reported marked elevation of IOP during the first 24 to 72 hours after operation in a group undergone extracapsular cataract extraction with healon, compared to the group which undergone similar operation without healon. The maximum IOP measurement was at day one post-operation. Other previous studies also reported similar results of raised IOP post-operatively in cataract extraction using sodium hyaluronate, however most of them did not focus on the IOP in the first 24 hours post-operation (Gross et. al, 1988, Naesser et. al, 1986, Passo et. al, 1985). Barron and associates (1985) were the first to document the increase in pressure that occurred within the initial 24-hour period after cataract surgery using healon. Raised IOP was found at 3 hours post-operatively and persisted above the pre-operative level till one-week post-operative period. The maximum mean pressure was $28.8 \text{ mmHg} \pm 11.9$ ($+11.3 \text{ mmHg} \pm 11.0$ difference from the pre-operative measurement) at 6 hours after surgery. Passo and his co-worker (1985), on the other hand noted the maximum IOP at 16 hours post-operatively with the mean difference of $+16.7 \text{ mmHg} \pm 1.1$ from the pre-operative level. The IOP only normalized to the pre-operative level at 72 hour post-operatively.

Healonid allows complex surgical manipulation in the anterior chamber, improves visibility while protecting the corneal endothelium and enclose tissues from the trauma of surgical instrumentation. The exact mechanism of post-operative increase in IOP after using healonid is not well understood but was thought to be secondary to a decrease in outflow facility (Lazenby et. al. 1981, Percival, 1982). Since healonid is a high viscosity substance, it has a great difficulty in leaving the anterior chamber through

the trabecular meshwork and in the mean time causing outflow obstruction. They exit from the eye via outflow channels without being metabolized. The viscosity has to be reduced with aqueous before this hydrophilic substance may run through the trabecular meshwork (Percival 1982). Post-operatively remaining viscoelastic seems to depolymerise and leave the anterior chamber (AC) during the period not exceeding 48-72 hours (Pape & Balazs, 1980). In an experimental study in human cadaver eyes, the instillation of sodium hyaluronate caused a 65% decrease in outflow facility (Berson et. al,1983). The amount of IOP rise allied directly with the amount of sodium hyaluronate remained in the anterior chamber (Barron et. al. 1985). Due to this reason, the practice of diluting or removing the viscoelastic substance at the end of the surgery in attempt to prevent postoperative increase in IOP has been recommended (Lazenby & Brooker, 1981).

2.1.2 Complications of post-operative ocular hypertension

Among the complications of an acute rise in IOP following routine cataract surgery is post cataract extraction anterior ischaemic optic neuropathy (PCE – AION). It is the most serious blinding ocular complication, with poor prognosis for recovery of the vision. It is caused by the acute high rise in IOP during the immediate post-operative period in eyes with vulnerable optic nerve head circulation. Thus, in susceptible persons, i.e. with arteriosclerosis, atherosclerosis, and cardiovascular disorders, and to eyes with poor circulation in the optic nerve head, a transient ocular hypertension can easily compromise a circulation in the optic nerve and produce PCE-AION. There is a high risk in the development of PCE-AION in the second eye patients with PCE-AION in the first eye. (Hyreh, 1974, 1980, Beri et. al. 1987).

Increased IOP may also be associated with post-operative pain, corneal edema, and loss of visual field in patients with pre-existing glaucoma.

2.1.3 Agents used previously in preventing post-operative ocular hypertension.

A number of agents have been tried in attempt to reduce the possible rise in IOP following cataract extraction. It started with Rich in 1969 where he demonstrated that administering 500mg. of acetazolamide (carbonic anhydrase inhibitor) intramuscularly at the end of the operation, followed by 250mg. orally every six hours for 24 hours, did not completely succeed in preventing postoperative ocular hypertension. It did however produce a statistically significant lowering of the hypertensive response in 24 hours. Acetazolamide decrease the intraocular pressure by declining the rate of aqueous secretion.

In 1977, Rich again demonstrated a favourable response using prostaglandin inhibitors. Since prostaglandin was implicated as a contributor factor in the postoperative ocular hypertensive response, by inhibiting its synthesis, he proved that he could reduce this response. By dividing the patients into three groups, he used oral indomethacin 25mg. every 6 hours for 48 hours preoperatively in the first group, oral acetylsalicylic acid 900mg. preoperatively in the second group, and a group of patients as a control measurement. He found that those drugs caused a significant reduction in the IOP rise 6 hours postoperatively but did not abolish it. The control group showed IOP rise about 3 times the preoperative level at 6 hours postoperatively. However, because of their irritant effect upon the gastric mucosa, it was not recommended for those with gastrointestinal disease.

Timolol has been investigated as a prophylaxis for postoperative raised in IOP by Obstbaum and Galin in 1979. They showed that prophylactic timolol 0.25% (a beta-adrenergic block which decrease aqueous secretion) instill topically at the completion of intracapsular cataract extraction without the use of alpha-chymotrypsin but with iris supported lens implant, reduced the postoperative IOP measured at 24 hours. This effect, in the absence of pupillary changes, made timolol advantageous in iris supported lens implanted eyes, where dilatation or undue constriction, may be dangerous.

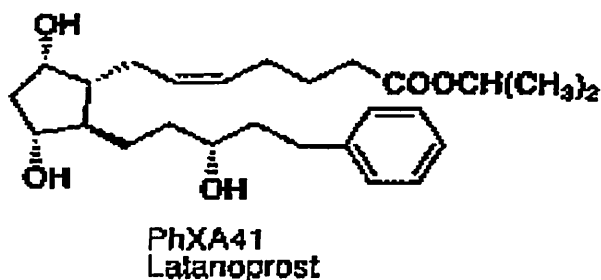
However, different story occurs in the case of extracapsular cataract extraction using sodium hyaluronate. Ruiz and co-workers (1987) in their study on timolol 0.5%, pilocarpine 4% eyedrop and pilocarpine 4% gel, demonstrated that timolol 0.5% instilled topically at the completion of extracapsular cataract extraction with the use of sodium hyaluronate and posterior chamber lens implant, failed to produce a statistically significant effect on the intraocular pressure 24 hours postoperatively. Similarly, the use of pilocarpine 4% eyedrop, showed minimal benefit, though, pilocarpine 4% gel significantly reduced the mean intraocular pressure 24 hours post-operatively. However, all groups showed a significant increase in IOP when compared with baseline values ($P < 0.001$).

Acetylcholine, a cholinergic agent has been used for many years as an adjunct in cataract extraction for its miotic effect. However, little attention had been paid to its effect on IOP. As with other cholinergic agents such as carbamylcholine (carbachol), acetylcholine have a direct effect on the ciliary muscle and were expected to increase

outflow facility through effects on the trabecular meshwork.. Hollands, Drance and Schulzer (1987) showed 0.75ml of intracameral acetylcholine 1% at the completion of extracapsular cataract extraction and posterior chamber intraocular lens implant without the use of viscoelastic substance have no effect beyond six hours from the time of surgery. Acetylcholine was rapidly broken down by the action of acetylcholinesterase that accounted for the lack of sustained effect on the IOP. In a similar study (Hollan, Drance and Schulzer, 1987) they examined the use of 0.4ml intracameral 0.01% carbachol and found that the IOP was significantly lower for 24 hours post-operatively. This is because of the carbachol was resistant to enzymatic hydrolysis and therefore active for a longer period.

2.2 LATANOPROST

2.2.1 Chemical structure of Latanoprost (PhXA41)



2.2.2 Pharmacological properties

Latanoprost (PhXA41 ; XalatanTM), one of the PGF₂ α analogue, is a drug from a new group of ocular hypotensive agents, the prostaglandin (PGs). It is a selective prostanoid FP receptor agonist which reduce the IOP by increasing the outflow of aqueous humor through the uveoscleral outflow.(Lindsey et. al. 1997). Several mechanisms have been proposed to explain the increased in uveoscleral outflow on the basis effect of latanoprost on the ciliary muscle. One of the hypothesis is that the PGF₂ α could induce ciliary smooth muscle cells to degrade adjacent extracellular matrix (ECM) in the spaces between ciliary smooth muscle fibers, thereby reducing the hydraulic resistance around the fibers. This will facilitate aqueous flow through the muscle (Lindsey et. al. 1997).

Although there is some increase in outflow facility through conventional trabecular meshwork by the latanoprost, it is not sufficient enough to account for the observed IOP reduction (Kerstetter et. al. 1988). Besides, unlike few other ocular hypotensive agents, it did not reduce the aqueous humor production (Kerstetter et. al. 1988, Higginbotham, 1996). Therefore it did not jeopardize the nutritional safety margin of avascular tissues in the anterior segment structures that depend on aqueous humor flow. This is particularly important especially to the trabecular meshwork where reduce aqueous humour production has potential in contributing to the deterioration of conventional outflow channels.(Becker, 1995)

Latanoprost has not been found to have any effect on the blood-aqueous barrier. It has no negligible effects on the intraocular blood circulation when used in clinical dose and studied on monkeys. However, in the eyes with glaucoma and its related condition, Miyake and his co-worker (1999) showed that latanoprost therapy was noted to enhance disruption of the blood-aqueous barrier and increase the incidence of angiographic cystoid macular oedema (CMO) formation in early postoperative pseudophakias. In their study, the latanoprost was given for five days (two days before and three days after the operation), compared to our study which the drug was given for only one dose. Miyake et. al. also showed the administration of nonsteroidal eyedrop such as diclofenac seems to prevent this adverse effect of latanoprost therapy.

Latanoprost in clinical doses has not been found to have any significant pharmacological effects on the cardiovascular or respiratory system.

2.2.3 Pharmacokinetic properties

Latanoprost is an isopropyl ester pro-drug that per se is inactive but after hydrolysis to the acid of latanoprost becomes biologically active. The pro-drug is well absorbed through the cornea and all drugs that enter the aqueous humour are hydrolysed during the passage through the cornea. The reduction of the IOP in man starts about 3 to 4 hours after administration and maximum effect is reached after 8 to 12 hours. Pressure reduction is maintained for at least 24 hours, therefore recommended therapy is one drop once daily (Diestelhorst et. al., 1997).

In three-center randomized, double-masked, one month study of twice-daily treatment with placebo or 0.0035%, 0.006% and 0.0115% latanoprost, the mean IOP reduction was between 31% and 38%, with only one week dose response relationship, suggesting that the low concentrations were close to the mean ocular hypotensive dose response curve for latanoprost (Alm et. al., 1993). The commercially available preparation of latanoprost are 0.005% and each ml. of latanoprost 0.005% contains 50 mcg latanoprost and benzalkonium chloride 0.2 mg/ml. For each drop of latanoprost contains approximately 1.5 µg latanoprost.

After topical application on monkeys, latanoprost is distributed primarily in the anterior segment, the conjunctiva, and the eyelids. There is practically no metabolism of the acid of latanoprost in the eye. The main metabolism occurs in the liver. The half life in plasma is 17 minutes in man. The main metabolites, the 1,2-dinor and 1,2,3,4-tetranor

metabolites, exert no or only weak biological activity in animal studies and are excreted primarily in the urine.

2.2.4 Side effects

The side effects of latanoprost are mainly ocular with no systemic side effect reported before. Ocular side effects mostly occur in an eye with prolonged used of latanoprost and include the following;

- a) increased pigmentation of the iris
- b) darkening, thickening and lengthening of the eyelashes.
- c) Darkening of the palpebral skin of the lids (very rarely been noted)
- d) Slight foreign body sensation
- e) Mild conjunctival hyperaemia (noted in about 10% of patients) and moderate hyperaemia (noted in about 1% of patients)

3. MATERIALS AND METHODS

MATERIAL AND METHODS.

3.1 STUDY DESIGN

This is a randomized, double-masked clinical trial which include patients undergone uncomplicated extracapsular cataract extraction with posterior chamber intraocular lens implantation.

3.2 SAMPLING

All consecutive patients, who were admitted to the hospital Universiti Sains Malaysia, Kubang Kerian, Kelantan for extracapsular cataract extraction with intraocular lens implantation under local anaesthesia between May 1999 and September 2000, who met the selection criteria were taken for the study.

They were randomly assigned into two groups. The latanoprost group (group A) consisted of patients who received a drop of guttae latanoprost 0.005% at the end of the surgical procedure. The control group (group B) consisted of patients who received a drop of guttae optizoline (Tetrahydrozoline hydrochloride) at the end of the surgical procedure.

3.2.1 Sample size

A minimum of 54 patients was required for this study based on calculation using Pocock's formula with the power of the study of 90%.

3.3 PATIENT SELECTION

Patients were selected according to the following criteria;

- a) Age between 40 and 80 year old.
- b) Pre-operative intraocular pressure below 22 mmHg in either eye.
- c) Axial length of the eyeball between 22 and 26 mm.
- d) No history of glaucoma, uveitis, retinal detachment and intraocular surgery before.
- e) No history of long-term use of ocular medications.
- f) No history of presently being on carbonic anhydrase inhibitors, diuretics, hyperosmotic agents, corticosteroids or anti-inflammatory agents.
- g) No evidence of glaucomatous cupping of the optic disc of either eye (when visible)
- h) No clinically significant visible ocular abnormalities other than cataract.
- i) No contraindication to the use of posterior chamber intraocular lens.

3.4 CRITERIA FOR EXCLUSION

Patients were excluded from the study after selection if the following events occurred;

- a) A posterior chamber intraocular lens could not be inserted.
- b) Healon had to be retained in the anterior chamber.
- c) Carbachol had to be used for what ever reason.
- d) Any complications intraoperatively causing ruptured posterior capsule.

3.5 CRITERIA FOR DIS-CONTINUING FROM THE STUDY

Patients were discontinued from the study if the intraocular pressure was found to be more than 30mmHg during any post-operative measurement. The patient will be treated accordingly and the subsequent measurements would not be a true reflection of the pattern of post-operative intraocular pressure anymore. The intraocular pressure of more than 30mmHg were chosen since it is known to cause ocular complications.

3.6 MINIMISING ERROR

Attempts in minimize the sampling and non-sampling errors were made by the following means;

- a) Randomized selection of patients into two groups.
- b) Masked, double blind study technique.
- c) The intra-ocular lens (polymethylmethacrylate by pharmaia, model 808C) was inserted in the capsular bag (posterior chamber) in all patients.
- d) The viscoelastic substance (Healon GV) used, were same in all patients.
- e) All surgeries were performed by two identified surgeon using the same preoperative and intraoperative procedures in all patients, who was masked to each patient's treatment group.
- f) All intraocular pressure measurements were taken by the same individual, who also was masked, to each patient's treatment group.
- g) Only the surgical assistant was aware of the drug given in each case.. The data regarding the patient and the treatment given was kept in a separate file that was kept by the surgical assistant.

3.6 PRE-OPERATIVE EVALUATION

3.6.1 History

A careful history was taken in all patients. This included present and past history of ocular problems, ocular surgery and ocular medication.

3.6.2 Ocular examination

Ocular examination started with using slit lamp biomicroscopy was done with special emphasis on the evidence of past or present uveitis, anterior chamber depth, rubeosis, pupil abnormalities and degree of lens opacities. In a case where the anterior chamber looks shallow, a gonioscopic examination was done to exclude angle abnormality and narrow angles.

Intraocular pressure was measured pre-operatively in the both eyes using the same Goldman applanation tonometer. Measurements were made with the tonometer prism aligned horizontally, without any pupillary dilatating medication. All measurements were made between 10 am and 1pm, one day prior to surgery.

Ophthalmoscopic examination after pupillary dilatation was done for the both eyes after intraocular pressure measurement (the morning, a day before the operation). The optic

disc and cup-disc ratios were noted. If the cataract was too dense to visualize the fundus, B-scan was done to exclude posterior segment abnormalities.

3.6.3 General examination

General and systemic examination was done for all cases to determine general fitness for the operation.

3.6.4 Laboratory investigations

Routine laboratory investigations were done a week prior to surgery. They consisted of blood sugar profile and electrocardiogram to determine the general fitness of the patient for the operation.

3.6.5 Demographic data and consent

For the patient who fulfill the criteria for selection, the demographic data were taken and recorded in form A (appendix I). The data recorded includes;

- a) Age of the patient
- b) Sex
- c) Eye selected : OD/OS
- d) Axial length of the eye ball
- e) Type of cataract
- f) Pre- operative intraocular pressure.

Consent was taken from the patient after the explanation regarding the study given to the patient. (Appendix II).

3.7 PRE-OPERATIVE MYDRIASIS AND MEDICATION

Pre-operative mydriasis was achieved by using 1% tropicamide and 2.5% phenylephrine instilled three times at 15 minutes interval approximately an hour before surgery. Premedication of intramuscular Promethazine hydrochloride (phenergan) 25mg and Pethidine 1mg/kg were given about one hour prior to surgery.

3.8 ANAESTHESIA

All cases were done under local anaesthesia using retrobulbar block. The local anaesthesia was given 15 minutes prior to surgery using 3 ml. of 50/50 mixture of 2% lignocaine and 0.5% bupivacaine.

A Van Lint block using 5ml. of the same mixture was also given after the retrobulbar injection.

3.9 PRE-OPERATIVE INTRAOCULAR PRESSURE REDUCTION

This was achieved using digital massage over the globe in all cases for 5 minutes soon after the retrobulbar injection was given. A constant pressure of 5mm Hg was then applied to the globe using Honan balloon for approximately 10 minutes.

3.10 SURGICAL TECHNIQUE

A standard manual cataract extraction was performed on all patients. The sequences of the operation were as follows;

- a) Barraquer's eye speculum was used to keep the eyelids open.
- b) A superior rectus bridle suture was applied.
- c) Fornix based conjunctival incisions was made followed by posterior or limbal corneal incision.
- d) Healon GV (figure 1) injected into the anterior chamber to deepen the chamber and protect the endothelium
- e) Anterior endocapsulotomy performed.
- f) The nucleus expressed, and the cortical remnant was aspirated with the simco irrigation-aspiration cannula.
- g) Healon GV again injected into the bag and anterior chamber.
- h) Intraocular lens (figure 2) inserted into the capsular bag.