

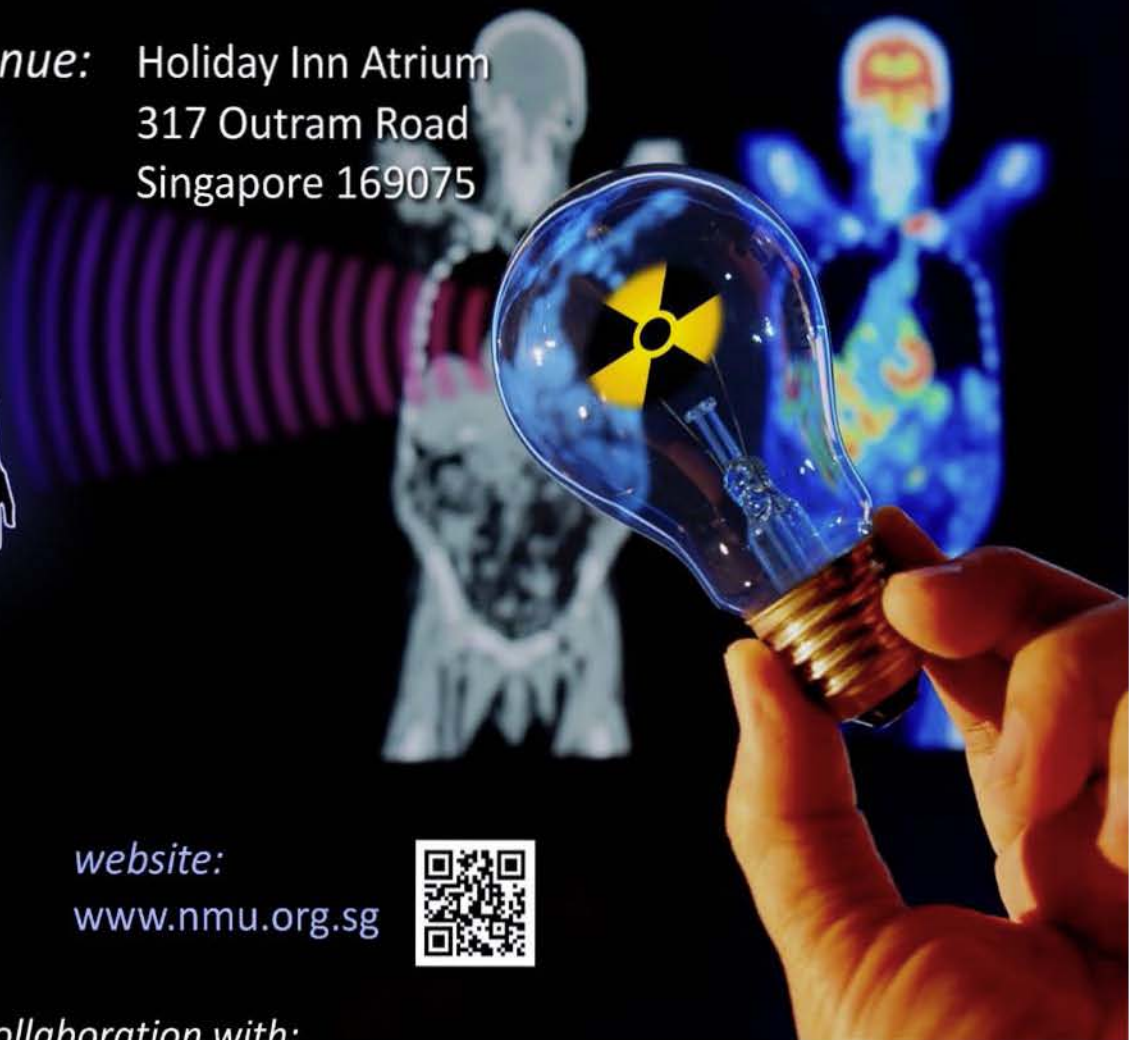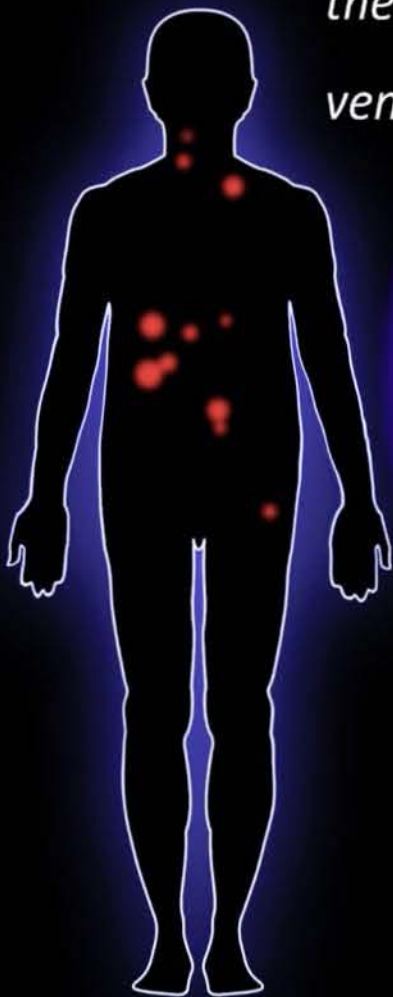
# Nuclear Medicine

UPDATE 2015

*date:* 6 - 8 August 2015

*theme:* Nuclear Medicine Theranostics

*venue:* Holiday Inn Atrium  
317 Outram Road  
Singapore 169075



*website:*  
[www.nmu.org.sg](http://www.nmu.org.sg)



*Organised by:*

*In collaboration with:*



# Nuclear Medicine

UPDATE 2015

*theme:* Nuclear Medicine Theranostics

6 – 8 August 2015      Holiday Inn Atrium, Singapore

*organised by:* Nuclear Medicine Society, Singapore

*in collaboration with:* World Association of Radiopharmaceutical & Molecular Therapy  
Asia-Oceania Federation of Nuclear Medicine & Biology  
American College of Nuclear Medicine  
Singapore General Hospital



# POSTER LISTING

Thursday, 06 August 2015

1520 – 1600 POSTER PRESENTATIONS 2

(Changi Room, Level 4)

- 
- P-10 **Wandering Meckel's Diverticulum on 99mTechnetium-pertechnetate Scintigraphy - A Diagnostic Dilemma?**  
Dr Maseeh uz Zaman, Pakistan
- 
- P-11 **The Study of Technetium-99m HMPAO Brain Perfusion Spect Imaging in Dementia Patients**  
Dr Thiri Kyi Phyu, Myanmar
- 
- P-12 **Single Bone Metastasis in Pancreatic Neuroendocrine Tumour**  
Dr Khadijah Abdul Hamid, Malaysia
- 
- P-13 **Role of Lymphoscintigraphy in the Management of Congenital Pulmonary Lymphangiectasia**  
Dr Khor Phay Phay, Malaysia
- 
- P-14 **Role of 99m TC-MDP Bone Scan for Evaluating Skeletal Metastasis in Patients with Carcinoma Breast: 1 Year Experience**  
Ms Shaila Sharmin, Bangladesh
- 
- P-15 **Role of 99mTc-MDP Bone Scan For Evaluating Skeletal Metastasis in Patients with Carcinoma Prostate**  
Ms Tania Sultana, Bangladesh
- 
- P-16 **The Incidence and Risk Factors Influencing Renal Scarring in Children Undergoing 99mTc-DMSA Scan Following Urinary Tract Infection**  
Dr Hazlin Hashim, Malaysia
- 
- P-17 **Meta-Analysis of Diagnosis Techniques for Multiple Myeloma Related Bone Disease**  
Ms Weng Wanwen, China
- 
- P-18 **Bone Scan in Alcohol Induced Multifocal Avascular Osteonecrosis: A Diagnostic Quandary**  
Dr Maseeh uz Zaman, Pakistan
- 
- P-19 **'In-House' Fatty Meal Cholescintigraphy in Characterisation of Dyspepsia-Symptom Complex**  
Dr Avani S. Jain, India
- 
- P-20 **"Pseudo-Thyroid Lobe": A Diagnostic Conundrum Caused by Ossified Anterior Longitudinal Ligament (OALL) on Bone Scan**  
Dr Maseeh uz Zaman, Pakistan
- 
- P-21 **Role of 99m TC-MDP Bone Scan for Evaluating Skeletal Metastasis in Patients with Carcinoma Cervix: 1 Year Experience**  
Dr Afroza Akhter, Bangladesh
-