

The Outcome of Closed interlocked Nailing for Treatment of Comminuted Femoral Shaft fracture

Prepared by

Dr. Mohamad Yazid Hj. Din, MBBS
Department of Orthopaedic Surgery
HUSM Kubang Kerian



3001262

**DISSERTATION SUBMITTED IN PARTIAL FULFILLMENT OF THE
REQUIREMENTS FOR THE DEGREE OF MASTER OF MEDICINE
(ORTHOPAEDIC)**

CONTENTS	PAGE
TABLES OF CONTENTS	i
ACKNOWLEDGEMENT	iii-iv
1. ABSTRACT - BAHASA MALAYSIA	v-iv
- ENGLISH	vi-vii
2. INTRODUCTION	1
3. REVIEW OF LITERATURES	5
3.1 ANATOMY	5
3.2 BLOOD SUPPLY OF THE FEMORAL SHAFT	8
3.3 INCIDENCE	14
3.4 MECHANISM OF INJURY	15
3.4.1 ASSOCIATED INJURY	16
3.4.1.1 VASCULAR INJURY	16
3.4.1.2 NERVE INJURY	17
3.5 CLASSIFICATION OF FRACTURE	17
3.6 EFFECT OF REAMING	22
3.7 BIOMECHANIC OF INTRAMEDULLARY NAIL	29
3.8 COMPLICATION OF INTRAMEDULLARY NAIL	33
3.8.1 INFECTION	33
3.8.2 NON UNION	34
3.8.3 MALUNION	35
3.8.4 NERVE INJURY	36
3.8.5 HETEROTOPIC OSSIFICATION	36
3.8.6 COMPARTMENT SYNDROME	37
3.8.7 IMPLANT FAILURE	38
3.9 OVERVIEW OF TREATMENT	38

3.9.1 INTRAMEDULLARY NAIL	39
3.9.1.1 CONVENTIONAL INTRAMEDULLARY NAIL	39
3.9.1.2 INTERLOCKING NAIL	41
3.9.2 PLATING	42
3.9.3 TRACTION	46
3.9.4 EXTERNAL FIXATION	46
3.10 OPERATIVE PROCEDURES	48
4.0 OBJECTIVE OF THE STUDY	56
5.0 METHODOLOGY OF THE STUDY	57
6.0 RESULT OF THE STUDY	63
7.0 DISCUSSION	88
8.0 CONCLUSION	100
9.0 LIMITATION OF THE STUDY	101
10.0 DEFINATION OF TERM	102
11.0 QUESTIONARE	104
12.0 REFERENCES	106

DEDICATED TO;

MY WIFE; NORSIAH MD NOOR

MY DAUGHTER; FATIN NABILAH

MY PARENT; DIN SHAFIE AND SITI MERYAM ARSHAD

ACKNOWLEDGMENT

I wish to express my sincere thanks to Dr. Mohamad Iskandar Mohamad Amin, Orthopaedic surgeon HUSM, who has been a constant source of inspiration and also for his valuable guidance and advice.

My special thanks to other lecturers Assoc. Prof. Devnani, Assoc. Prof Dr. Zulmi Wan, Dr Nordin Simbak, Dr. Halim and Dr. Aidura Mustafa, for their guidance.

My sincere thanks to former and present Orthopaedics consultants in Penang Hospital i.e Dr. Jamaludin, Dr. Thevarajan, Mr. Se To Boon Chong and for their kind supports.

I would like to thank all my friends for their supports.

Finally I would like to thanks to my wife and my daughter for their time and patience they have sacrificed to make the completion of this diserrtation possible.

Abstraks

Fraktur tulang femur adalah suatu kecederaan yang sering berlaku, selalunya disebabkan oleh kemalangan jalan raya. Kecederaan tulang ini boleh diklasifikasikan kepada beberapa tahap bergantung kepada teruknya kemalangan yang berlaku. Bagi golongan muda, selalunya kepatahan ini berlaku semasa kemalangan jalanraya. Bagi golongan tua pula ianya disebabkan kecederaan dirumah seperti jatuh dan lain lain.

"Static reamed interlocking nailing" adalah suatu cara rawatan yang standard dalam merawat fraktur tulang femur terutamanya bagi yang mengalami fraktur yang teruk. Suatu ketika penggunaan kaedah ini dianggap boleh membawa kepada komplikasi non union. Satu lagi cara merawat tulang femur yang patah ini ialah menggunakan kaedah "unreamed"

Satu analisis retrospektif telah dibuat untuk mengenal pasti kebaikan dan kelemahannya.

Dalam masa dua tahun, iaitu dari bulan Januari 1996 hingga 1997, seramai 92 pesakit dengan 93 kepatahan telah dimasukkan dalam kajian untuk dianalisiskan . Mereka

terdiri daripada 77 orang lelaki dan 16 perempuan. Pesakit berumur diantara 16 hingga 73 tahun. Keputusan hasil rawatan telah dianalisa berdasarkan kepada pnyembuhan (union), jenis implan yang digunakan dan komplikasi yang timbul akibat daripada cara rawatan.

Kesimpulan dari analisa ini menunjukkan bahawa kaedah ini adalah sesuai bagi rawatan fraktur femur yang teruk (comminuted). Satu lagi keputusan analisa menunjukan saiz implan yang digunakan adalah lebih kecil berbanding dengan implan yang digunakan di negara barat.

Abstract

Fractures of femoral shaft is quite common injury especially those involving the road traffic accident. The severity of comminution ranges from simple to highly comminuted fracture. For the younger age group, it had always been due to road traffic accident. For the older age group, the usual cause is minor injury such as fall.

Static reamed interlocked nailing is a standard treatment in the management of femoral shaft fracture, especially the comminuted one. The used of static nailing was thought to lead to increasing risk of nonunion. Unreamed nailing is another choice in treating comminuted femoral shaft fracture.

A retrospective analysis of comminuted femoral shaft fractures treated with locked reamed interlocking nail was carried out to identify the outcomes of this procedure.

For the period of two years, from January 1996 till December 1997, 92 patients with 93 comminuted femoral shaft fractures were available for analysis. Male were 77 and female were 16. The age of patients ranges from 16

to 73 years old. The result of the fixation were analysed with respect to union, malunion, length and size of the nail used, surgical complication and implant failures.

This study concludes that this procedure is a good choice for the treatment of comminuted fractures of the femoral shaft. It also shows that the size of the nail needed in the treatments of this fractures is smaller in size compared to the one used in western populations.

2.0 Introduction

The femur is essential for ambulation. It is subjected to axial loading, bending forces and torsional forces during walking. The distal and proximal part of the femur makes up half of the hip and knee joint. Fracture to this bone will lead to significant effect on either one of these joints.

A femoral shaft fracture usually result from a high-energy force violent enough to fracture the bone. This injury can lead to loss of a lot of blood. About 40% of patients with an isolated femoral shaft fracture have an average transfusion requirement of 2.5 units of red cells (Wolinsky and Johnson 1998).

Prior to the advent of modern techniques, the femoral fractures were disabling and frequently fatal injuries. The treatment has evolved over the past century from simple splinting or traction of a limb to the refined technique of internal fixation. This has greatly lessen the mortality and morbidity of this injury

There are a number of reasons for the alteration in the management of femoral fractures (Court-Brown 1998).

Orthopaedic surgeons have come to appreciate that bone union is not always the only goal to be achieved and that patient function is, in fact, the most important outcome measure. The slogan 'movement is life' was adopted by the Arbeitgemeinschaft für Osteosynthesefragen (AO) group who initially advocated surgery using rigid bone plates to permit early movement. However, as in other branches of surgery, orthopaedic surgeons have adopted minimal access techniques with improved preservation of soft tissues and bone vascularity. As the advantages of this type of approach became apparent plating gave way to external skeletal fixation and subsequently to interlocking intramedullary nailing.

Surgeons initially became interested in interlocking intra-medullary nailing because of the difficulties that they encountered in the management of femoral fractures. Although Kuntscher invented the interlocking femoral nail it was the collaboration of *Klemm & Schellmann (1986)* and *Kempf et al (1985)*, which produced the nails that changed the treatment methods of many surgeons. These nails were passed antegrade into the femur using fluoroscopy to reduce the fracture and guide the nail distally. Proximal and distal locking screws were used to maintain length and alignment.

The classical indication for an intramedullary nail is a closed fracture in the middle one third of the femur. Using the closed nailing technique the fracture, haematoma and periosteal blood supply are minimally disturbed and rapid healing of the fracture occurs with little risk of infection, non union or shortening.

Comminuted fractures of the femur, on the other hand, present a much more difficult problem. Treatment with skeletal traction, spica casts, cast bracing, or roller traction almost always leads to union. However, prolonged hospitalization, malunion, and shortening often occur. Open reduction and plate osteosynthesis, while restoring length and alignment, require an extensive surgical dissection with considerable blood loss and a small but definite risk of infection, delayed union, nonunion, and implant failure. Standard closed IM nailing followed by traction for three to six weeks is another treatment alternative, but it compromises the full benefit of closed nailing and does not completely eliminate the possibility of shortening at the fracture site. Open IM nailing with adjunctive cerclage wiring provides a good mechanical solution for certain comminuted fractures, but it exposes the patient to increased risks of infection and delayed union.

To treat these difficult femur fractures effectively, several investigators have developed and implemented a locking nail. Locking the nail into bone is achieved by the addition of self-tapping screws inserted through holes located in the ends of the nail, with the aid of an image intensifier. Interlocking nailing provides immediate length and rotational stability to the fracture and allows the patient to be mobilized without the risks of shortening. Since it is done as a closed technique, the risks of infection and delayed union are minimized.

The use of the locked nail inserted with a closed technique has become the standard care for treatment of femoral shaft fracture but demand experience on the part of the surgical team (*Winqvist 1993*)

The objective of this study is to see epidemiological distribution of the comminuted fractures of the femoral shaft as well to see the outcomes of this type of fractures treated with static interlocking nail in Penang Hospital. With this assessment and analysis, hopefully we can have a better understanding on the treatment of comminuted femoral shaft fractures.

3.0 Review of literatures

3.1 Anatomy

The femur is the strongest, longest and heaviest bone in the body. It is a long tubular structure that extends from the hip proximally to the knee distally. This bone is divided to the shaft or diaphysis and distal and proximal metaphysis.




figure 1: Femoral shaft with diaphysis, metaphysis and isthmus

The shaft of femur extends from the level of lesser trochanter to the flare of the condyles. The shaft of femur shows a general forward convexity. It is slightly bowed anteriorly and narrowest at its shaft. The anterior surface is smooth but posterior part has a ridge, the linea aspera. The medial margin continues below as medial supracondylar ridge. The lateral margin becomes continuous below with the lateral supracondylar ridge. On the posterior surface, below the greater trochanter is the gluteal tuberosity.

There are many muscles attached to the linea aspera. The muscles are gluteus maximus, adductor magnus, adductor brevis, vastus lateralis, vastus medialis, vastus intermedius, and short head of biceps. Large muscles attached to the greater trochanter. If fracture occurs distal to their insertion, they abduct the proximal fracture fragment. (Figure 2)

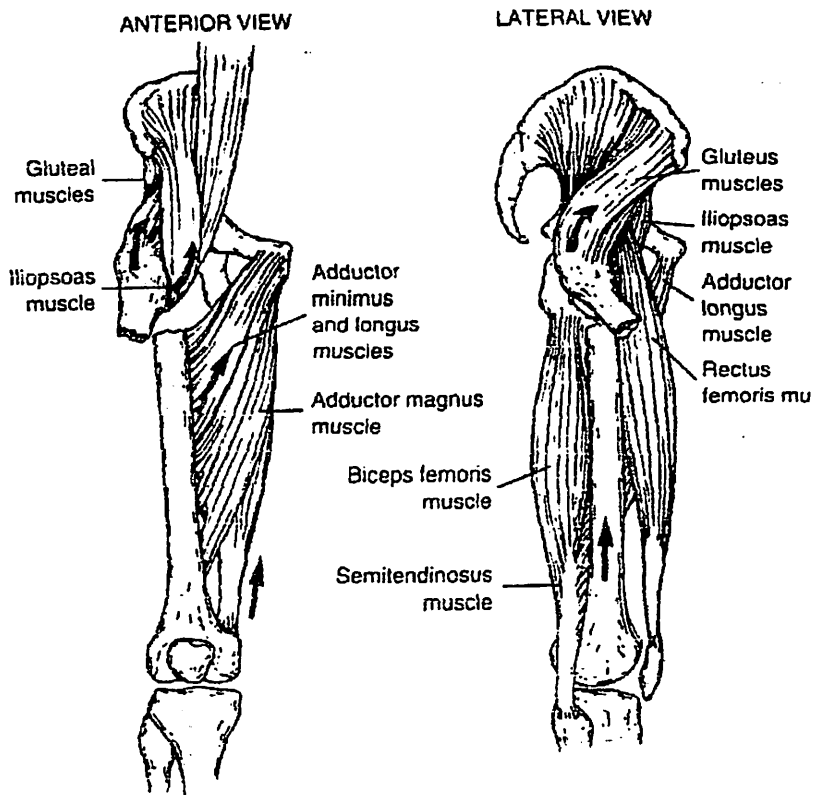


figure 2: Typical deformities occurring with fracture at proximal part of the femur

Several muscles attach on the distal femur. The large adductor muscle mass inserting on the distal medial aspect of the femur tends to create an apex lateral angulation deformity in midshaft fractures. This apex lateral deformity is accentuated by the force of weight bearing, since the axis of application is medial to the shaft of the femur. The forces that tend to create apex lateral angulation are counterbalanced by a large tension band of the fascia lata and lateral muscle mass.

The major function of the femur is as a structure for standing and walking. The best design for strength, particularly with axial loading and bending, is a tubular structure. The femur is reinforced posteriorly by the linea aspera, which counteracts the large anteroposterior bending forces that occur during weight bearing.

3.2 Blood Supply of the Femoral shaft.

The adequate knowledge of blood supply or vascularity of bone is paramount important in the management of long bone fracture. Any discussion of the management must be prefaced by a review of blood supply.

Macnab and De Hass (1974) and *Trueta (1974)* pointed out three main sources of long bone blood supply i.e. the nutrients artery, the metaphyseal vessel and the periosteal vessel.

Macnab and Dee Hass also stressed the importance of intact periosteum acting as periosteal seal to prevent fibrous tissue ingrowth. In resting bone, the periosteal vessel play little part in the nutrition of the cortex. Following fracture, the vessels could be seen to

penetrate the cortex and help to reestablish the endosteal circulation right up to the fracture site.

Rhineland (1968) devised a functional classification of normal circulation of a long bone. It is made up of the afferent, efferent and intermediate vascular system.

Afferent system, which carries blood, bearing nutrients to all part of the body consist of:

1. The principle nutrient artery
2. The metaphyseal artery and
3. The periosteal arterioles.

The efferent system which takes blood bearing wastes products away from bone comprises of

1. The large emissary veins and vena comitans of the nutrient artery which drain the medullay contents exclusively
2. the cortical venous channels, which drain the deeper portion of compactum into periosteal venules and
3. the periosteal capillary, which are in the continuity with the cortical capillary of superficial cortical lamellae.

All these convey blood in an external direction.

(figure 3)


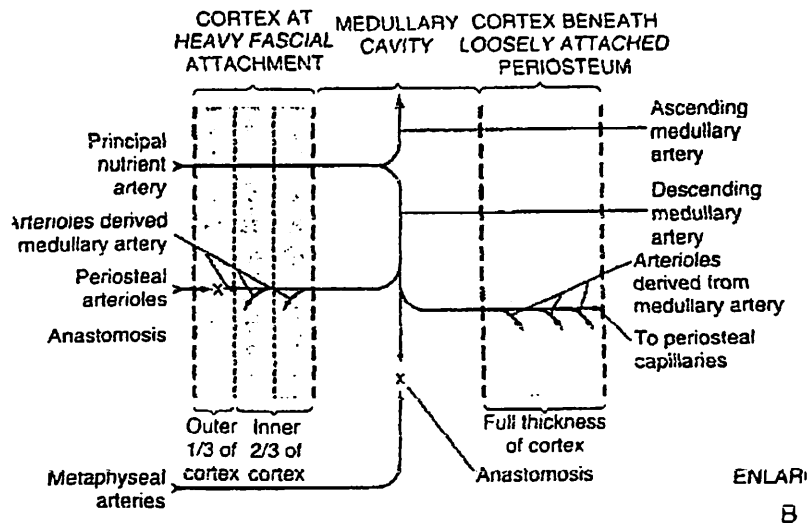


figure 3: Normal direction of blood flow from medullary canal to the cortex. Note that there is minimal contribution from the periosteal blood supply to the cortical bone, which only at the site of strong fascial attachments, such as linea aspera in the femur

In addition to metaphyseal arteries, the femur usually has a single artery that branches off the profunda artery to penetrate the upper half of the diaphyseal cortex, close to linea aspera (*Laing 1953*). The nutrient artery forms medullary arteries in the canal and extend proximally and distally (*Rhilander 1968*). (Figure 4). These medullary arteries penetrate the endosteum of the bone to supply the inner two third of the cortex. These metaphyseal arteries can supply the endosteum of the diaphyseal cortex through their

communications if the nutrients artery is interrupted. The outer third of the cortex is supplied by the periosteal arterioles, which enter the cortex from the fascial attachment.



re 50-3

Figure 4: Blood supply to the femoral shaft , anterior posterior view.

The femoral artery enters the thigh by passing behind the inguinal ligament. It descends almost vertically toward the adductor tubercle of the femur and ends at the opening in the adductor magnus muscle by entering the popliteal space as the popliteal artery. A frequent site of injury is at the adductor hiatus, where it is tethered by soft tissue

The profunda femoris is a large and important branch that arises from the lateral side about 4cm below the inguinal ligament. This artery sends a perforating branch to the proximal half of the femur as the nutrient artery to the femoral shaft. It also sends the perforating artery to supply the muscles that lie along the lateral side of the femur. These perforating arteries can be damage by fracture or during the lateral approach to the femoral shaft.

Two important nerves that run across the thigh are sciatic and femoral nerves. The femoral nerve enters the thigh under the inguinal ligament and supplies the quadriceps muscles. The sciatic nerve enters the thigh posteriorly under the piriformis muscle and is well protected by the muscles as it run through the thigh. Injury to these two nerves in quite uncommon in the fracture of femoral shaft.

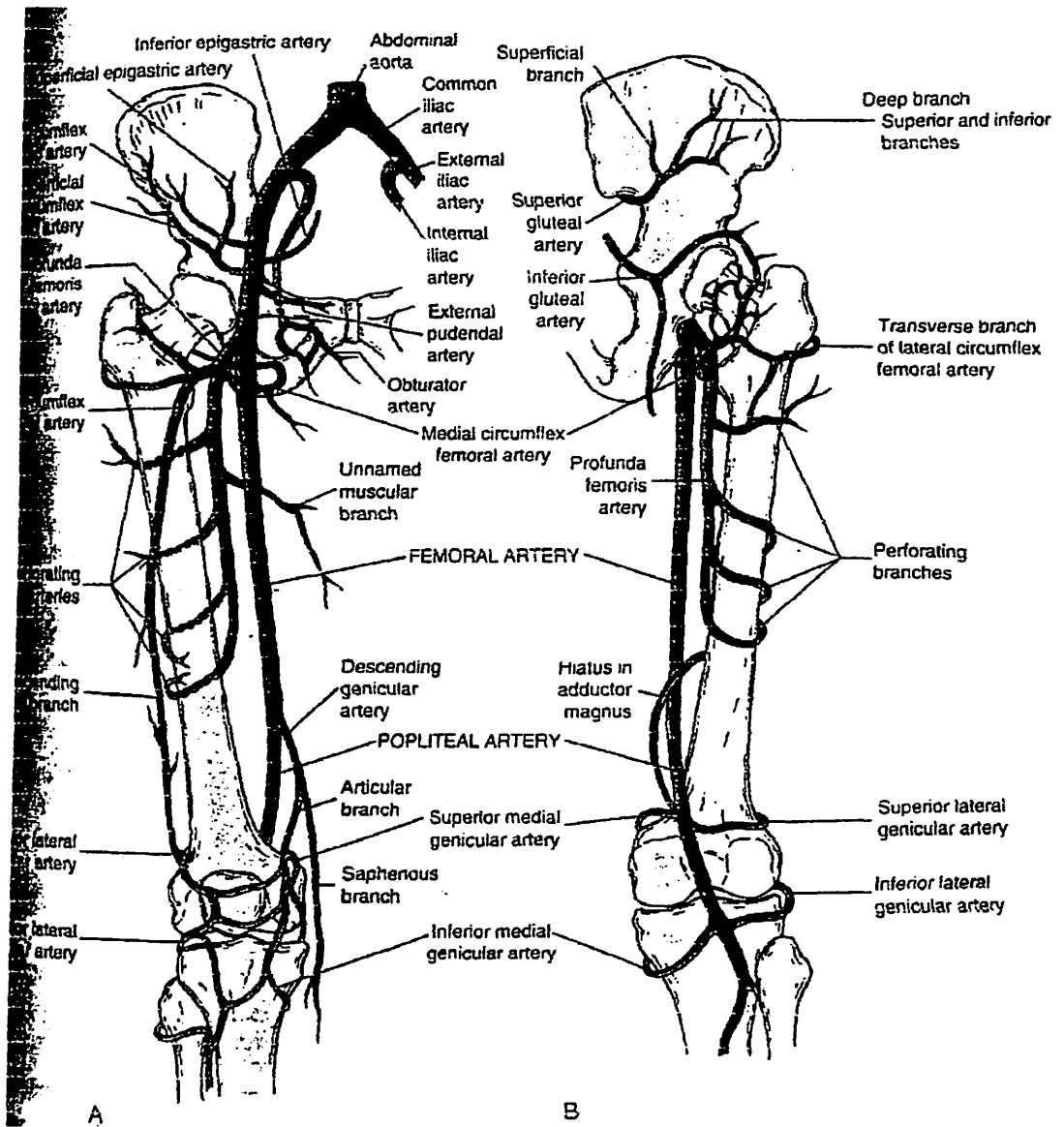


Figure 5: Blood supply to the thigh. A: anterior view

B: Posterior view

3.3 Incidence

Fractures of the femur, in the USA, occurred at a rate of one per 10,000 people per year (Grazier et al 1984). The injuries were more common in those younger than 25 years and older than 65 years of age. The incidence in the age group between 15 to 24 years of age was 39 per 100,000 persons per year. In a Swedish population base study, the average annual incidences in male age groups from 10 to 19 years and from 20 to 29 years were 14.7 and 9.2 per 100,000 inhabitants in 1980s, respectively. High-energy trauma is well known cause of the femoral shaft fractures. *Salminen et al. (2000)* reported 75% of these fractures were caused by high-energy trauma and 85% of these were caused by road traffic accident.

It is noted that there is increase number of fracture of shaft of femur occurred in the elderly, commonly resulted from low to moderate energy trauma. This increased incidence probably due to increased number of elderly incidence in certain part of the world.

Most of the fracture occurred in the midthird of the femur. Regarding the degree of comminution only 20%of the

fractures represented the severely comminuted Winquist and Hansen grade III and IV fracture pattern.

These fractures will result in restricted activity for an average of 107 days, with 69 these in beds. The average length of stay in hospital was 25 days. (*Wolinsky and Johnson 1998*)

In Malaysia there no data to show the incidence of femoral shaft fractures but it is believe to increasing each year.

3.4 Mechanism of Injury

Femoral shaft fractures are usually result from high-energy trauma. They occur mostly in males, as a result of motorvehicle accidents. Its usually result in fatal injury in the past but many patients survive now due to high standard prehospital and hospital care.

Fracture patterns vary according to the direction and quantity of forces absorbed. A direct force applied perpendicular to the axis of the bone produces a tranverse fracture with local soft tissues trauma. A

force applied in rotational direction may injure the hip and knee. The amount of comminution at the fracture site increases directly with the amount of energy absorbed by the femur at the time of injury.

3.4.1 Associated Injuries

3.4.1.1 Vascular injury.

Vascular injuries associated with femoral shaft fractures are rare. It occurs at a rate of 0.1 to 2% of fractures (Cone at al. 1989, Cook at al. 1944, Kluger at al. 1994). Blunt trauma can tear the femoral artery at the level of abductor canal. Distal pulses should be examined in all cases of fracture of the femoral shaft. If any doubts regarding the arterial injury arise, arteriogram examination must be performed.

3.4.1.2 Nerve Injuries

Nerve injuries are also rare. The nerve is more commonly injured by direct, penetrating injury. Most neurological injuries are the result of difficulties and problems with treatment rather than with the injury.

3.5 Classification of fractures

Classification of femoral fracture is important in making the decision of the managements, and patient care. Therefore it should be included in describing the fractures. The description of level of fracture, the fracture patern, and the grade of comminution is important.

Fracture of femoral shaft can be classified according to the level on the bone (Figure 6)

1. Proximal third
2. mid-shaft
3. distal third

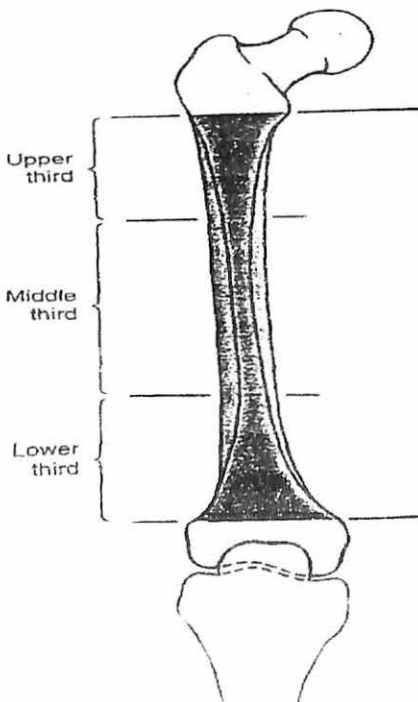


Figure 6: Descriptive term for fracture location

Comminution of femoral shaft fractures was classified by *Winguist et al (1984)*. This assigns comminuted fractures to one of five grades, with the numbers increasing with the degree of comminution.

Grade I: comminuted fracture has a small butterfly fragment that is less than 25% of the width of the bone.

Grade II: comminuted fracture has a larger butterfly fragment of 50% or less of the width of the bone.

Grade III: comminuted fractures consist of a larger segment of comminution (greater than 50% of the width of the bone) with only a small spike of remaining proximal and distal fragments continuing in cortical contact. Such fractures are always unstable in length and rotation.

Grade IV: comminuted fractures consist of segmental comminution with no bone contact between the major proximal and distal fragments.

Grade V: consists of segmental bone loss, which generally occurs in conjunction with an open fracture and is always an unstable fracture.

Grade I and II may be relatively stable in length and rotation, as there is good contact between the major

proximal and distal fragments if the fracture occurs away from the proximal or distal metaphyseal flare.

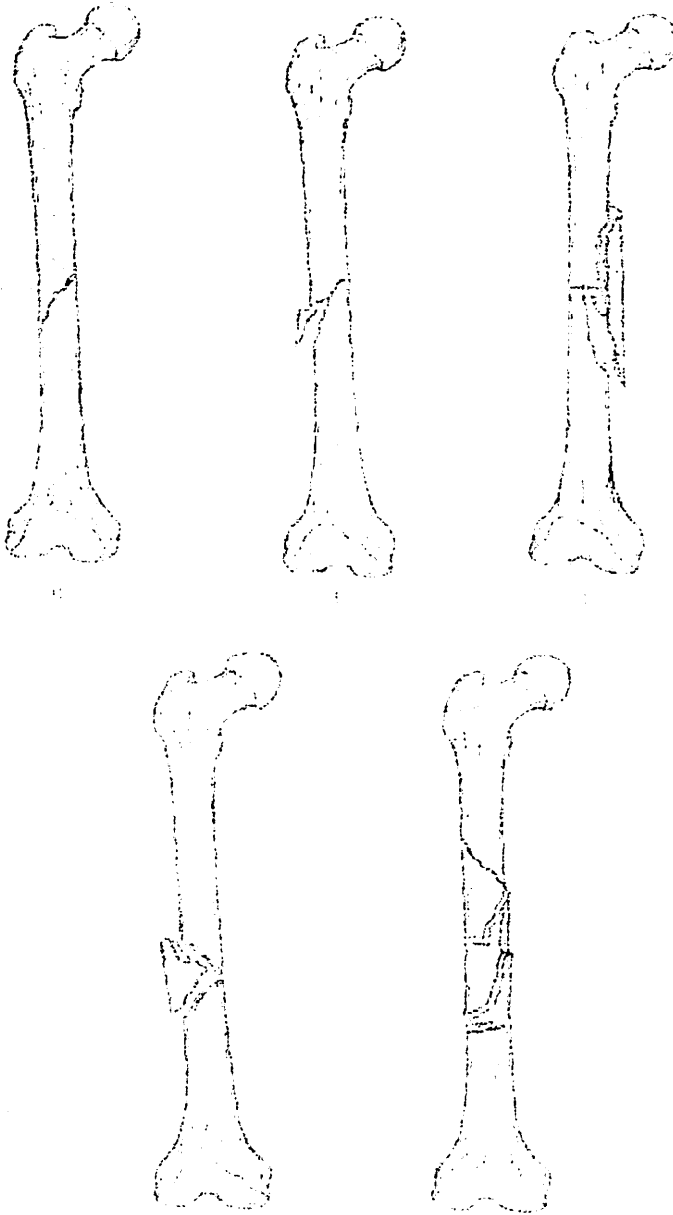


figure 7: Winquist and Hansen's classification of femoral shaft of fracture

Other type of classification, AO classification (Muller et al, 1991) (Figure 8) also can be applied if the need to do so exists.

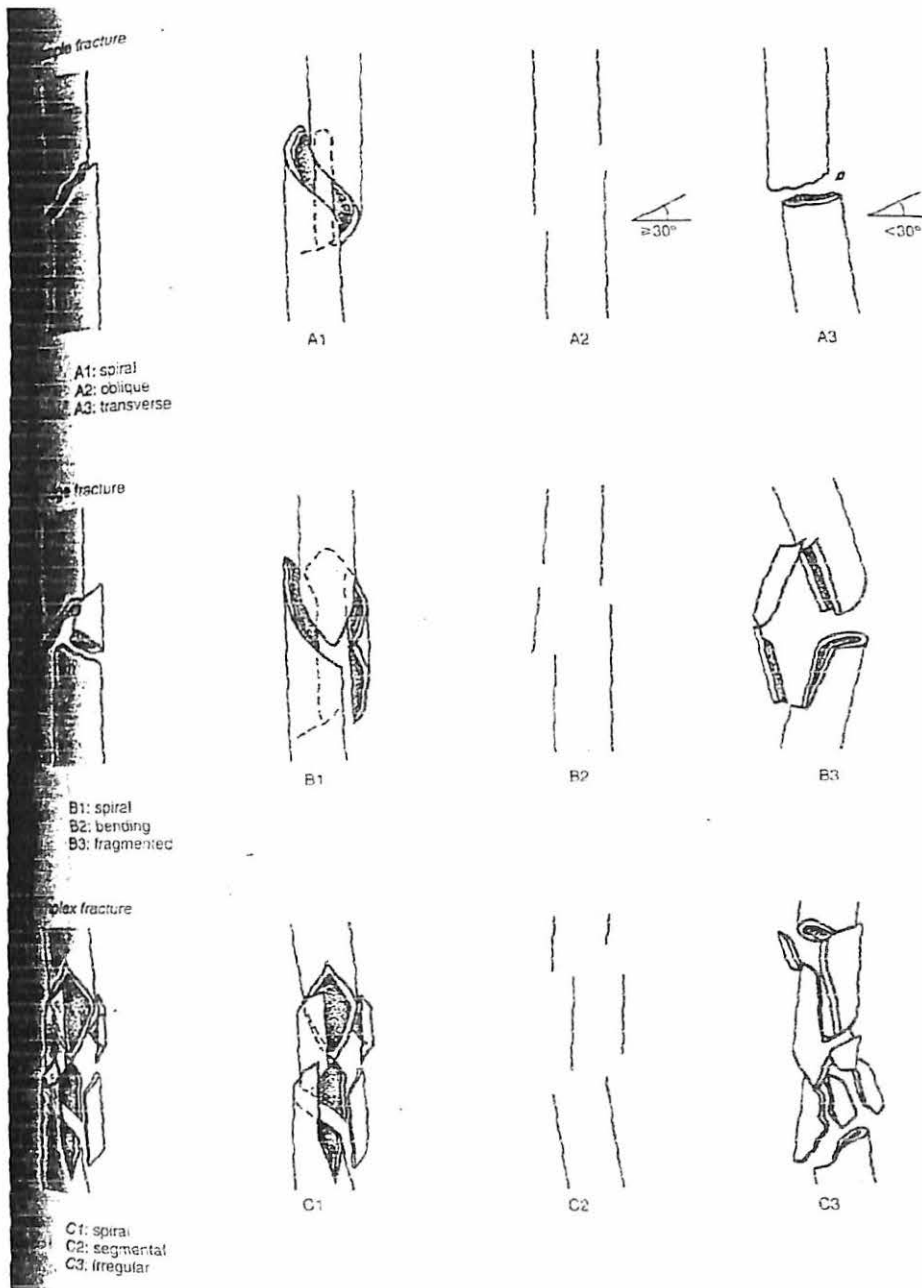


figure 8: AO Classification of femoral shaft fractures

3.6 Effect of reaming

Reaming of medullary canal can increased the length medullary contact. It serves the purpose of extending the isthmus, and a larger area of contact is created. This will further enhancing the stability of the fixation (Chapman 1980).




Figure 9: The contact length between a bone and IMN increases when a bone is reamed because a larger area of constant diameter is created.

ASYMMETRIC CONTACT LENGTH

mm REAMED	%
4	55
3	61
2	65
1	70
0	75

DERIVED FROM
STATISTICAL SAMPLE

Figure 10: Effect of canal taper on contact length. Since the distal taper is more gradual, for every millimeter reamed, the contact length increases disproportionately more distally.

Increasing the contact length is not the sole function of reaming. It also allows the insertion of a bigger nail. The bigger diameter of the nail will increase the stability further.

Reaming of the medullary canal has certain disadvantages. It is known that the reaming will damage the intramedullary blood supply. However, recent work has quantified the extent of the damage. *Klein et al (1990)* showed that reaming of the canine tibia diminished the cortical blood supply by 45 to 85%, whereas use of unreamed nails was associated with a 15 to 30% reduction. *Schemitsch et al (1994)* noted that cortical revascularization of sheep tibiae took up to 6 weeks after unreamed nailing, compared with 12 weeks after reamed nailing. *Reichert et al (1995)* however, took a contrary view, suggesting that reaming is actually beneficial to fracture union. Using intact sheep tibiae and labelled microspheres they demonstrated that intramedullary nailing induced a six-fold increase in the periosteal circulation within 30 mm. They did not demonstrate a rise in the overall blood supply and postulated that an increased periosteal vascular supply compensated for any decrease in the intramedullary circulation.

Any violation of the intramedullary canal may affect cortical vascularity or viability (*Kessler 1986*). A few studies had shown that the insertion of intramedullary nail will interfere with circulation of diaphyseal cortex (*Trueta 1955, Rhinelander 1974*). This is an important

issue because satisfactory tissues response for fracture healing is dependent on an adequate vascular supply. However it is believed reaming will create bone graft material through which and osteogenic response may be generated.

The timing of cortical revascularisation is not completely known. Regeneration of the medullary blood supply appears to be restricted to the marrow spaces on the endosteal surface that are not in direct contact with the nail. There is usually evidence of regenerate medullary arterioles at about 4 weeks after the fracture (*Chapman 1986, Wiss et al 1986*). Following reamed intramedullary nailing, the implant itself represents a certain obstacle to revascularization. This has been underlined by experiments showing that the medullary canal is revascularized more quickly following nonreamed nail systems. It has been observed repeatedly that small vessels grow into existing gaps between the bone and the nail in an astonishingly short period of time, from where they penetrate into the neighboring malperfused cortical bone. At the relatively few sites of close contact between bone and medullary nail, bone lamellae will be removed by osteoclastic activity so that vessels can sprout into the newly formed gap.